

## BALLOON ANGIOPLASTY IN NATIVE AORTIC COARCTATION: RESULTS IN SHIRAZ AND REVIEW OF ARTICLES

M. BORZOEI, G.H. AJAMI, M.R. SABRI, M. RASTEGARI, AND A.R.  
GHASEMI

*From the Pediatrics Department, Pediatric Cardiology Division, Shiraz Medical Sciences University,  
Shiraz, Islamic Republic of Iran.*

### ABSTRACT

Balloon angioplasty for aortic coarctation was introduced in 1979 for the first time.<sup>1</sup> This procedure soon became the choice treatment for restenosis of operated coarctation,<sup>2-5</sup> but remains controversial for native (unoperated) coarctation. However, it seems to be rapidly becoming the intervention of choice for relief of unoperated coarctation as well. In this study, we evaluate the outcome of this procedure in 16 patients with native aortic coarctation, between September 1992 and May 1995. In all patients, dilation was performed successfully and provided significant reduction of pressure gradients ( $p < 0.001$ ). The peak systolic pressure gradient across the coarcted site decreased significantly from  $46.2 \pm 4.8$  mmHg (mean  $\pm$  SD) to  $12.2 \pm 2.5$  mmHg (mean  $\pm$  SD). Two patients were complicated by development of a small aneurysm, and one with reopening of the ductus arteriosus (one had both), but no instances of rupture of aorta and/or death. This suggests the possibility of acceptance of this new therapeutic strategy for native coarctation of the aorta. However, further evaluation of its benefits and safety is recommended.

**Keywords:** Native aortic coarctation, Balloon angioplasty

*MJIRI, Vol. 11, No. 3, 191-195, 1997.*

### INTRODUCTION

Balloon angioplasty for coarctation of the aorta (CoA) started postmortem in 1979,<sup>1</sup> and developed after experience on animals.<sup>6</sup> This technique was then published for operated aortic coarctation (recoarctation) after demonstration of reasonable long-term results in man. In unoperated CoA, in contrast, there has been considerable controversy regarding the safety and long-term effectiveness of the procedure.<sup>7,8</sup> This treatment has been suggested as choice therapy,<sup>3,4,10</sup> especially in neonates and small infants. It is also reported as satisfactory,<sup>15</sup> comparable with surgery (even preferred, because of less complications),<sup>11</sup> and indicated<sup>12</sup> in most recent studies. In

this study we used balloon angioplasty in native CoA in infants and children and one adult and report the results and discuss whether or not this strategy was acceptable.

### PATIENTS AND METHODS

We began percutaneous balloon valvoplasty and angioplasty in children with a case of severe aortic stenosis in a 3 year old boy in September 1991. The protocol used for dilatation of pulmonary stenosis, subvalvar (web) and valvar aortic stenosis, CoA, atrial septostomy, and miscellaneous procedures are summarized in Fig. 1. In all patients with CoA,

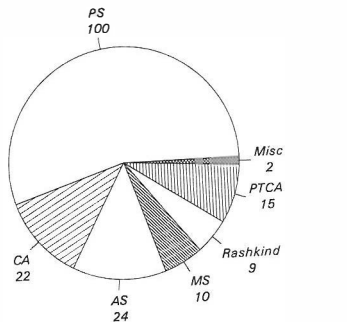
dilatation was indicated when the pressure gradient was more than 25 mmHg across the short segment coarcted site (except those with associated lesions such as left to right shunt, and pulmonary hypertension or congestive cardiomyopathy). Dilatation is also indicated in CoA patients with other associated heart lesions such as aortic stenosis (valvar and subaortic web), transposition of great arteries, left to right shunts with pulmonary hypertension, patent ductus arteriosus, ventricular septal defect, cardiomyopathy, etc.

Eighteen patients with median age of 8.2 years (range 4 months to 15 years) underwent percutaneous balloon dilatation of CoA from September 1992 to May 1995. Pressure gradient measurement and angiography of aortic arch (using left anterior oblique 60 degree projection) was performed before and after angioplasty. The balloon size selected for use was equal to the end of the aortic arch, one centimeter before the narrow segment<sup>5</sup> as measured from echocardiography and angiographic views.

The patients were followed clinically and echocardiographically for 5 to 28 months. Doppler estimations of gradients were calculated by applying the modified Bernolli equation to maximum continuous-wave Doppler systolic peak flow velocities across the coarcted site. All data are presented as mean±one standard deviation. Paired Student's t-test was used for comparison of data obtained before and after angioplasty. The level of significance was set at  $p < 0.05$ .

**RESULTS**

From 18 patients with native CoA, two patients were excluded because of inadequate data despite successful dilatation. The clinical and paraclinical details of 16 patients who underwent angioplasty are summarized in Table I. Angioplasty was performed successfully in all



PS= Pulmonary stenosis      Misc= Miscellaneous  
 AS= Aortic stenosis        CA= Coarctation of aorta  
 MS= Mitral stenosis        Rash = Rashkind  
 PTCA= Percutaneous coronary angioplasty

Fig. 1. Therapeutic cardiac catheterization in Shiraz from September 1991 to May 1995.

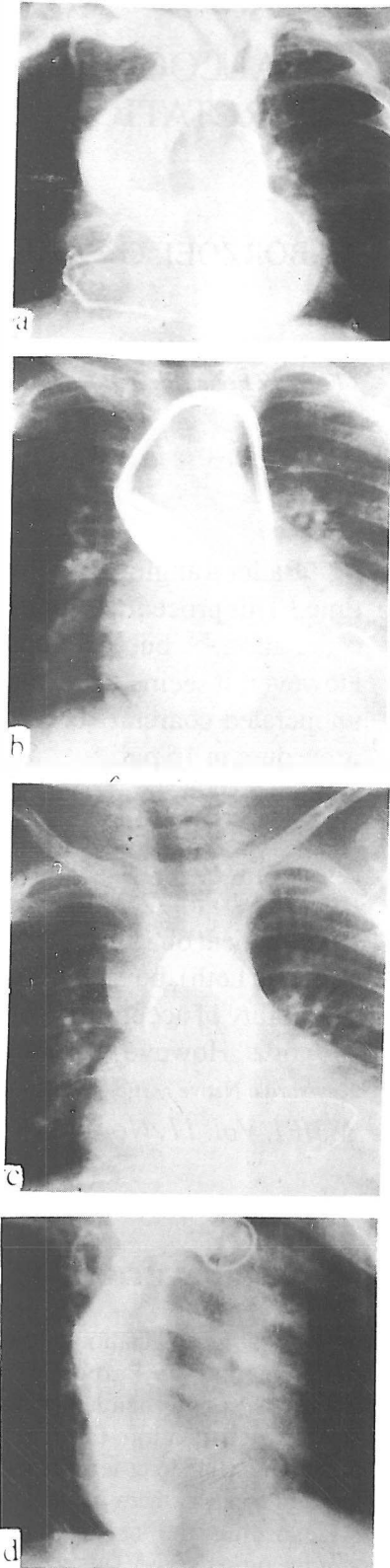


Fig. 2(a-d). Aortogram before intervention (a), balloon valvoplasty (b), angioplasty (c), and postangioplasty (d) views of a 2.5 year old boy with aortic stenosis and coarctation (case no. 14).

Table I. Clinical and paraclinical details of 16 patients with balloon angioplasty for native coarctation of aorta.

Data case No.	Age/Sex (year)	Pressure gradient (mmHg)		Coarctation diameter (mm)		Associated heart lesions	Complications
		B	A*	B	A		
1	12/M	35	12	9	11	isolated	none
2	7/M	50	10	6.6	12	isolated	small aneurysm
3	11/M	60	30	3	5.8	isolated	none
4	9/M	55	13	8.6	14	small VSD <sup>†</sup>	none
5	15/M	50	0	4	9.3	AS, AI	none
6	8/M	45	8	5	9.3	isolated	post-coarctectomy syndrome
7	7m*/M	5	0	2.6	4.6	VSD, PDA, PH <sup>†</sup>	none
8	8/M	53	16	5.2	9	AI	none
9	21m/M	47	20	3.5	6.4	isolated	paradoxical hypertension
10	15/M	95	35	5	11	AI	none
11	7/M	50	20	4.6	12	isolated	none
12	3/M	30	22	3	4	small PDA	paradoxical hypertension
13	8/F	35	0	5	10	dilated CMP <sup>+</sup>	none
14	2.5/M	33	11	3.4	6.4	AS (G=100 mmHg)	post-coarctectomy syndrome none
15	6/F	43	3	4.6	12.4	isolated	aneurysm, and reopening of ductus arter- iosus
16	4m/M	30	5	2.3	4.6	VSD, PH with aortic arch hypoplasia	

\* A= after; B=before ; \*m= month; †VSD= ventricular septal defect, AS= aortic stenosis, AI= aortic insufficiency, PDA= patent ductus arteriosus, PH= pulmonary hypertension; \*CMP= cardiomyopathy.

patients, detected by angiography and/or decreased gradient. The median age at time of angioplasty was 8.2 years (range 4 months to 15 years).

The ratio of males to females was 14:2. Nine patients had associated cardiac lesions, such as aortic valve stenosis, left to right shunt, cardiomyopathy, transposition of great arteries, etc. Three had aortic valve stenosis and valvoplasty was performed in 2 with severe stenosis at the same time (Fig. 2; one case did not show a pressure gradient but CoA was demonstrated angiographically, Fig. 3).

The peak systolic pressure gradient across the coarcted site decreased significantly from  $46.2 \pm 4.8$  mmHg (mean $\pm$ SD) to  $12.2 \pm 2.5$  mmHg immediately after the procedure ( $p < 0.001$ ). The diameter of the coarcted site increased significantly from  $4.7 \pm 0.5$  mm (mean $\pm$ SD) to  $8.8 \pm 0.9$  mm ( $p < 0.05$ ). The femoral pulse at the site opposite to the catheterized artery was well palpable immediately after angioplasty. In two patients (no. 7 and 13) unequal pulses before failed to improve after angioplasty, one due to CHF and the other because of a large left to right shunt. Clinical and echocardiographic follow up revealed restenosis over

the subsequent 8 to 28 months in two patients. There were no deaths, but one developed reopening of the ductus arteriosus and two developed small aneurysms (one patient had both). Two patients developed weak femoral pulses in the catheterized site for a long term. Two had post-coarctectomy syndrome, and paradoxical hypertension was seen in two. None of the patients required immediate surgical intervention. None of them were studied angiographically on follow up.

## DISCUSSION

Balloon intervention for the treatment of obstructive lesions has expanded in many directions, and now includes the treatment of aortic coarctation. Recent studies have demonstrated that balloon angioplasty yields acceptable intermediate and long-term results in patients with postoperative recoarctation.<sup>3,4</sup> Reoperation for these patients is technically hazardous for the surgeon, and may lead to significant complications, such as intraoperative bleeding and paraplegia. According to the report of the VACA registry,

## Balloon Angioplasty in Aortic Coarctation

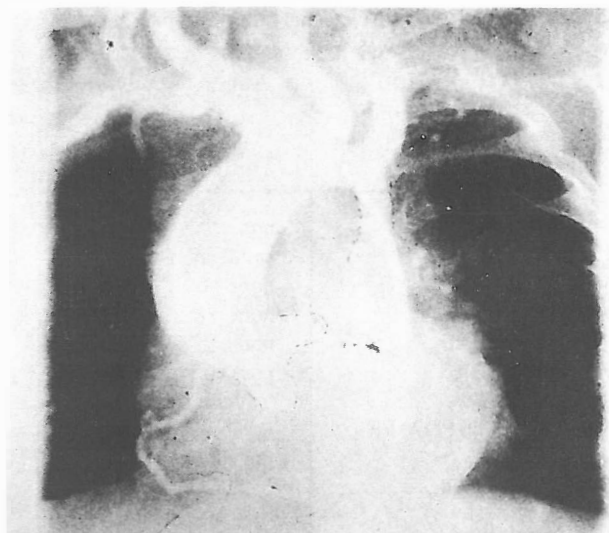


Fig. 3. Angiography of a 5 year old boy with aortic stenosis and coarctation who did not show a gradient of CoA (perhaps due to severe aortic stenosis).

angioplasty is the first-choice treatment for postoperative recoarctation irrespective of the type of surgery.<sup>5,20</sup> In native coarctation on the other hand, there is considerable controversy regarding the effectiveness and safety of angioplasty. In a review of 22 articles, 574 patients who had undergone angioplasty for native CoA had a high success rate. The major complications were death in one infant, CVA in one, paradoxical hypertension in 8, and the most common was aneurysm in 18 patients.<sup>7,10,11-29</sup> In many of these articles, angioplasty for native CoA was reported to be the choice treatment. Mortality was reported to be high in one article (13%), but was insignificant compared to surgery as a control group.<sup>35</sup>

In the present study, the effectiveness and safety of this procedure has been demonstrated, without mortality, and with few major complications. The VACA registry in the United States, nonetheless, reported satisfactory results of dilatation with an acceptably low incidence of fatal complications in patients with native CoA. In neonates with the ductus-dependent coarctation complex, in whom a large duct with right to left shunting coexists with a septal defect, surgical coarctectomy with banding of the pulmonary trunk and division of the duct is considered to be a better choice of treatment than dilatation.<sup>20</sup>

In conclusion, following the advances made in balloon dilatation, acceptable results, and insignificant complications, it may be possible to change the therapeutic strategy for aortic coarctation. In this present study we also found this procedure safe and effective for treatment of CoA. However, further evaluation of its long-term effectiveness with regard to

restenosis will be necessary, particularly in neonates and young infants.

### ACKNOWLEDGEMENT

We wish to thank Dr. R. Gharib for his constructive comments and Ms. Alishahi for secretarial and computer assistance.

### REFERENCES

1. Sos T, Sniderman KW, Rettek-Sos B, Strupp A, Alonso DR: Percutaneous transluminal dilatation of coarctation of thoracic aorta postmortem. *Lancet* 2: 970-971, 1979.
2. Kan JS, White RI Jr, Mitchell SE, Farniott EJ, Donahoo JS, Gardner TJ: Treatment of restenosis of coarctation by percutaneous transluminal angioplasty. *Circulation* 68: 1087-1094, 1983.
3. Hijazi ZM, Fahey JT, Kleinman CS, Hellenbrand WE: Balloon angioplasty for recurrent coarctation of the aorta: immediate and long-term results. *Circulation* 52: 621-631, 1991.
4. Rocchini AP: Balloon angioplasty of postoperative aortic recoarctation. *Prog Pediatr Cardiol* 1: 28-34, 1992.
5. Hellenbrand WE, Allen HD, Golinko RJ, Hagler DJ, Lutin W, Kan J: Balloon angioplasty for aortic recoarctation: results of valvoplasty and angioplasty of congenital anomalies registry. *Am J Cardiol* 65: 793-797, 1990.
6. Lock JE, Niemi T, Burke BA, Einzig S, Castafieda-Zuniga WR: Transluminal angioplasty of experimental aortic coarctation. *Circulation* 66: 1280-1286, 1982.
7. Tyagi S, Arora R, Kaul UA, Sethi KK, Gambhir DS, Khalilullah M: Balloon angioplasty of native coarctation of aorta in adolescents and young adults. *Am Heart J* 123 (3): 674-80, 1992.
8. Dorr R, Kunze KP, Hanrath P: Morphology of aortic isthmus stenosis—invasive study using intravascular ultrasound. *Z-Kardiologie* 81 (8): 445-8, 1992.
9. Rao PS: Balloon angioplasty of aortic coarctation: a review. *Clin Cardiol* 12 (11): 618-20, 1987.
10. Rao PS: Balloon angioplasty for coarctation of the aorta in infancy. *J Pediatr* 110 (5): 713-8, 1987.
11. Rao PS, Chopra PS: Role of balloon angioplasty in the treatment of aortic coarctation. *Ann Thorac Surg* 52 (3): 621-31, 1991.
12. Rao PS, Najjar HN, Mardini MK, Solymar L, Thapar MK: Balloon angioplasty for coarctation of the aorta: immediate and long-term results. *Am Heart J* 115 (3): 657-65, 1988.
13. Fawzy ME, Dunn B, Galal O, Wilson N, Shaikh A, Sriram R, Duran CM: Balloon coarctation angioplasty in adolescents and adults: early and intermediate results.

- Am Heart J 124 (1): 167-71, 1992.
14. Sharma S, Bhagwat AR, Loya YS: Percutaneous balloon angioplasty for native coarctation of the aorta. Early and intermediate term results. *J Assoc Physicians India* 39 (8): 610-3, 1991.
  15. Ray DG, Subramanyan R, Titus T, Tharakan J, Joy J: Balloon angioplasty for native coarctation of aorta in children and adults: factors determining the outcome. *Int J Cardiol* 36 (3): 273-81, 1992.
  16. Ledesma-Velasco M, Ramiresz-Reyes H, Aldana-Perez T: Percutaneous transluminal angioplasty in aortic coarctation in adolescents and adults: mid-term results. *Arch Inst Cardiol Mex* 62 (4): 339-43, 1992.
  17. Zhou A: Congenital aortic coarctation in children treated by percutaneous transluminal balloon angioplasty. *Chug Hua Hsin Hsuan Ping Tsa Chih* 18 (3): 169-71, 1990.
  18. Stein JI, Beitzke A, Suppan C, Lammer J, Fall A: Percutaneous transluminal balloon valvoplasty and balloon angioplasty in congenital heart defects with left heart obstruction in childhood. *Wien Klin Wochenschr* 31: 102 (16): 479-86, 1990.
  19. Galal O, Gomestza B, al-Halees Z, et al: Short and long-term problems in dilatation of untreated aortic isthmus stenosis in children. *Z Kardiol* 79 (7): 518-22, 1990.
  20. Tynan M, Finley JP, Fontes V, Hess J, Kan J: Balloon angioplasty for the treatment of native coarctation: results of valvoplasty and angioplasty of congenital anomalies registry. *Am J Cardiol* 15 : 65 (11): 790-2, 1990.
  21. Rao PS, Carey P: Remodelling of the aorta after successful balloon coarctation angioplasty. *J Am Coll Cardiol* 14 (5): 1312-7, 1989.
  22. Rico J, Sobrino N, Calvo L, et al: Percutaneous transluminal angioplasty in aortic coarctation in young adults. *Rev Esp Cardiol* 42 (6): 415-7, 1989.
  23. Rao PS, Thapar MK, Kutlyli F, Carey P: Causes of recoarctation of unoperated aortic coarctation. *J Am Coll Cardiol* 13 (1): 109-15, 1989.
  24. Alyousef S, Khan N, Nihill M, Lababidi Z, Mullins C: Percutaneous transvenous antegrade balloon angioplasty in aortic isthmus stenosis. *Herz* 13 (1): 36-40, 1988.
  25. Sievert H, Bussmann WD, Pfrommer W, et al: Transluminal angioplasty of aortic isthmus stenosis in juveniles and adults. *Dtsch Med Wochenschr* 112 (36): 1371-3, 1987.
  26. Rao PS: Balloon angioplasty for coarctation of the aorta in infancy. *J Pediatr* 110 (5): 713-8, 1987.
  27. Beekman RH, Rocchini AP, Dick M, et al: Percutaneous balloon angioplasty for native coarctation of the aorta. *J Am Coll Cardiol* 10 (5): 1078-84, 1987.
  28. Wren C, Peart I, Bain H, Hunter S: Balloon dilatation of unoperated aortic coarctation: immediate results and one year follow up. *Br Heart J* 58 (4): 369-73, 1987.
  29. Lababidi ZA, Daskalopoulos DA, Stoeckle H Jr: Transluminal balloon coarctation angioplasty: experience with 27 patients. *Am J Cardiol* 1; 54 (10): 1288-91, 1984.

