

ZYGOMYCOSIS OF COLON CASE REPORT AND REVIEW OF THE LITERATURE

HOSSEIN FOROUTAN,
R. MASHAYEKHI, M.D.

From the Department of Gastroenterology, Imam Khomeini Hospital, Tehran University of Medical Sciences, Tehran, Islamic Republic of Iran.

ABSTRACT

Zygomycosis is a fulminant infection which usually afflicts patients who are immunocompromised by diabetes mellitus, malignancy or immunosuppressive therapy.¹ This disease is a rare but highly invasive fungal infection which occurs in organ transplant recipients.² Mucormycosis confined to the gastrointestinal tract is an uncommon form of the disease, accounting for only seven percent of all mucormycoses.^{3,4} We are reporting a case of gastrointestinal mucormycosis in a young woman, perhaps for the first time in Iran.

Keywords: Infection, fungus, zygomycosis

MJIRI, Vol. 11, No. 1, 53-55, 1997.

INTRODUCTION

A 33 year old woman was admitted to the hospital with icterus. There was a six-month history of intermittent jaundice with mild right upper abdominal quadrant pain and progressive symptoms of general malaise, weakness and anorexia. The patient had never taken any medication or alcohol.

On physical examination, she was deeply icteric. The temperature was 37.3°C, the pulse was 76/min and the respirations were 16/min. Blood pressure was 100/70 mmHg. No skin rash or lymphadenopathy was found. The head, neck, lung and heart were normal. The abdomen was slightly distended due to ascites, and there was mild tenderness in the right upper abdominal quadrant with no guarding or rebound tenderness. There was a palpable liver edge 6 cm below the right costal margin, and the spleen edge was palpable 6 cm below the left costal margin. No prominent venous pattern was observed on the abdominal wall.

There was mild peripheral edema. Rectal examination was normal and a stool specimen was negative for occult blood. The urine was normal except that it contained bilirubin and urobilinogen. The levels of urea nitrogen, creatinine, glucose, uric acid, calcium, phosphorus and electrolytes were normal. The hematocrit was 31 percent, the white

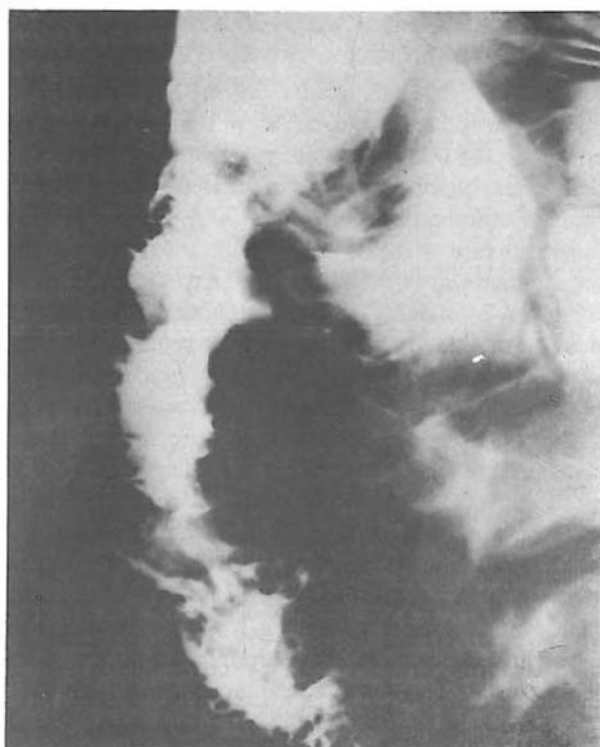

Fig. 1. Barium study of the colon showing multiple mucosal ulcerations and decreased diameter of the ascending colon.

Zygomycosis of Colon



Fig. 2. Cecal area is not involved as evidenced by smooth surface and good distensibility.

cell count was 11,000 per cubic millimeter, the platelet count was 185,000 per cubic millimeter and the mean corpuscular volume was 79 cubic micrometers. The serum aspartate aminotransferase was 400 U/L, and alanine aminotransferase was 260 U/L. The conjugated bilirubin concentration was 14 mg/dL and the total bilirubin concentration was 24 mg/dL. The prothrombin time was 30 seconds (INR: 11) The serum total protein concentration was 5.4 g/dL (albumin: 2.3 g/dL, globulin 3.1 g/dL). The serum level of alpha-1-antitrypsin was normal, as was the serum level of ceruloplasmin. 24 hour urinary excretion of copper was normal. The serologic markers for hepatitis B and C were negative. Other laboratory findings included negative ANA, negative LE cell, and weakly positive ASMA. Paracentesis of ascites revealed a transudative fluid. Radiographs of the chest revealed no specific finding as did the plain abdominal film and upper gastrointestinal barium study with small bowel follow-through.

Endoscopic retrograde cholangiopancreatography revealed no abnormal findings. An ultrasonographic examination of the abdomen showed ascites with enlarged spleen and liver, and the portal vein was dilated with 16 mm

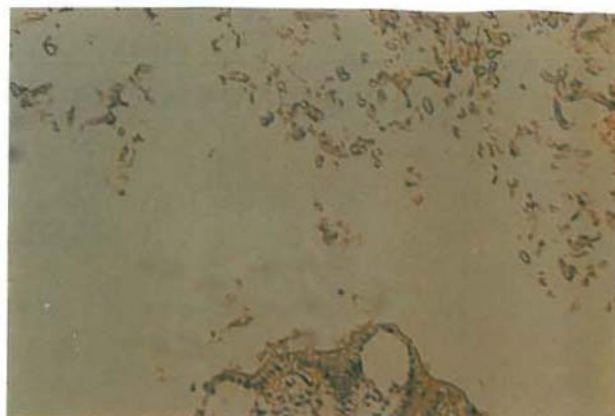


Fig. 3. Colonic mucosa and adjacent hyphae of zygomycosis (muconnycoses) within intestinal lumen (low magnification, H&E staining).

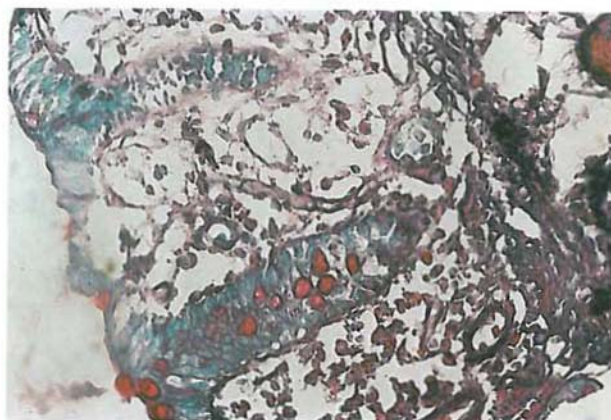


Fig. 4. Non-septate broad hyphae of zygomycosis-note irregular and some right-angle branching and variable thickness of hyphae (high magnification, H&E staining).

diameter in the portahepatic region. Doppler sonographic study of the hepatic veins was normal.

A liver biopsy was performed and showed the pathologic findings of chronic active hepatitis. On the 12th hospital day, prednisolone was started. Two weeks later, hematochezia occurred. Esophagogastroduodenoscopy and proctosigmoidoscopy revealed no abnormal findings. Barium enema of the colon showed multiple mucosal ulcerations and decreased diameter of the ascending colon (Fig 1). Cecal area was normal with a smooth surface and good distensibility (Fig. 2).

Colonoscopy showed granular mucosa with large superficial ulcerations and a circumferential exophytic mass in the ascending colon. The remainder of the colon appeared normal. Multiple biopsy specimens were obtained from the edge and surface of the lesion which was firm and moved en masse during the biopsy. Microscopic examination of the biopsy specimens showed inflammatory reaction with numerous fungal elements composed mostly of branched

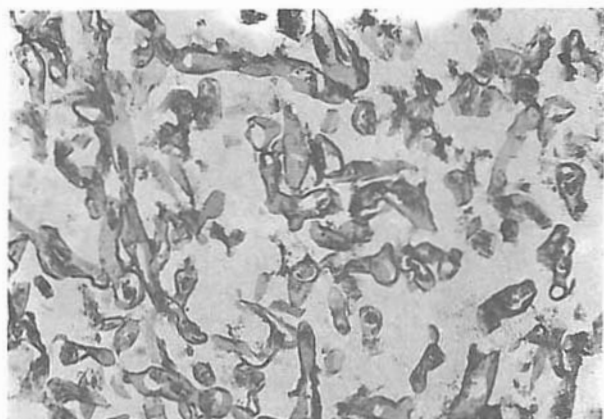


Fig. 5. Presence of zygomycoitic hyphae within mucosa (PAS staining).

nonseptate hyphae spreading throughout the mucosa (Figs. 3-5). The patient received amphotericin B, but the treatment was unsuccessful and unfortunately she died. Her parents did not permit an autopsy.

DISCUSSION

Zygomycosis of the gastrointestinal tract is an unusual form of the disease, and accounted for only 7 percent of all cases of zygomycosis in one review.^{3,4} It is believed that infection of the alimentary tract is acquired through direct ingestion of and invasion by fungal spores.⁵ The infection spreads from the mucosal surface outwards, and a shaggy, velvety discolored surface or large plaque-like area of gray and blackened eschar are characteristic of this infection. Masses of necrotic tissue may mimic carcinoma. Predisposing underlying conditions include local abnormalities of the gastrointestinal tract such as peptic ulceration and post-traumatic peritonitis, prematurity, aplastic anemia, leukemia and diabetic ketoacidosis.^{6,7} There is a strong tendency for the hyphae to invade blood vessels.⁸

Our case had predominant colonic involvement with

minimal involvement of the terminal ileum. Diagnosis usually depends on histologic proof of tissue invasion, as cultures are usually negative and hence unreliable.⁹ The presence of fungal hyphae in the depth of necrotic mucosa and angioinvasion are adequate histologic evidence to establish pathogenicity in this case. This is the rarest form of the disease and review of the literature reveals that only 87 cases have been described with isolated gastrointestinal involvement up to now.⁹ An antemortem diagnosis had been established in only 2 of the 87 reported cases by preoperative biopsy.

The treatment is amphotericin B, coupled with vigorous surgical debridement. In our case surgical debridement was not performed because of poor general condition of the patient.

REFERENCES

1. Craig, NM, et al: Disseminated rhizopus infection in a premature infant. *Pediatric Dermatology* 11: 346-350, 1994.
2. Singh N, et al: Invasive gastrointestinal zygomycosis in a liver transplant recipient. *Clin Infect Dis* 20: 617-620, 1995.
3. Ismail MHA: Gastric mucormycosis. *Tropical Gastroenterology* 11: 103-105, 1990.
4. Lehrer RI, Howard DH, Sypherd PS, et al: Mucormycoses: UCLA conference on mucormycosis. *Ann Int Med* 93: 93-108, 1980.
5. Lyon DT, Schubert TT, Manita AG, Kaplan MM: Phycomycosis of the gastrointestinal tract. *Am J Surg* 137: 287-291, 1979.
6. Thomson SR, Bade PG, Taams M, Chrystal V: Gastrointestinal mucormycosis. *Br J Surg* 78: 952-954, 1991.
7. Mooney JE, Wagner A: Mucormycosis of the gastrointestinal tract in children: report of a case and review of the literature. *Pediatr Infect Dis* 12: 872-876, 1993.
8. Sugar AM: Mucormycosis. *Clin Infect Dis* 14(suppl 1): 126-129, 1992.
9. Gulati S, Berthakur G, et al: Zygomycosis of colon. *Indian Pediatr* 28: 940-943, 1991.

