

# PRACTICAL PROBLEMS AND THE EFFICACY OF INTRAOSSEOUS INFUSION: SOLVING THE PROBLEMS BY EMPLOYING AN ANIMAL MODEL

PEDRAM NIKNAFS, M.D.,  
ALIREZA SOTUDEHNEJAD, M.D.\*, AND  
HAMID TABRIZCHI, M.D.\*\*

*From the Departments of Pediatrics, \*Surgery, and \*\*Pathology, Kerman University of Medical Sciences  
and Health Services, Kerman, Islamic Republic of Iran.*

## ABSTRACT

In critically ill infants and children, intravascular (IV) access is sometimes very difficult. In such cases intraosseous (IO) infusion should be used as the method of choice. However, in practice, different problems are experienced with this procedure. To overcome the practical problems and to confirm the efficacy of IO infusion in reversing hypovolemic shock, an animal model was used by employing three rabbits. In rabbit I, after insertion of a 14-gauge bone marrow aspiration needle in the proximal tibia, the flow rate of normal saline was very slow by gravity, but pressure infusion devices including manual pushing with a syringe, blood pressure cuffs, or infusion pumps all increased the flow rate remarkably. In rabbit II, the circulation time of a dye given by IO route was very short; therefore drugs are expected to appear in the systemic circulation shortly after IO injection. In rabbit III, hypovolemic shock was induced by withdrawing blood and then, rapidly and successfully treated by IO infusion of normal saline.

**Keywords:** Intraosseous infusion, hypovolemic shock, animal model.

*MJIRI, Vol. 10, No. 3, 229-232, 1996.*

## INTRODUCTION

The intravenous (IV) route is still preferred for administration of drugs and fluids, but IV access is often a time consuming and difficult procedure in the resuscitation of critically ill pediatric patients. In one pediatric department, IV access took more than ten minutes in 24% of pediatric cardiopulmonary arrest victims.<sup>1</sup> In 6% of these patients, IV access was never obtained. Such experiments have led to a resurgence in the use of the intraosseous (IO) route to obtain vascular access for pediatric resuscitation efforts. The physiologic basis for the IO route is that the intramedullary vessels and vascular lakes in the bone marrow are protected and supported by hard, noncollapsible bony walls which remain patent in shock or arrest states and are drained into the systemic venous system. Thus, IO infusion is actually a

form of IV infusion.<sup>2-7</sup>

After the resurgence of IO infusion, we were encouraged to employ it in emergency situations. Unfortunately, early practices were not satisfactory and sometimes failed completely. The main reasons for such failure included inability to place a needle in the right position, slow flow rate by gravity, and blockade of infusion after a few minutes. After reviewing the literature it was revealed that many physicians have had such problems with IO infusion.<sup>8</sup> In order to find a solution, we carried out an experimental animal study during which the efficacy of IO infusion in reversing shock was also evaluated.

## HISTORICAL BACKGROUND

The intraosseous route of infusion was first proposed by

Drinker et al.<sup>9</sup> in 1922, and the first human IO infusion performed was described in 1934. The technique gained rapid acceptance in Europe and first appeared in the United States in 1940,<sup>7,9</sup> but a few reports appeared regarding the practical problems encountered with the technique. Therefore during the late 1950s and 1960s IO infusion was superseded by the use of a venous cutdown and plastic catheters that were easier to place than other available IV modes.<sup>9</sup> After this, not much was written about the technique of IO infusion until 1977 when Valdes<sup>8</sup> reported on his experience with 15 patients in whom IV cannulation was difficult or impossible. This report was ignored.<sup>7</sup> The rejuvenation of IO infusion began in 1983 with a letter to the editor of the American Journal of Diseases of Children by Henry Turkel.<sup>6</sup> In response to this letter, the editor invited articles or studies on the technique of IO infusion. Within the last decade, studies have shown that the IO route is as quick and effective as the central IV route and superior to the peripheral IV route in shock or cardiac arrest situations.<sup>7</sup>

### MATERIALS AND METHODS

The study group consisted of three rabbits, which were anesthetized with a combination of ketamine (50 mg/kg) and atropine (0.18 mg/kg). The animals were monitored by a cardiorespiratory neonatal monitor.

In rabbit I, weighing 1.8 kg, a 14-gauge bone marrow aspiration needle was placed in the proximal portion of the tibia. The needle was directed caudally, away from the growth plate, then connected to IV infusion tubing through which normal saline (NS) was running. With gravity infusion, the flow rate was  $1 \pm 0.3$  mL/minute which is not enough to reverse shock. In order to increase the flow rate, we employed different methods, including flushing the needle with heparinized saline, introducing a needle into the IV bag, applying 300 mmHg pressure by a blood pressure cuff around the bag, using an infusion pump, and manual pushing with a syringe.

In rabbit II, weighing 1.3 kg, after anesthesia and intubation, the inferior vena cava (IVC) and the heart were exposed surgically; then, a syringe was introduced into the IVC close to the heart and negative pressure was applied by the syringe. Five seconds after pushing methylene blue-stained saline through the needle which was placed in the proximal tibia, dye appeared in the aspirate.

In rabbit III, weighing 1.0 kg, after anesthesia and intubation, a catheter was placed in the internal jugular vein. At this time (time 0) the experiment was begun by withdrawing 50 mL of blood through the catheter. The central venous pressure (CVP) dropped from the baseline of  $-2$  cm H<sub>2</sub>O (time 0) to  $-4$  cm H<sub>2</sub>O (after 3 minutes). At this time, when the heart rate (HR) dropped from the baseline of 240 beats per minute (bpm) to 30 bpm, the carotid pulse was

no longer palpable and the monitor signaled apnea, the rabbit was in hypovolemic shock. Immediately after developing shock, the needle was placed in the bone and the infusion of normal saline commenced. After infusion of 160 mL of normal saline, CVP increased to  $+4.5$  cm H<sub>2</sub>O, the HR reached 240 bpm (after 13 minutes) and the rabbit was successfully resuscitated.

Rabbits I and III were sacrificed on the following day and rabbit II was sacrificed at the end of the study with a depolarising drug (suxamethonium). Both the experimental and intact tibial bones were removed and sent to the histopathology laboratory for morphologic study. The material was fixed with 10% formalin and decalcified with 5% nitric acid. Four-micron sections were prepared from both right and left tibiae and stained by conventional staining methods.

### RESULTS

In rabbit I, by employing different means to increase the rate of normal saline infusion, we showed that pressure infusion devices such as infusion pumps, blood pressure cuffs, or manual pushing with a syringe all significantly increased the flow rate by IO route (Table I). Our experiment in rabbit II was indicative of a very short circulation time by this route. The reason for not comparing IO with IV circulation time was due to technical problems. Since the most suitable vein for inserting the cutdown catheter is the femoral vein, and the catheter must be advanced cephalad in order to secure its position, the tip of the catheter and the bone marrow aspiration needle would be at different levels and results would not be comparable.

In rabbit III, hypovolemic shock, induced by withdrawing 50 mL of blood, was rapidly and successfully treated by IO infusion of 160 mL of normal saline (Fig. 1).

Microscopic study did not show any significant pathologic alteration in the marrow cavity of the tibial bones of the study animals except for some degree of edema along with dilated and congested blood sinusoids.

### DISCUSSION

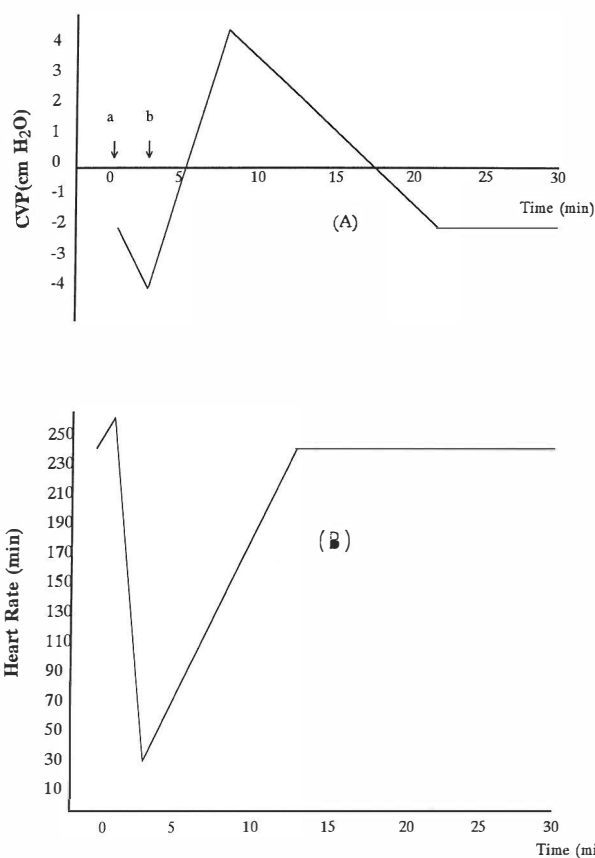
To confirm the position of the needle in the marrow cavity we applied the following criteria<sup>10</sup>:

1. The lack of resistance after the needle passed through the bony cortex.
2. The needle's standing upright without support.
3. Aspiration of bone marrow into the syringe.
4. The infusion's flowing freely without significant subcutaneous infiltration.

One of the most common mistakes is to advance the needle through the opposite side of the bone. This was

**Table I. Different methods for increasing the flow rate of normal saline through a 14-gauge bone marrow aspiration needle placed in the proximal tibia of a rabbit model.**

Time (min)	Means employed to increase flow	Flow rate (mL / min) Mean ± SD
0 - 9	By gravity through an infusion tube	1.0 ± 0.3
10 - 19	Flushing the needle with 3 mL of heparinized saline, then connecting the infusion tube	2.25 ± 0.18
20 - 29	Introducing a needle into the solution bag	2.95 ± 0.32
30 - 39	Infusion pump running at its maximum flow rate	5.0
40 - 49	Applying 300 mmHg pressure by a blood-pressure cuff around the solution bag	7.55 ± 1.65
50 - 53	Manual pushing of fluid with a syringe	>20



**Fig. 1.** Treatment of hypovolemic shock with IO infusion of NS in a rabbit model.

(A): Drop in CVP after withdrawing blood and increase in CVP after IO infusion of NS.

(B): Heart rate monitoring showing severe bradycardia indicating shock and returning to baseline after IO infusion of NS.

IO = intraosseous CVP = central venous pressure

NS = normal saline.

a = blood withdrawal b = placement of the IO needle and infusion of NS.

avoided by applying a piece of a nasogastric or cutdown tube on the shaft of the needle as a depth indicator which prevented forcing the tip of the needle too deep into or through the bone.

We placed the needle in the proximal tibia. This site is suitable for infants less than one year old in whom the needle is usually placed approximately 1 cm below and medial to the tibial tuberosity. In older children and adults, other alternative sites such as the distal tibia and distal femur may be used. To prevent damage of the growth plate it is recommended to push the needle caudally.<sup>8</sup> If extravasation occurs, the needle should be withdrawn and the bone not used as a site for further infusion.<sup>10</sup>

In rabbit II, although we didn't perform a control study to compare the circulation time when using IO infusion with infusion into the femoral vein, Pepper's studies have indicated that circulation times of IO and IV fluid injections are virtually the same.<sup>2</sup>

A number of follow-up studies on bone and bone marrow after IO infusions have been reported and have shown only short-term periostitis and no long-term sequelae.<sup>11</sup> Studies have shown that IO infusions of solutions including saline, bicarbonate, and dopamine do not produce growth disturbances in growing bone or injure the physis, and metaphyseal changes following insertion of a bone marrow needle resolve within 3 weeks.<sup>12</sup> There were no significant pathologic alterations in the marrow cavity of our cases except for some degree of edema and sinusoidal congestion.

Our study showed that a 14-gauge bone marrow aspiration needle was large enough to deliver as much fluid as usually needed in order to resuscitate a rabbit in circulatory shock. As there are not many patients requiring IO infusion, experience with this method is expected to take time unless animal models are used. Technical difficulties decrease with experience and familiarity with the procedure. Since

the satisfactory performance of this study, we have no longer had the problems usually encountered.

In conclusion, IO infusion is a skill that every pediatrician should acquire. As an emergency technique, IO infusion appears to be an effective method by which multiple resuscitation medications as well as large volumes of colloids, crystalloid, and blood may be administered.<sup>1,10,13,14</sup> Ideally, a bone marrow infusion needle should be used.<sup>4</sup> As this kind of needle may not be available in many situations, we suggest a 14 or 16-gauge bone marrow aspiration needle in infants. IO infusion can be performed both in prehospital settings and the emergency department. IO infusion should be used only in cases in which (or as long as) venous access is not possible.<sup>1,9,13,14</sup> We also believe that using animal models may help physicians to learn the IO technique over a short period of time. Experience shows that most young physicians are not aware of the existence and utility of the IO route for emergency administration of drugs and fluids. If even one child's life is saved by the rejuvenation of this technique, the effort has been worthwhile.<sup>3</sup>

The reader is encouraged to consult references No. 7 and 11 regarding the application of IO infusion in humans.

### ACKNOWLEDGEMENT

The authors would like to thank Mr. Behnam Larestani, Technician of Anesthesiology, for his intimate cooperation and Hamid Abdollahi, M.D., Mohsen Janghorbani, M.D., and Mohammad Hossein Daii, M.D. for critical reading of the manuscript.

### REFERENCES

1. Rosetti V, Thompson BM, Aprahamian C: Difficulty and delay in intravascular access in pediatric arrests. *Ann Emerg Med* 13: 406, 1984.
2. Berg RA: Emergency infusion of catecholamine into bone marrow. *AJDC* 138: 810-11, 1984.
3. Orłowski JP: My kingdom for an intraosseous line. *AJDC* 138: 803, 1984.
4. Ryder IG, Munro HM, Doull IJM: Intraosseous infusion for resuscitation. *Arch Dis Child* 66: 1442-3, 1991.
5. Seigler RS, Tecklenburg FW, Sgealy R: Prehospital intraosseous infusion by emergency medical services personnel: a prospective study. *Pediatrics* 84: 173-177, 1989.
6. Turkel H: Intraosseous infusion. *AJDC* 137: 706, 1983.
7. Orłowski JP: Emergency alternatives to intravenous access. *Ped Clin North Am* 41: 1183-99, 1994.
8. Valdes MM: Intraosseous fluid administration in emergencies. *Lancet* June 11: 1235-1236, 1977.
9. Louis PT: Intraosseous infusion: an emergency skill for the pediatrician. *Contemporary Pediatrics* 9: 48-60, 1992.
10. Spivey WH: Intraosseous infusions. *J Pediatr* 111: 639-42, 1987.
11. Rosetti V, Thompson BM, Miller J, et al: Intraosseous infusion: an alternative route of pediatric intravascular access. *Ann Emerg Med* 14: 885-8, 1985.
12. Bielski RJ, Bassett GS, Fideler B, et al: Intraosseous infusions: effects on the immature physis. *J Pediatr Orthop* 13: 511-15, 1993.
13. Guy BJ, Haley K, Zsupan SJ: Use of intraosseous infusion in the pediatric trauma patient. *J Pediatr Surg* 28: 158-61, 1993.
14. Neish SR, Macon MG, Moore JWM, Graeber GM: Intraosseous infusion of hypertonic glucose and dopamine. *AJDC* 142: 878-80, 1988.