

Gallstone ileus and a three centimeters stone in terminal ileum: a case report

Seyed Hamid Moosavy,^{MD¹}, Hossein Froutan,^{MD²}, Mojdeh Habibi,^{MD³}
NesaaAghazadeh,^{MD⁴}, Yasir Andrabi⁵

Dept. of gastroenterology, Imam Khomini Hospital, Tehran University of Medical Sciences.

Abstract

Gallstone ileus is a rare complication of cholelithiasis found in less than 0.5% of patients. It is an uncommon cause of small bowel obstruction, accounting for 1% to 3% of all mechanical bowel obstructions and over 25% of nonstrangulated bowel obstructions in patients older than 65 years with a female predominance.

We report a 60-year-old woman who was referred to our hospital because of abdominal pain, nausea, vomiting and constipation forty days prior to admission. An upright abdominal X-ray showed air fluid levels and an oval calcified opacity in the region of right iliac fossa. The ultrasonographic examination revealed air in biliary tree and several small stones in the gallbladder. Follow up of abdominopelvic CT scan showed severe distention of small intestinal loops, pneumobilia and a 3cm-calci-fied intraluminal mass. The clinical diagnosis of gallstone ileus was made, but un-fortunately her general condition worsened with the decline in Glasgow Coma Scale declined since she was suffered an extensive cerebrovascular accident and eventual-ly she died of cardiac arrest. Inspired by the mentioned case we reviewed the litera-ture on the cause, diagnosis and treatment of gallstone ileus.

Keywords: Cholelithiasis, Gallstone ileus

Introduction

Gallstone ileus is a rare complication of cholelithiasis that is seen in less than 0.5% of patients [1]. The gallstone usually enters the bowel via a cholecystenteric fistula resulting from inflammation and adhesions between the biliary and enteric system following cholecystitis. The stone travels through the bowel and can lodge in different places along the gastrointestinal (GI) tract [2]. However, the clinical diagnosis of gallstone ileus is difficult [1,3,4] and radiographic examinations are frequently inconclu-sive [1,4,5], but the classic presentation of Rigler's triad of small bowel obstruction, pneumobilia, and atypical migrating mineral shadow on plain radiographs may aid in diagnosis [6]. Despite great advances in peri-operative care over the past few years, mortality rates for gallstone ileus remain high, in the region of 15 - 18% [1,7]. This is partly due to the elderly patient population having multiple medical co-morbidities [8]. Since it is a common con-

dition in older age groups with several co-morbidities that restrict the clinician in selecting an appropriate ther-apeutic modality, we decided to report the following case and review the literature on the cause, diagnosis and treatment of gallstone ileus.

Case

A 60-year-old woman was admitted to the emergency department (ED) of our hospital with abdominal pain, loss of appetite and vomiting. Forty days prior to admis-sion, after having a high fat meal, she felt a dull epigastric pain that slowly progressed. This was also accompanied by nausea and vomiting approximately 2 hours after eat-ing her meal. One week prior to admission, she com-plaind of constipation, but never had obstipation. Her past medical history was unremarkable. She did not have any hospitalisation or abdominal surgery, and never ex-perienced similar symptoms before. Her habitual history was negative for cigarette smoking, alcohol, opium or il-

1. **Corresponding author**, Associate Professor of Hormozgan University of Medical Sciences, Gastroenterologist, Shahid Mohammadi Hos-pital Bandarabbas, Hormozgan, Iran. Email:

2. Professor of gastroenterology, Imam Khomini Hospital, Tehran University of Medical Sciences.

3-5. Intern of gastroenterology, Imam Khomini Hospital, Tehran University of Medical Sciences.

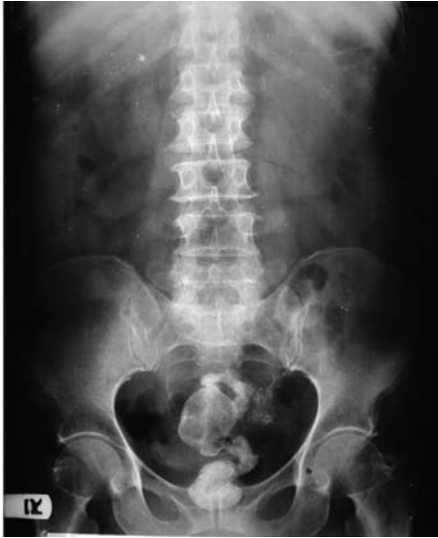

Fig. 1. An oval calcified opacity in right iliac fossa region on plain abdominal X-Ray.

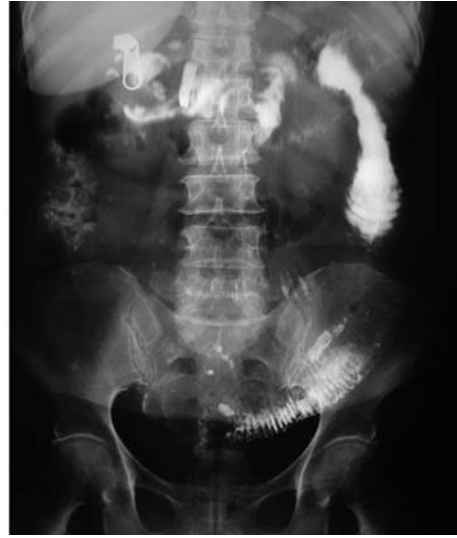

Fig. 2. Post ERCP biliaryenteric fistula on plain abdominal X-Ray.

licit drug consumption. She sought medical care at a local medical centre in her hometown where primary diagnostic evaluations were performed, then she was referred to our hospital for advanced diagnostic and therapeutic evaluation.

Our physical examination in emergency room showed an old woman who looked ill and was mildly dehydrated. She was afebrile. Her conjunctive was pale but she had no jaundice. Her abdominal examination revealed normal bowel sounds and a moderately distended and diffusely tender abdomen without rebound, guarding, or peritoneal irritation on palpation. The rectal exam revealed normal tone with light brown, guaiac-negative stool.

In laboratory findings, white blood cell count was 8800 in each mm³ of blood, hemoglobin was 10.4g/dL, and platelet count was 363000 μ /L (mm³). Liver function tests and amylase were normal. Renal function tests and biochemistry tests were normal.

Air fluid levels, distended intestinal loops and an oval calcified opacity in the region of right iliac fossa were demonstrated in plain abdominal X-ray that was performed immediately. (Figs. 1,2,3).

On ultrasonographic examination, echogenic foci were seen in intrahepatic ducts that were compatible with air, (pneumobilia) along with a shrunken gallbladder that contained several small stones.

Subsequent enhanced computed tomography of abdomen and pelvis disclosed air in the biliary tree, a normal size gallbladder and a dilated common bile duct (CBD) (11mm). A round calcified intraluminal density that was impacted in the terminal ileum lumen along with severe dilation of small intestinal loops approximately 5 cm in diameter were identified. (Fig 4,5,6).

The clinical diagnosis of gallstone ileus was made. The patient was admitted overnight for intravenous hydration and observation. A physical examination on the following morning revealed that her abdominal condition remained unchanged.

Unfortunately, as diagnostic evaluation was being done, patient's general condition worsened. Gradually, she lost orientation to time, place and person. A neurological consultation was sought, and an extensive ischemic cerebrovascular accident was diagnosed. She was transferred to the intensive care unit (ICU) of the hospital, and

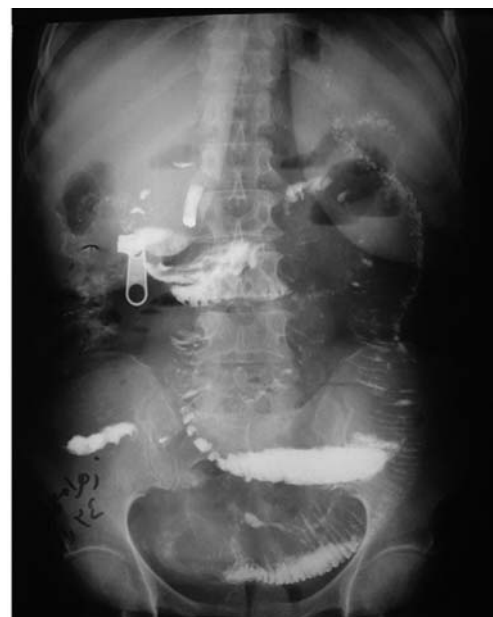

Fig. 3. Post ERCP with air fluid level on plain abdominal X-Ray.

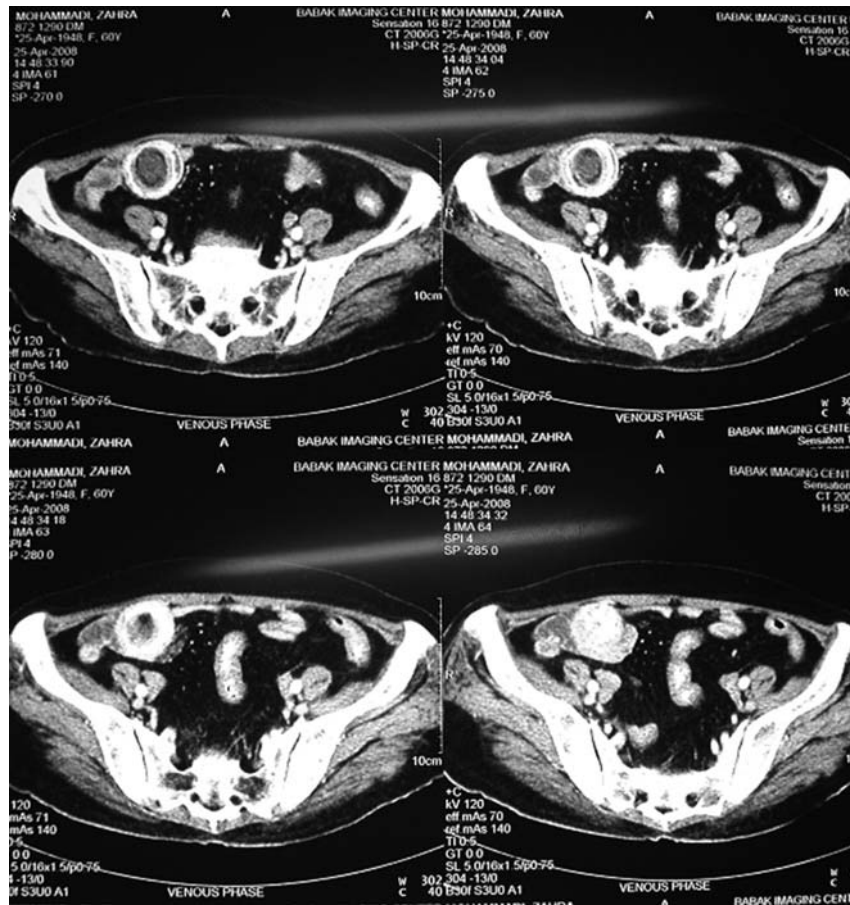


Fig 4. A CT Scan showing gall stone in ileum.

approximately 24 hours later patient expired because of a cardiac arrest.

Discussion

The term "gallstone ileus" was first coined by Bartolin in 1654 and refers to the mechanical intestinal obstruction due to impaction of one or more large gallstones within the GI tract. Gallstone ileus is a rare complication of cholelithiasis, causing 1-3% of mechanical small bowel obstructions, but up to 25% in those aged older than 65

years.[1] The mortality rate of gallstone ileus in the general population is estimated at 15-18%, believed largely to be due to co-morbid conditions in the patient population.[1] Biliary-enteric fistula is the major pathologic mechanism of gallstone ileus[9]. The gallstone enters the GI tract through a fistula between a gangrenous gallbladder and the GI tract. Occasionally a stone may enter the intestine through a fistulous communication between the common bile duct and the GI tract. Although the gallstone can impact anywhere in the GI tract, its size should

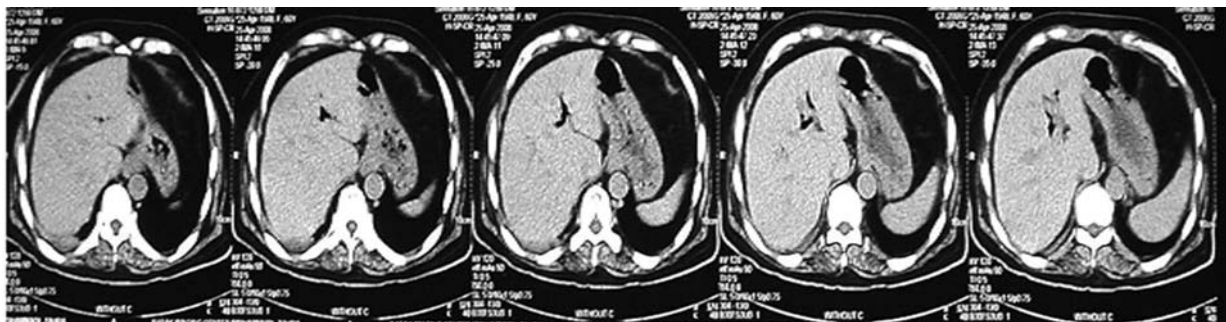


Fig. 5. An abdominal CT scan showing pneumobilia.

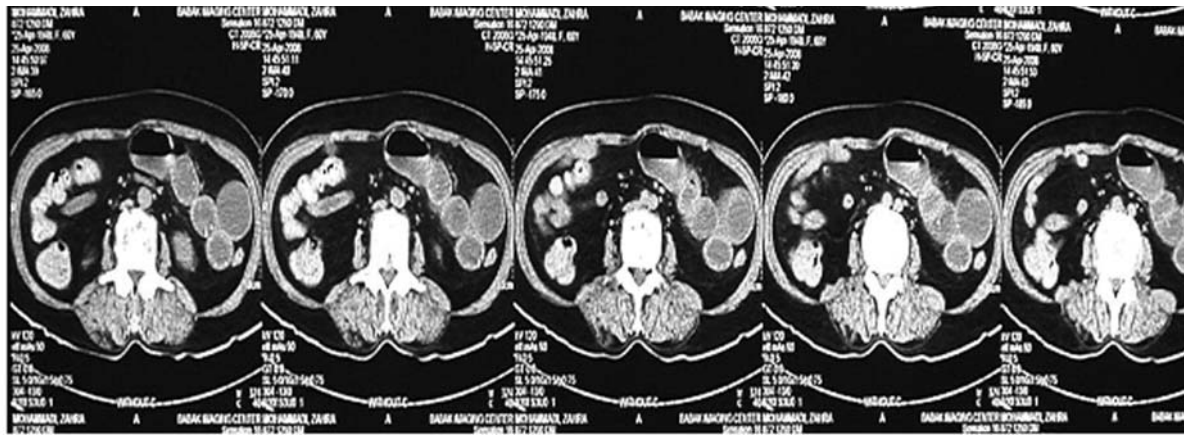


Fig. 6. an abdominal CT Scan showing intestinal obstruction.

be at least 2 cm to 2.5 cm in diameter to cause obstruction [10]. Reisner and Cohen[1] reviewed 1001 cases of gallstone ileus and reported that the most common locations of impaction of gallstone are the terminal ileum and the ileocecal valve because of the anatomical small diameter and less active peristalsis. Fifty to 70 percent of gallstones impact in the ileum, which is the narrowest segment of the intestine. The jejunum and stomach are the next most frequently affected sites. [11] Colonic obstruction tends to occur where there is preexisting pathology, such as a post diverticulitis stricture [11].

The clinical manifestations of gallstone ileus are variable and usually depend on the site of obstruction. The onset may be manifested as acute, intermittent or chronic episodes[12]. The most common symptoms include nausea, vomiting and epigastric pain. Moreover, a small portion of patients may presented with hematemesis secondary to duodenal erosions. Laboratory studies may show an obstructive pattern with elevated values of bilirubin and alkaline phosphatase [11].

Rigler et al. [9] described the classic triad of mechanical small bowel obstruction, ectopic gallstone, and air in the biliary tree on abdominal x-ray film for the diagnosis of gallstone ileus. The presence of 2 of the 3 signs is considered pathognomonic. However, these features are present in only onethird of cases, and the diagnosis is often made only at laparotomy [1]. The findings on plain abdominal films are frequently nonspecific because only 10% of gallstones are sufficiently calcified to be visualized radiographically. Upper or lower gastrointestinal barium studies occasionally identify the site of obstruction or fistula. Abdominal sonography is useful to confirm the presence of cholelithiasis and may identify a fistula, if present [13]. However, abdominal CT becomes the more important modality in diagnosing gallstone ileus because of its better resolution, and when comparing with plain abdominal film and abdominal US, it can provide a more rapid and specific diagnosis in emergency

use. Lassandro et al[14] compared the clinical value of plain abdominal film, abdominal US and abdominal CT in diagnosing 27 cases of gallstone ileus, and found that the Rigler's triad presents 14.81% in plain abdominal film, 11.11% in abdominal US, and 77.78% in abdominal CT, respectively. Yu et al[15] studied the value of abdominal CT in the diagnosis and management of gallstone ileus and concluded that the abdominal CT offers crucial evidence not only for the diagnosis of gallstone ileus but also for decision making in management strategy[15]. Laparoscopy has been rarely used for the diagnosis.[16]

In a comprehensive Medline search, only few cases of gallstone ileus have been reported. The average age of patients in reported of gallstone ileus is 70 years, with the youngest subject being 13 years of age.

Gallstone ileus constitutes a surgical emergency with a difficult clinical and radiologic diagnosis that occurs almost exclusively in the elderly [10-12,18] with a mean age of 77 years (range, 65-88 years). The history, clinical, and radiologic findings are nonspecific, but indicative.[10,18] However, it is mandatory that the exact pre-operative determination be made, or maybe just a suspicion of the cause is adequate for precise diagnosis of in the case of a small bowel obstruction with requirement of an emergency operation. The main purposes treatment in gallstone ileus is early relief of intestinal obstruction and minimization of morbidity and mortality. Previous practice has recommended that enterolithotomy alone should be the standard procedure and that fistula repair and cholecystectomy should be reserved for a later stage, only in the presence of continuing or recurrent symptoms [20-22]. However, nowadays current opinion supports the one-stage approach as the procedure of choice, when feasible; in high-risk patients with severe local biliary conditions, enterolithotomy alone can resolve the emergency situation, and cholecystectomy should be performed at the second stage only if residual symptomatic stones are present [1, 15]. Bowel resection is only indi-

cated when there is intestinal perforation or ischemia[18]. Tan et al[18] compared the two surgical strategies of enterolithotomy alone and enterolithotomy with cholecystectomy for the emergent treatment of gallstone ileus, and concluded that both procedures are safe with no mortality, but the better surgical option is enterolithotomy. Doko et al[19] agreed that the one-stage procedure should be reserved only for highly selected patients with absolute indications. Recently, laparoscopy-guided enterolithotomy has become the preferred surgical approach in treating gallstone ileus[20]. Additionally, the non-surgical treatment of gallstone ileus has been suggested, including endoscopic removal and shock-wave lithotripsy, but this depends on the location of obstruction [21,22].

Gallstone ileus usually has a poor prognosis and worsens with age. The mortality rate, as reported in previous studies, is 7.5%-15%[10], largely due to delayed diagnosis and concomitant conditions such as cardiorespiratory disease, obesity and diabetes mellitus. The post-operative recurrence rate of gallstone ileus is 4.7% and only 10% of patients require secondary biliary surgery for recurrent biliary symptoms [23].

Conclusion

A rare case of gallstone ileus is reported. It is a difficult clinical entity to diagnose and therefore requires a high index of suspicion and must be considered in intestinal obstruction patients with a past history of gallstone, especially in elderly females. Abdominal CT is the preferred modality because of its rapid diagnosis of gallstone ileus. Making an appropriate decision in the surgical management of gallstone ileus is difficult and must be individualized according to patient's age and comorbidities. Most patients benefit from emergent enterolithotomy rather than one-stage procedure (enterolithotomy, cholecystectomy, and fistula repair). The one-stage procedure should be offered only to highly selected patients with good cardiorespiratory reserve and with absolute indications for biliary surgery at the time of presentation.

References

1. Reisner RM, Cohen JR. Gallstone ileus: a review of 1,001 reported cases. *Am Surg.* 1994;60(6):441-446.
2. van Hillo M, van der Vliet JA, Wiggers T, et al. Gallstone obstruction of the intestine: an analysis of ten patients and a review of the literature. *Surgery.* 1987; 101(3):273-276.
3. Day EA, Marks C: Gallstone ileus. Review of the literature and presentation in thirty-four new cases. *Am J Surg* 1975; 129:552-558.

4. Seal EC, Creagh MF, Finch PJ: Gallstone ileus: A new role for computed tomography. *Postgrad Med J* 1995; 71:313-315.

5. Balthazar EJ, Schechter LS: Gallstone ileus. The importance of contrast examinations in the roentgenographic diagnosis. *Am J Roentgenol Radium Ther Nucl Med* 1975; 125:374-379.

6. Doko M, Zovak M, Kopljar M, et al. Comparison of surgical treatments of gallstone ileus: preliminary report. *World J Surg.* 2003;27(4):400-404.

7. Zuegel N, Hehl A, Lindemann F, Witte J: Advantages of one-stage repair in case of gallstone ileus. *Hepatogastroenterology* 1997; 44:59-62.

8. Moberg AC, Montgomery A: Laparoscopically assisted or open enterolithotomy for gallstone ileus. *Br J Surg* 2007; 94:53-57.

9. Rigler LG, Borman CN, Noble JF. Gallstone obstruction: pathogenesis and roentgen manifestations. *JAMA* 1941; 117:1753-9.

10. Rodriguez Hermosa JI, Codina Cazador A, Girones Vila J, Roig Garcia J, Figa Francesch M, Acero Fernandez D. Gallstone Ileus: results of analysis of a series of 40 patients. *Gastroenterol Hepatol* 2001; 24: 489-494.

11. Clavien PA; Richon J; Burgan S; Rohner A Gallstone ileus. *Br J Surg* 1990 Jul;77(7):737-42.

12. Kasahara Y, Umemura H, Shiraha S, Kuyama T, Sakata K, Kubota H. Gallstone ileus. Review of 112 patients in the Japanese literature. *Am J Surg* 1980; 140: 437-440.

13. Lasson A, Loren I, Nilsson A, Nirhov N, Nilsson P. Ultrasonography in gallstone ileus: A diagnostic challenge. *Eur J Surg.* 1995;161:259-263.

14. Lassandro F, Gagliardi N, Scuderi M, Pinto A, Gatta G, Mazzeo R. Gallstone ileus analysis of radiological findings in 27 patients. *Eur J Radiol* 2004; 50: 23-29.

15. Yu CY, Lin CC, Shyu RY, Hsieh CB, Wu HS, Tyan YS, Hwang JI, Liou CH, Chang WC, Chen CY. Value of CT in the diagnosis and management of gallstone ileus. *World J Gastroenterol* 2005; 11: 2142-2147.

16. Agresta F, Bedin N. Gallstone ileus as a complication of acute cholecystitis. Laparoscopic diagnosis and treatment. *Surg Endosc* 2002; 16: 1637.

17. Syme RG. Management of gallstone ileus. *Can J Surg* 1989; 32: 61-64.

18. Tan YM, Wong WK, Ooi LL. A comparison of two surgical strategies for the emergency treatment of gallstone ileus. *Singapore Med J* 2004; 45: 69-72.

19. Doko M, Zovak M, Kopljar M, Glavan E, Ljubicic N, Hochstadter H. Comparison of surgical treatments of gallstone ileus: preliminary report. *World J Surg* 2003; 27: 400-104.

20. Franklin ME Jr, Dorman JP, Schuessler WW. Laparoscopic treatment of gallstone ileus: a case report and

review of the literature. *J Laparoendosc Surg* 1994; 4: 265-272.

21. Dumonceau JM, Delhay M, Deviere J, Baize M, Cremer M. Endoscopic treatment of gastric outlet obstruction caused by a gallstone (Bouveret's syndrome) after extracorporeal shock-wave lithotripsy. *Endoscopy* 1997; 29: 319-321.

22. Meyenberger C, Michel C, Metzger U, Koelz HR. Gallstone ileus treated by extracorporeal shockwave lithotripsy. *Gastrointest Endosc* 1996; 43: 508-511.

23. Van Hillo M, van der Vliet JA, Wiggers T, Obertop H, Terpstra OT, Greep JM. Gallstone obstruction of the intestine: an analysis of ten patients and a review of the literature. *Surgery* 1987; 101: 273-276.