

## DOPPLER ECHOCARDIOGRAPHY IN SUBCLINICAL RHEUMATIC VALVULAR REGURGITATION: A LONG-TERM STUDY

M. BORZOEI AND G.H. AJAMI

*From the Department of Pediatrics, Division of Pediatric Cardiology, Shiraz University of Medical Sciences, Shiraz, Islamic Republic of Iran.*

### ABSTRACT

Doppler echocardiography (DE) is known to be a valuable tool for detecting subclinical forms of valvular regurgitation (VR) in the acute phase of rheumatic fever (RF). Previous studies have mostly dealt with the acute phase problem with only short-term follow-up. In this study, 24 children between 4-15 years of age (mean age  $11.8 \pm 2.7$  years) with RF without clinically diagnosed carditis (most with arthritis) who had two or more DE studies in the course of follow-up (more than 12 months) were assessed utilizing DE.

Twenty-one patients had positive DE findings in one or more valve(s) (87.5%). VR disappeared within 1-8 months (mean  $4.4 \pm 2.3$  mo.) in 9 (42.8%) and persisted in 12 (57.2%) patients during 12-60 months follow-up, whereas DE in children with normal heart structure was rarely associated with left-sided VR ( $P < 0.001$ ). Therefore DE can be a more valuable tool for detection of acute and late phase disease, and follow-up and prevention of RF, and since endocarditis may be the only significant finding of organic cardiac involvement, it may be accepted as a major diagnostic criterion.

**Keywords:** Doppler echocardiography, valvular regurgitation, rheumatic fever.

*MJIRI, Vol. 9, No. 3, 193-195, 1995.*

### INTRODUCTION

Rheumatic fever and rheumatic heart diseases are one of the important causes of mortality and morbidity in developing countries. RF has a fall and rise in prevalence even in the industrial countries.<sup>1,2</sup> Confirmation of the diagnosis of acute and late or prolonged RF when there is no clinical evidence of cardiac involvement is difficult, thus making the decision for prevention duration vital. Arriving at such a decision is made possible by DE in patients with RF in the early phase and at long-term follow-up. Furthermore, subclinical carditis can also be detected by DE. Resurgence of RF in the industrial countries and a relatively high prevalence in developing countries<sup>1,2</sup> make the use of this

new criterion even more important.

### PATIENTS AND METHODS

From December 1988 to May 1994, 99 patients with RF have been studied by DE; 24 patients had two or more DE studies in the follow-up (12-60 months). Age ranged from four to 15 years (mean age  $11.8 \pm 2.7$ ), with 14 boys (58.3%) and 10 girls (41.7%). 115 children 3-15 years of age (mean age  $9.9 \pm 3.5$ ) with 53 boys (46%) and 62 girls (54%) were chosen as the control group. Of the 115 children, 74 (64.3%) had a functional cardiac murmur, 16 (13.9%) had chest pain and 25 (21.7%), non-rheumatic arthritis. All had two-

## Doppler Echo in Subclinical Valvular Regurgitation

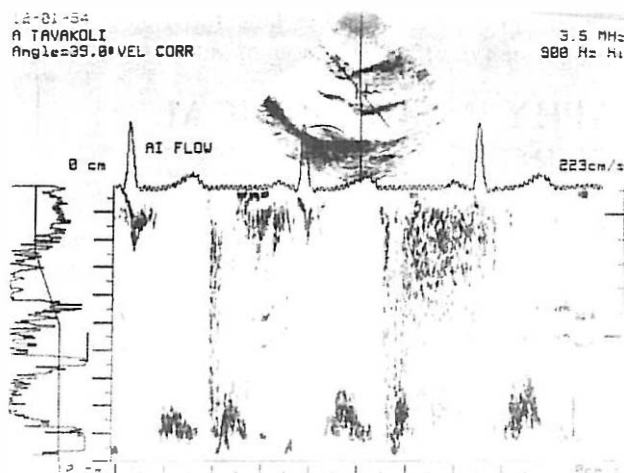


Fig. 1. Doppler echocardiography of aortic insufficiency in a 6 year old female with rheumatic fever without clinical carditis.

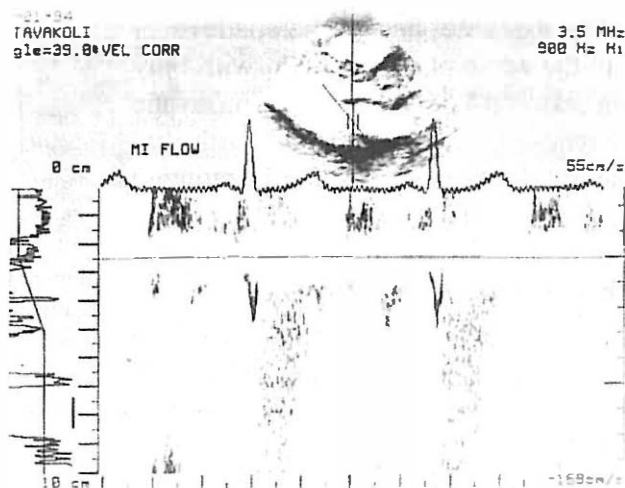


Fig. 2. Doppler echocardiography of mitral regurgitation in the same patient.

dimensional echocardiography Doppler technique for detection of valvular regurgitation. They were examined by Biosounds N-276 and OTE Biomedica SIM-5000 echocardiography units between 1988 and 1994.

mostly done with a 3.5 mHz transducer and with at least two different views for every heart

nary valve which was examined in the parasternal short-axis view. VR was defined as a high-velocity turbulent signal more than 1.5 meter/second proximal to the valve and duration of all or nearly all of the systolic or diastolic phase. VR was defined as trivial when signals were obtained just proximal to the valve, mild when detected in the first third part, and moderate in the second third of the proximal chamber of each valve. Figs. 1 and 2 are Doppler echocardiography tracings of trivial aortic and mitral valve

acute phase findings (no= )	late phase (12-60 months) (no= )
HR (11)	HR (8)
AI (2)	AI (3)
HR+AI (8)	MR+AI (1)
Normal (3)	Normal (12)
Total positive (21)	(12)

Fig. 3. Doppler echocardiography findings in acute and long-term follow-up of 24 patients with rheumatic arthritis without clinical carditis.

MR= mitral regurgitation, AI= aortic insufficiency.

Table I. Doppler echocardiography findings in 115 normally structured hearts.

Doppler echo findings*	No. (%)
1-Tricuspid regurgitation	19(16.5)
2- Pulmonary regurgitation	10(8.6)
3- TR and PR	5(4.3)
4- Mitral regurgitation	1(0.8)
5- Aortic regurgitation	1(0.8)
Total	36(31.3)

\*Two-dimensional echocardiography was normal in all 115 children.

insufficiency in a 6 year old girl with rheumatic arthritis and without clinical carditis.

## RESULTS

Twenty-four RF patients (with rheumatic arthritis) had normal or only a functional murmur on physical exam. Nevertheless, 21 of 24 patients (87.5%) had positive DE findings indicative of one the most common of which was Combined

8 (38.1%) and aortic insufficiency in 2 (9.5%) cases at first DE exam in the acute phase of illness. VR disappeared within 1-8 months (mean  $4.4 \pm 2.3$  mo.) in 9 (42.8%) and persisted in 12 (57.2%) patients during 12-60 months fol-

low-up, with mitral regurgitation remaining the most common (Fig. 3). DE in 115 normal children revealed VR in 36 (31.3%), the most common of which was tricuspid regurgitation in 19 (16.5%), but left-sided AV valve regurgitation was rare, seen in 1 (0.8%) instance

## DISCUSSION

Resurgence of rheumatic fever has been reported in eight locations of the United States and some countries in Europe.<sup>1-3</sup> The prevalence of RF remains high in developing countries.<sup>4</sup> These and unusual forms of RF make important the early diagnosis of illness, especially in suspicious and subclinical forms. Detection and unmasking of silent or subclinical VR by DE has been reported in some articles,<sup>5-7</sup> mostly in the acute phase or short-term.

In this present study, confirmed acute rheumatic fever patients without clinical heart involvement and mostly with arthritis showed a high prevalence (87.5%) of valvular insufficiency on the first DE exam (nearly the same as some other reports, even with a colour Doppler study).<sup>6</sup> The most common valvular involvement was mitral valve insufficiency. The low prevalence of left-sided VR in normal heart-structured children as a control group in this study and other reports,<sup>8-11</sup> adds to the value of DE in the diagnosis of RF without clinically recognizable carditis ( $P < 0.01$ ).

Long-term persistence of VR proven by DE can confirm subclinical residual heart disease which is sometimes the only presenting finding of RF. Therefore, DE may serve as a major criterion of RF and can add to the WHO diagnostic criteria for diagnosis of RF,<sup>12</sup> especially in uncertain cases. It is also valuable in those requiring life-long secondary prevention and endocarditis prophylaxis because reversible clinical and subclinical carditis usually first 8 months of the acute phase and mostly remains beyond 12 months of onset.

## ACKNOWLEDGEMENTS

I wish to thank Dr. R. Gharib for his constructive comments, and Mrs. Rahimi for secretarial work and computer assistance.

## REFERENCES

1. Ayoub EM: Resurgence of rheumatic fever in the United States. *Postgraduate Medicine* 92(3): 133-42, 1992.
2. Bisno A, et al: The rise and fall of rheumatic fever. *JAMA* 259(5): 728-9, 1988.
3. Stollerman GH: The return of rheumatic fever. *Hospital Practice* 15(2): 100-113, 1988.
4. Agrwal BL: Rheumatic heart disease unabated in developing countries. *The Lancet* 8252(2): 910-11, 1981.
5. Steinfeld L, Ritter S: Silent rheumatic mitral regurgitation unmasked by Doppler study (abstract). *Circulation* 74 (suppl 2): 385, 1986.
6. Fogler MG, et al: Occurrence of valvar heart disease in acute rheumatic fever without evident carditis. *Br Heart J* 67: 434-8, 1992.
7. Fogler MG, Rachel H: Doppler echocardiographic finding of mitral and aortic valvar regurgitation in children manifesting only rheumatic arthritis. *Am J Cardiol* 63 (15): 1278-80, 1989.
8. Chong YC, et al: Prevalence of valvular regurgitation by Doppler echocardiography in patients with structurally normal hearts by 2-dimensional echocardiography. *Am Heart J* 1173: 639-42, 1989.
9. Akasaka T, et al: Age-related valvar regurgitation; a study by pulsed Doppler echocardiography. *Circulation* 76(2): 262-5, 1987.
10. Brand A, et al: The prevalence of valvar regurgitation in children with structurally normal hearts. A colour Doppler echocardiography study. *Am Heart J* 123: 177-80, 1992.
11. Yoshida K, et al: Colour Doppler evaluation of valvar regurgitation in normal subjects. *Circulation* 78(41): 840-7, 1988.
12. Alto AW: Acute rheumatic fever: an update. *Am Family Physician* 45(2): 613-9, 1991.