

MANDIBULAR OSTEOSARCOMA MISTAKEN FOR PERICORONAL INFECTION : A CASE REPORT

MOHAMMAD HOSEIN KALANTAR MOTAMEDI, D. D. S.,*
MOHAMMAD HASAN KALANTAR MOTAMEDI, M. D.,**
MOHAMMAD REZA KALANTAR MOTAMEDI, M.D., F.A.C.S.,+
AND ISMAIL YAZDI, D.M.D.†

*From the *Department of Oral, Maxillofacial and Reconstructive Surgery, Baqiyatallah Hospital, Imam Hosein University of Medical Sciences, Tehran, the **Department of Surgery, Baqiyatallah Hospital, Imam Hosein University of Medical Sciences, Tehran, the +Department of Surgery, Shohada Medical Center, Shahid Beheshti University of Medical Sciences, Tehran, and the †Department of Oral Pathology, Tehran University of Medical Sciences, Tehran, Islamic Republic of Iran.*

ABSTRACT

Osteosarcoma is relatively rare in the jaws and variable in presentation, thus its recognition may be quite confusing and delay diagnosis and treatment. Also, in contrast to most malignancies, osteosarcoma is usually encountered earlier in life and may clinically resemble features of more common oral entities such as chronic osteomyelitis, fibrous dysplasia, osteoblastic metastatic carcinoma, ossifying subperiosteal hematoma and chondrosarcoma. Hence definitive treatment may be inadvertently delayed, jeopardizing the chance for cure.

A case of chondroblastic osteosarcoma of the mandible which was mistakenly treated as a pericoronal infection by a dentist is presented. The treatment instituted was continued for several weeks despite progression of the lesion, after which the patient was referred. This delay made necessary a more radical resection than that which would have been needed had the patient been referred earlier.

MJIRI, Vol. 8, No. 4, 271-275, 1995.

INTRODUCTION

Osteosarcoma is a tumor composed of tissues in different stages of bone development. It occurs predominantly in

*Assistant Professor and Chairman, Clinic of Oral, Maxillofacial and Reconstructive Surgery, Baqiyatallah Hospital, Imam Hosein University of Medical Sciences, Tehran.

**Assistant Professor, Department of Surgery, Baqiyatallah Hospital, Imam Hosein University of Medical Sciences, Tehran, and Fellow of Cardiovascular Surgery, Shahid Rajai Heart Hospital, Tehran.

+Associate Professor and Chairman, Department of Surgery, Shohada Medical Center, Shahid Beheshti University of Medical Sciences, Tehran.

†Professor and Chairman, Department of Oral Pathology, Tehran University of Medical Sciences.

long bones, commonly with pain and swelling. Approximately 6 to 7% arise in the jaws, chiefly in the third decade of life. The alveolar ridge of the maxilla and the body of the mandible are the most common sites. It is rare in the facial soft tissues, and occurs twice as often in the mandible than the maxilla with a predilection for males (60%). It is interesting that in sites other than the face, the mean age of occurrence is a decade earlier and trauma has been cited and documented to predispose to its development in half of the reported cases, as have many pre-existing diseases such as Paget's. Surprisingly, none of the reported cases of osteosarcoma of the jaws have had a previous history of either. In the facial bones, only exposure to radiation has been documented to predispose to the development of osteosarcoma. Loose

Mandibular Osteosarcoma

teeth, paresthesia, toothache, bleeding and nasal obstruction are also among the manifestations reported.¹⁻⁵ The jaw lesions have less tendency to metastasize and carry a better prognosis. Metastases are almost exclusively hematogenous and primarily to the lungs, usually within 6 months of diagnosis, while lymph node involvement is extremely rare.⁶

Most investigators divide osteosarcoma into osteoblastic and osteolytic forms, the latter being less differentiated. Histologically, it has traditionally been classified into osteoblastic, chondroblastic and fibroblastic types depending on the matrix components, but it is recognized today that a greater number of microscopic and structural patterns exist such as parosteal, periosteal, telangiectatic, small cell, fibrous histiocytomatous and extraosseous osteosarcoma variants.⁷⁻¹⁶ The chondroblastic type accounts for 10-47% of the jaw lesions and has a more favorable survival rate. A recent review of maxillary osteosarcomas at Sloan-Kettering Cancer Center (New York, NY) has shown the most common histologic variant in that series to be the fibrosarcomatous and fibrohistiocytomatous types, which comprised 50%.¹⁶

Histologically the tumor consists of atypical undifferentiated and disordered osteoblasts with tumor osteoid and bone formation in irregular patterns, which constitute the more common osteoblastic type (60%). Anaplastic fibroblasts are also found to predominate in approximately 34% of the tumors. Some tumors are composed of cartilage and myxomatous tissue, and it is currently believed that these should be diagnosed as osteosarcoma even if it is the chief tissue composing the tumor and if significant malignant osteoblasts or osteoid can be identified, since its course will probably be that of an osteosarcoma rather than a chondrosarcoma. If limited chondroid is present, it is classified as chondroblastic osteosarcoma.¹⁸

CASE REPORT

A 28 year old Iranian male referred to the OMF surgery clinic on April 17, 1992 complaining of swelling of the right side of the lower jaw. Two months before he noticed pain and swelling in the area of the lower right mandibular third molar which presented upon mastication. At that time he referred to his dentist who after obtaining a periapical radiograph of the tooth, noticed bone resorption in the area of the bifurcation and the pericoronal area (Fig. 1). The patient was prescribed antibiotics for one week, after which the tooth was extracted since the swelling had failed to subside. The patient was prescribed antibiotics of a broader spectrum and told that the swelling would subside given time. However, when the swelling increased two weeks later despite extraction of the tooth and antibiotic therapy, the patient was referred.



Fig. 1. The periapical x-ray of the lower right third molar. Note furcation involvement, widening of the PDL and loss of lamina dura.

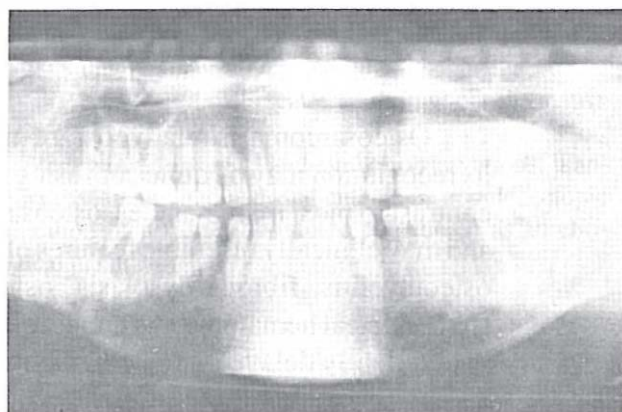


Fig. 2. The OPG x-ray. Note diffuse "cumulus cloud" radiopacity under the right mandibular second molar.

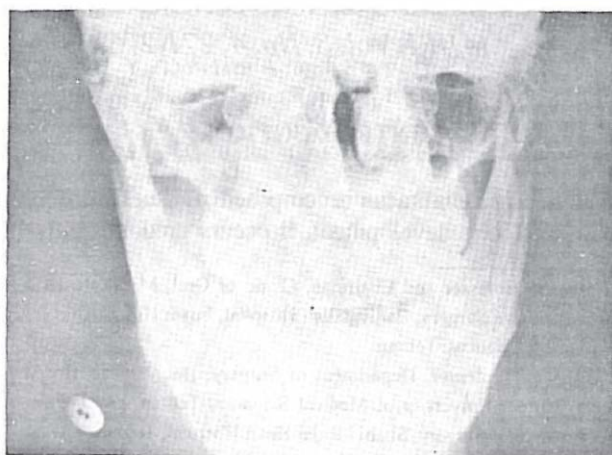


Fig. 3. The PA radiograph of the patient demonstrating the "sun-ray" effect in the area of the right mandibular angle (opposite button).



Fig. 4. The photomicrograph of the specimen. Note neoplastic proliferation of cartilaginous-like tissue, fibroblastic cells and rich vascularization.

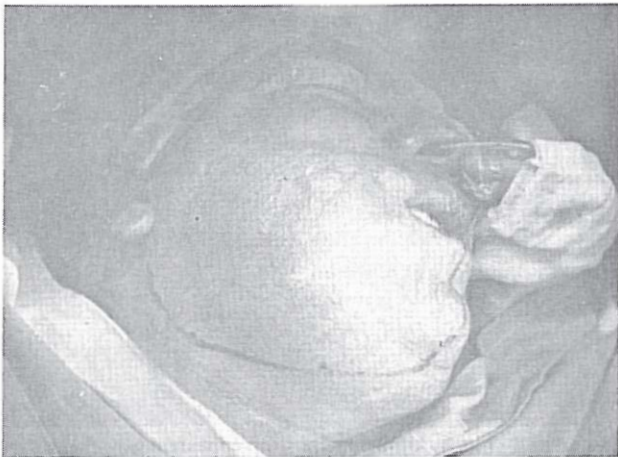

Fig. 5. Outline of the classic lip-split incision for the lower cheek flap approach to the tumor.

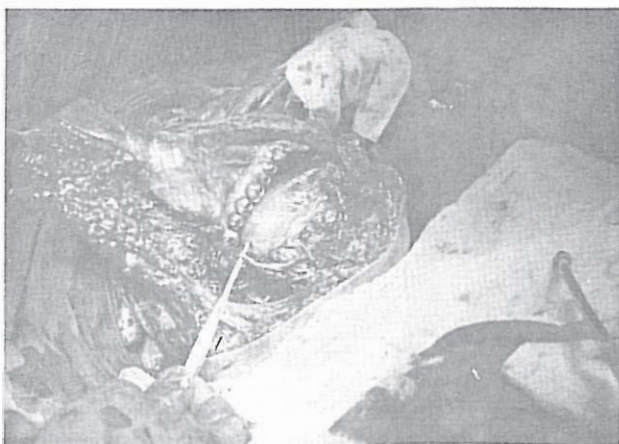

Fig. 6. The cheek flap after disarticulation. Probe demonstrating the lingual nerve.

By this time the patient presented with a firm, slightly tender, intra-oral swelling which now extended from the mandibular angle up to the first premolar tooth. The second molar was also mobile and paresthesia was present up to the corner of the mouth on that side.

On the orthopantomogram (OPG) diffuse hyperdense cumulus cloud type radiopacity was evident with undefined borders in the right molar area of the mandible (Fig. 2). On the PA radiograph of the mandible however, the classic "sun-ray" type bone formation could be seen (Fig. 3). The patient's past medical history was insignificant and he was in good health. Physical examination, chest x-ray, and other lab findings were also non-contributory.

The diagnosis of primary osteosarcoma of the mandible was confirmed via incisional biopsy (Fig. 4). At surgery, a midline lip-split incision was made which extended downward and backward two finger breadths under the border of the mandible to the angle and behind the ramus (Fig. 5). Dissection was begun subcutaneously to the platysma. Intra-orally the lip split incision was continued around the tumor with approximately 3 cm margin of normal tissue converging distally at the retromolar pad. Intraoral dissection was aided by electrocautery and splitting the mandible at the symphysis five centimeters anterior to the lesion both clinically and radiographically. The mandible was then retracted laterally for better access and visualization. All contiguous structures were removed en bloc with the tumor, including the ipsilateral submandibular and sublingual glands. After elevation of the cheek flap the platysma was sectioned 3 cm below the inferior border of the mandible extraorally and removed with the mandible after disarticulation (Figs. 6 and 7).

The masseter and pterygoid muscles were also sectioned 3 cm distal to their insertions prior to disarticulation. A closed suction drain was placed extra-orally and secured and the wound closed in layers (Fig. 8). The patient recovered uneventfully and the marginal mandibular and lingual nerves were spared, although this was not and should not be a primary objective in such a case and they should be sacrificed without hesitation if necessary. Grossly the tumor had not perforated the cortical plates.

The patient received chemotherapy with adriamycin starting two weeks post-operatively. Arch bars had been placed initially at operation on the contralateral side prior to resection and were maintained in fixation for six weeks, after which elastics were used for an additional two weeks, at which time the patient was able to open and close the jaw without deviation. An acrylic appliance was then fabricated for the maxilla with a guide plane to keep the mandible in proper alignment with the upper arch and prevent deviation due to muscle pull. The patient was well with no sign of recurrence 30 months postoperatively and is currently scheduled for reconstruction (Fig. 9).

DISCUSSION

Osteosarcoma has an extremely rapid clinical course and may actually increase in size while under observation—hence it must be given immediate attention.²⁰ The presenting signs and symptoms are few and various,²¹ and this fact may delay diagnosis and treatment. Apparently the primary difficulty encountered in the diagnosis of jaw lesions appears to be that the clinical features of a number of common dental disorders resemble those of rapidly growing osteosarcoma, i. e. chronic osteomyelitis (which can cause paresthesia and tooth mobility similar to malignancy), fibrous dysplasia, osteoblastic metastatic carcinoma, ossifying subperiosteal hematoma and chondrosarcoma.^{6, 21}

Osteosarcoma is generally thought to arise from primitive undifferentiated cells and from malignant transformation of osteoblasts. In the mandible, paresthesia of the lower lip is important and almost pathognomonic for a malignancy invading the neurovascular bundle. When the jaws are involved tumor cells can rapidly spread through the PDL and resorb both tooth and alveolar bone, producing a widened PDL space on the radiograph. Widening of the periodontal membrane space, "Sun-ray" effect and widening of the mandibular canal radiographically seem to be almost pathognomonic for osteosarcoma.

Other characteristic appearances are the "cumulus cloud" or triangular projecting radioopacities called "Codman's triangles". Sometimes periosteal bone deposition in an "onion skin" pattern may also be seen.^{1, 5, 6} It has been recognized that osteosarcoma may produce satellite lesions within the medullary canal of the bone involved proximal to the major lesion. These "skip lesions" are usually not seen on radiographs and are discovered only on pathological examination of the specimen, thus suggesting that resection should be performed at a level proximal to the tumor.^{16, 18}

The osteolytic type of osteosarcoma and those of the maxilla appear to carry the worst prognosis. The literature reveals that patients treated initially by radical surgical resection have had the best survival rate, up to 80 percent.²⁰ Preoperative and postoperative chemotherapy have also had favorable results.²³⁻²⁵ However, radiotherapy although advocated by some does not appear to improve survival rates in patients with mandibular osteosarcoma.^{16, 18, 20} Adriamycin, high dose methotrexate and cis-platinum have shown definite effects in the treatment of the tumor, and when these are used in combination with definitive surgical therapy, most current studies report a 50% 5-year disease-free survival rate.¹⁸

CONCLUSION

Osteosarcoma of the jaws is characterized by aggressive behavior and difficulty in obtaining local control. The 5-

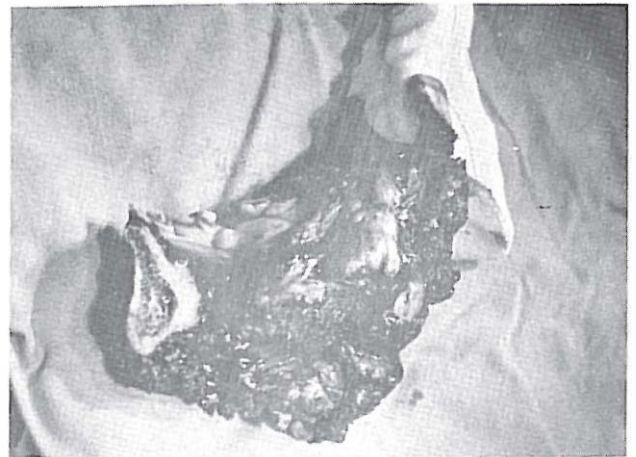


Fig. 7. The pathologic specimen along with all contiguous structures and the submandibular and sublingual glands.

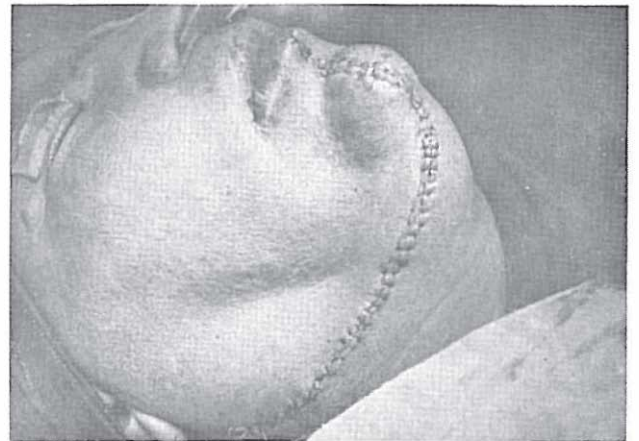

Fig. 8. Immediate post-op appearance.




Fig. 9. Appearance of the patient 30 months post-operatively, demonstrating complete facial nerve function despite extensive hard and soft tissue resection.

year survival rate of patients treated for osteosarcoma of the mandible has varied considerably between 25 to 80 percent, again variability due to the stage of the tumor and adequacy of resection since limited resections have carried 27% survival. Thus initial radical surgery is the treatment of choice and a 75 to 100 percent survival may well be expected.^{1, 22, 26}

Since the tumor extends microscopically along marrow spaces without clinical or radiographic evidence and may produce satellite lesions within the medullary canal,^{18, 29, 30} treatment must be radical if there is to be hope of curing the patient. A reduction in hematogenous spread and the margins of surgical resection for osteosarcoma of the extremities have been demonstrated by use of chemotherapy, thus advocating its use in other bones of the body but until prospective studies demonstrate its effectiveness for osteosarcoma of the jaws, the cornerstone of treatment remains initial radical surgery. Resection of pulmonary metastases has also prolonged life in some patients and in a smaller number it has apparently eradicated the disease.^{18, 22-28, 30}

Presented is a case report of chondroblastic osteosarcoma of the mandible. This case was unusual because the lesion had manifested and presented as a pericoronitis confusing his dentist and prolonging the period of disease before definitive treatment. The young age of the patient and inconspicuous signs and symptoms must not preclude early diagnosis, biopsy and immediate surgery in order that the potentially high morbidity and mortality inherent with the tumor may be minimized.

REFERENCES

- Garrington GE, et al: Osteosarcoma of the jaws: Analysis of 56 cases. *Cancer* 20:377, 1967.
- Coventy MB, Dahlin DC: Osteosarcoma. *J Bone Joint Surg* 39: 741, 1957.
- Kragh LV, Dahlin DC: Cartilaginous tumors of the jaws and facial region. *Am J Surg* 99:852, 1960.
- Parsons WH, et al: Extraskelatal osteogenic sarcoma. *Ann Surg* 119:595, 1944.
- Yagan R, et al: Involvement of the mandibular canal: early sign of osteogenic sarcoma of the mandible. *Oral Surg* 50:56, 1985.
- Wood NK, Goaz NW: *Differential Diagnosis of Oral Lesions*. St. Louis, C. V. Mosby Co. 3rd ed, pp. 455-7, 1985.
- Colmenero et al: Osteogenic sarcoma of the jaws, MFH subtype. *J Oromaxillofac Surg* 48: 1325-1328, 1990.
- Yunis et al: Histologic diversity of osteosarcoma. *Path Ann* 21:121, 1986.
- Dahlin DC, Unni KK: Osteosarcoma of bone and its important recognizable varieties. *Am J Surg Path* 1:61, 1977.
- Uribe-Botero G, et al: Primary osteosarcoma of bone. *Am J Clin Path* 67:427, 1977.
- Unni KK, Dahlin DC et al: Introosseous well differentiated osteosarcoma. *Cancer* 40:1337, 1977.
- Sim F, Unni KK, et al: Osteosarcoma with small cells simulating Ewing's tumor. *J Bone Joint Surg* 62A:207, 1979.
- Ahuja SC, et al: Parosteal osteogenic sarcoma. Histological grading and prognosis. *J Bone Joint Surg* 59A:632, 1977.
- Pora AN, Smith JL: Osteogenic sarcoma and parosteal osteogenic sarcoma of the maxilla and mandible: study of 20 cases. *Am J Clin Path* 54:625, 1970.
- Unni KK, Dahlin DC: Periosteal osteogenic sarcoma. *Cancer* 37:2476, 1976.
- Vincent SD, Lilly GE, Ruskin JD: Recurrent enlargement of the left maxillary alveolus. *J Oral Maxillofac Surg* 51: 671-675, 1993.
- Gardner DG, Mills DM: The widened periodontal ligament of osteosarcoma of the jaws. *Oral Surg* 41:652, 1976.
- Harrelson JM, Callaghan JJ: Infections and neoplasms of bone. In Sabiston DC: *Textbook of Surgery*. 14th ed. Philadelphia, W. B. Saunders, 1991, p. 1359.
- Shafer WG, Hine MK, Levy BM: *Textbook of Oral Pathology*. 4th ed, pp. 180-3, Philadelphia, W.B. Saunders, 1983.
- Linqvist C, et al: Osteosarcoma of the mandible. *J Oromaxillofac Surg* 44:759, 1986.
- Kragh LV, Dahlin DC: Osteogenic sarcoma of the jaws and facial bones. *Am J Surg* 96:496, 1958.
- Clark L, Unni KK, Dahlin DC: Osteosarcoma of the jaws. *Cancer* 51:2311, 1983.
- Rosen S: Preoperative chemotherapy for osteogenic sarcoma. *Cancer* 6:121, 1982.
- High CL, Glass KT: Osteosarcoma of the mandible. *Oral Surg* 45:678-684, 1978.
- Jaffe W, et al: Osteosarcoma: intra-arterial treatment of the primary with cis-diamine-dichloroplatinum II (CDP). *Cancer* 51:402-407, 1983.
- Caron AS, et al: Osteogenic sarcoma of the facial and cranial bones. A review of 43 cases. *Am J Surg* 122:719, 1971.
- Reyes JM, et al: Osteogenic sarcoma of the tongue. *Oral Surg* 51:421, 1981.
- Ryan RF, et al: Osteogenic sarcoma of the mandible: A plea of initial radical surgery. *J Bone Joint Surg* 78:41, 1986.
- Upshaw JE, et al: Extension of primary neoplasm of bone to marrow. *Surg Gyn Obstet* 89:704, 1949.
- Pease GL, et al: Surgical management of osteosarcoma of the mandible. *Arch Otolaryngol* 101:761, 1975.
- Shah JP: *Atlas of Head and Neck Surgery*. London, Wolfe Medical Ltd. pp. 41-42, 1990.