

NEUROFIBROMATOSIS PRESENTING AS SCROTAL ELEPHANTIASIS

M.R. RAZZAGHI, M.D., A.R. HONARMAND, M.D., AND
M.R. RAFII, M.D.*

*From the Departments of Urology and *Pathology, Medical School, Shahid Beheshti University of Medical Sciences, Tehran, Islamic Republic of Iran.*

ABSTRACT

Neurofibromatosis being manifested as scrotal elephantiasis is a very rare condition and in review of the literature no such presentation was found. Here we report a 20 year old man who presented with scrotal elephantiasis and consequently, a pathological diagnosis of neurofibromatosis was reached.

MJIRI, Vol. 8, No. 2, 137-139, 1994.

Keywords: Scrotal mass, Neurofibromatosis, Elephantiasis, Scrotal lymphedema

INTRODUCTION

Neurofibromatosis may involve the scrotum as an isolated lesion without other manifestations of von Recklinghausen's disease, but it is a very rare manifestation and in review of the literature we found only two cases.

Even more rare is neurofibromatosis presenting as scrotal elephantiasis. We could not find any such case in the literature. Here we present a 20 year old man who developed painless scrotal enlargement over three years and on referral had huge scrotal elephantiasis. The patient underwent operation and neurofibromatosis was diagnosed.

CASE REPORT

A 20 year old man from Iraq who has been living in Iran for 13 years presented with a chief complaint of painless scrotal enlargement of three years' duration (Fig. 1). He gave no history of any hereditary or familial disease. There were no accompanying symptoms such as fever, anorexia, weight loss, or malaise. On physical examination the scrotum was hugely enlarged and nearly 30cm in diameter. It was firm and rubbery, dark colored and had a crusting surface with pitting edema on finger pressure. The posterior

scrotal surface had areas of pressure sores and cellulitis with purulent discharge. Inguinal lymph nodes were normal. The physical exam was otherwise unremarkable. No café au lait spots were seen.

Lab data revealed a normal CBC and peripheral smear and eosinophilia was not detected. Also peripheral smears performed at different times throughout the day and night with special staining techniques for detecting microfilariae were negative. The ESR was increased to 100mm in the first hour. Serum electrolytes, liver function tests and renal

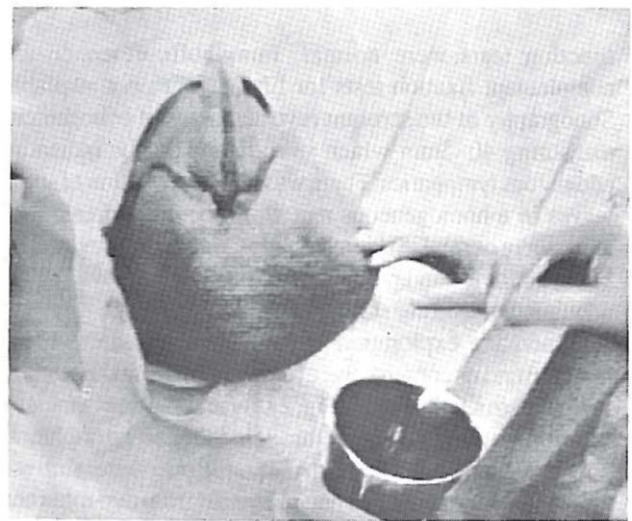


Fig. 1. Gross picture of scrotum before surgery.

M.R. Razzaghi, M.D., Assistant Professor of Urology,
A.R. Honarmand, M.D., Resident of Urology, and
M.R. Rafii, M.D., Professor of Pathology,
Shahid Beheshti University of Medical Sciences, Tehran.

Neurofibromatosis as Scrotal Elephantiasis

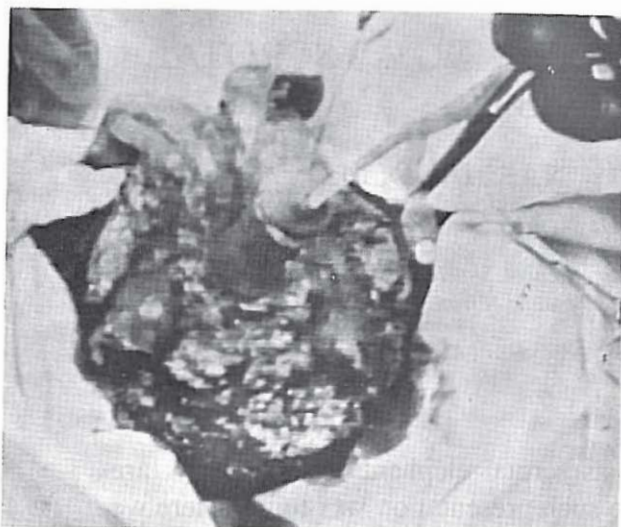


Fig. 2, A. Postoperative result following removal of the scrotal mass.

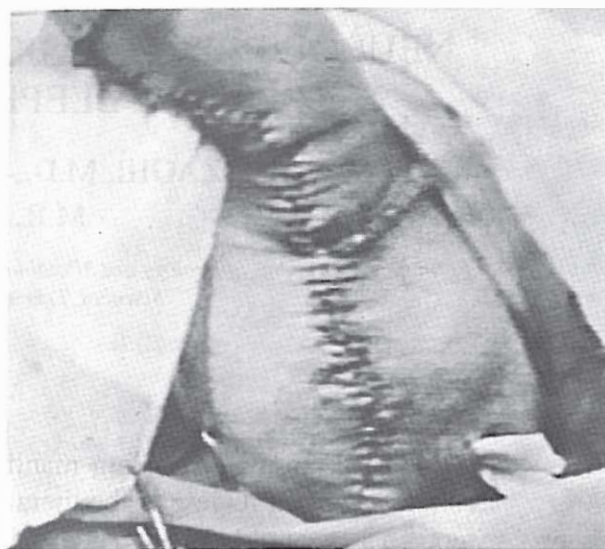

Fig. 3. Postoperative result demonstrating the newly constructed scrotum.




Fig. 2, B. Gross mass of scrotum weighing nearly 10 lbs.

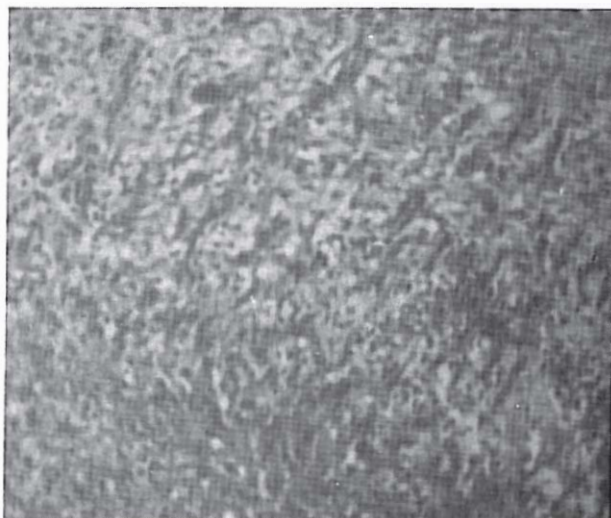


Fig. 4. Microscopic section of scrotal mass.

function tests were normal. Immunofluorescence and complement fixation tests for filariae were not available. Sonography of the scrotum revealed areas of echogenicity measuring 40x5mm which were thought to be indicating edematous lymphatics. There was good conduction of sound waves in a homogeneous pattern in the other areas. Both testes were normal in size and shape. Sonographic evaluation of the abdomen and pelvis was normal with no evidence of adenopathy. The chest x-ray was also normal.

Operative exploration was performed and the whole scrotum and its contents were removed, leaving the testicles and cord structures intact (Fig. 2). By making a circumcision incision and extending it through the median raphe, all subcutaneous tissues beneath the penile skin were removed. The testes were put into a pouch created from two rotational flaps from the skin of the inguinal region (Fig. 3).

On microscopic sections, long sheets of neoplastic tissues were seen with interlacing bundles of elongated cells in between fibroblasts and fibrocytes. A few satellite cells and multinuclear cells with slight pleomorphism were also seen. No significant numbers of mitoses were detectable. The pathological diagnosis was a giant neurofibroma (Fig. 4).

DISCUSSION

Von Recklinghausen's disease is an inheritable disease in which areas of increased skin pigmentation are combined with multiple neurofibromas. Although neurofibromatosis

is hereditary, nearly 50% of cases appear to be caused by mutations. Solitary neurofibromas, like their inherited counterparts affect both sexes equally, and they usually develop in patients who are in their 20s and the majority of them have superficial lesions of the dermis or subcutis. The tumors arise from the neurilemmal sheath (Schwann cells), and fibroblasts of peripheral nerves. Most of these tumors cause no symptoms, but occasionally, if they attain a large size or occupy an unusual position, they may cause pressure upon contiguous structures. In about 5-10% of cases of neurofibromatosis one of the tumors will become sarcomatous. About one-third of cases are discovered incidentally in asymptomatic patients undergoing routine clinical examinations. Another one-third of the patients come seeking advice concerning their cosmetic appearance and the remainder present with neurologic symptoms. There

is no treatment for the disease other than surgical excision of the tumors.

REFERENCES

1. Elliot FG, Eid TC, Lakey WH: Genito urinary neurofibromas: clinical significance. *J Urol* 125: 725, 1981.
2. Yoshimura K, Maeda D, Saiki S: Solitary neurofibroma of the scrotum. *J Urol* 143: 23, 1990.
3. Levant B, Chetlin MA: Neurofibroma of tunica albuginea testis. *J Urol* 59: 1187, 1948.
4. Livolsi VA, Schiff M: Myxoid neurofibroma of the testis. *J Urol* 118: 341, 1977.
5. Yamamoto M, Miyake K, Mitsuya H: Intrascrotal extratesticular neurofibroma. *Urology* 20: 200, 1982.