

EVALUATION OF THE ROLE OF CELL-MEDIATED IMMUNITY IN DERMATOPHYTOSIS

A.R. KHOSRAVI,* M. FRANCO,** AND M. MAHMOUDI[†]

From the [†]Faculty of Veterinary Medicine, and ^{*}School of Public Health, Tehran University, and the
^{**}Department of Pathology, School of Medicine and Immunology Division, UNESP, Botucatu, Brazil.

ABSTRACT

For demonstration of cell-mediated immunity and its role in the process of dermatophytosis, 98 patients with acute dermatophytosis (group 1) and 131 chronic dermatophytosis patients (group 2) were chosen. In all patients, lymphocyte transformation and skin test were used. 96 members of group 1 (98%) had positive delayed-type hypersensitivity (DTH) responses to trichophytin, whereas only 43 subjects (32.8%) of group 2 had positive DTH responses. In group 1, positive lymphocyte blastogenic responses to trichophytin and phytohemagglutinin were seen in 95 (96.9%) and 98 (100%) patients, respectively, but in group 2 the positive results were observed in 49 (34.4%) and 127 (94.9%) subjects, respectively. Patients with chronic dermatophytosis had histories of a number of systemic disorders such as: atopy 64 patients; diabetes, seven patients; contact dermatitis, four patients; and tuberculosis, three patients.

MJIRI, Vol. 7, No. 3, 165-169, 1993.

INTRODUCTION

Dermatophytic infections are very superficial in location (i.e., generally confined to the stratum corneum), and it might seem reasonable to assume that this type of infection would not sensitize the host.¹ However, the disease process is greatly influenced by the host response to dermatophyte infection. There are a number of studies on the immunology of dermatophytosis.^{2,3,4} Hosts infected with dermatophytes usually develop cellular hypersensitivity.¹

Several studies have demonstrated that animals, experimentally infected with dermatophytes, generally develop delayed hypersensitivity to antigens of the infecting agent.^{5,6,7} Delayed hypersensitivity responses appear to be important in the development and clearance of the lesions of dermatophytosis.¹ Kerbs et al.⁵ found that in guinea pigs

with experimental *Trichophyton mentagrophytes* infections, the degree of maximal erythema occurred when the animals developed cell-mediated immunity.

Lepper⁸ noted that in cattle infected with *T. verrucosum*, the development of inflammation in primary infections coincided with the development of delayed hypersensitivity to fungal antigens.

Green et al.,⁹ used *T. mentagrophytes* infections of guinea pig skin grafts on nude mice to demonstrate that cell-mediated immunity is required to sustain inflammation in the infected skin and to eliminate the infecting organisms. In the bovine model of dermatophytosis, delayed-hypersensitivity reactions appeared to promote the clearance of the infection by increasing the rate of desquamation of the stratum corneum.⁸

In man, the importance of cell-mediated immunity, as manifested by delayed-hypersensitivity responses to trichophytin, in the resistance to dermatophytosis has been demonstrated by experimental infections; subjects with positive delayed tests appear to be relatively immune to experimental inoculation with *T. mentagrophytes*, whereas

Correspondence Address: A.R. Khosravi, Department of Medical Mycology, Faculty of Veterinary Medicine, University of Tehran, P.O.Box 14155-6453, Tehran, Iran.

Cell-Mediated Immunity in Dermatophytosis

chronically infected subjects with negative delayed skin tests were susceptible.⁸⁻¹³

PATIENTS AND METHODS

229 patients were selected for this study. The patients, based on types of ringworm, were divided into 2 groups as follows:

Group 1: In this group 98 subjects with acute dermatophytosis were chosen. The duration of their infection ranged from 1 to 3 months (mean duration, 2.5 months). Their ages ranged from 11 to 36 years (mean age, 19 years).

Group 2: In this group, 131 subjects with chronic dermatophytosis were selected. The duration of their infection ranged from 7 to 38 years (mean duration, 21 years), the age range being from 41 to 65 years (mean age, 51 years).

Trichophytin (Cruickshank) was used for skin test in all 229 patients. Each individual was questioned for a personal history of medical problems such as acne, psoriasis, contact dermatitis, diabetes, and atopy.

Skin Test

Trichophytin was used in saline solution. The patients were injected intradermally on the volar aspect of the forearm, with trichophytin (10 µg/0.1 mL).

The sites of injection were observed to determine the size and degree of erythema, and degree of induration at 30 minutes, 24, 48, and 72 hours.

At 20 minutes reading, a wheal greater than 10 mm in diameter, with or without a flare, was considered a positive immediate reaction. The DTH reaction were interpreted as positive if any degree of erythema, edema, or induration was present at the 72 hours reading.

Lymphocyte Transformation Test (LTT)

For LTT, 30 mL of blood from each patient was aspirated into sterile syringes containing 1: 500 U heparin and 2.0 mL of 8% dextran. The blood was sedimented for 35 min at the room temperature. Lymphocytes were isolated and washed three times in HBSS.

For culture of lymphocytes, RPMI 1640 medium which contained 15% heat-inactivated guinea pig serum, 10 mM hepes buffer, 100 µg/mL streptomycin, 100 U/mL penicillin, 0.29 mg/mL L-glutamine, and 0.15% sodium bicarbonate was used. Cells were cultured in microtiter plate at 5×10^5 cells per well in 0.2 mL of medium. The mitogens were added in the following concentration: Phytohemagglutinin (PHA) 4 µg/mL and trichophytin, 5 µg/mL. Microcultures were incubated at 37°C in a humidified atmosphere of 5% CO₂ in air for three days.

Then, tritiated thymidine (0.5 cell per well) was added

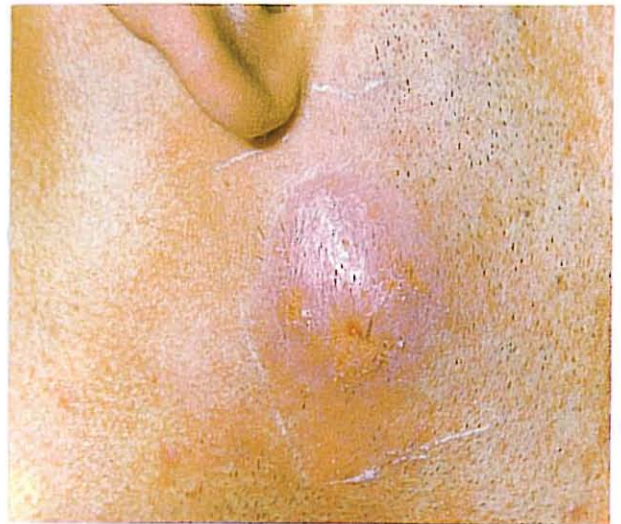

Fig. 1. Tinea barbae, severe inflammatory reaction (Kerion) produced by infection with *M. canis*.

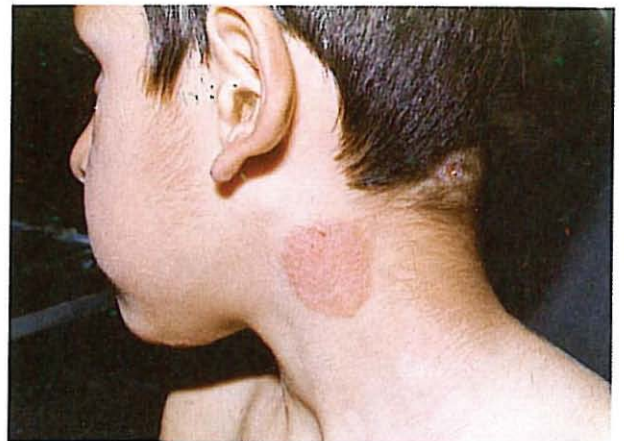

Fig. 2. Acute form of tinea corporis caused by *T. verrucosum*.

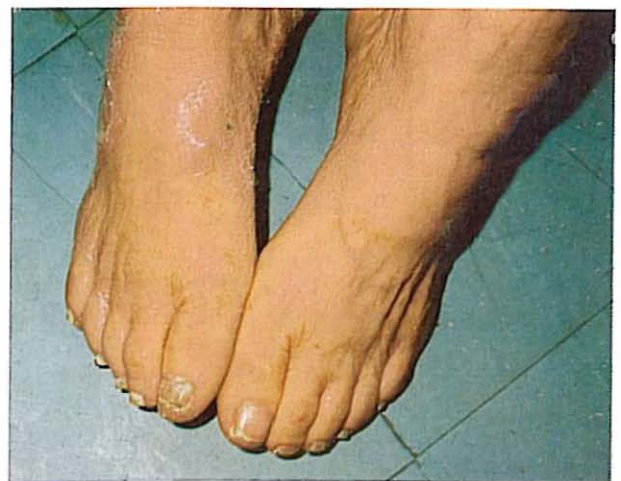

Fig. 3. Tinea unguium. The infection is chronic and of many years' duration.

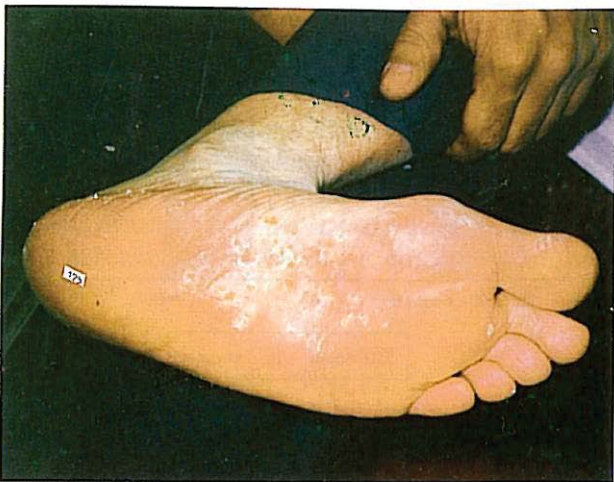

Fig. 4. Tinea pedis due to *T. rubrum*.

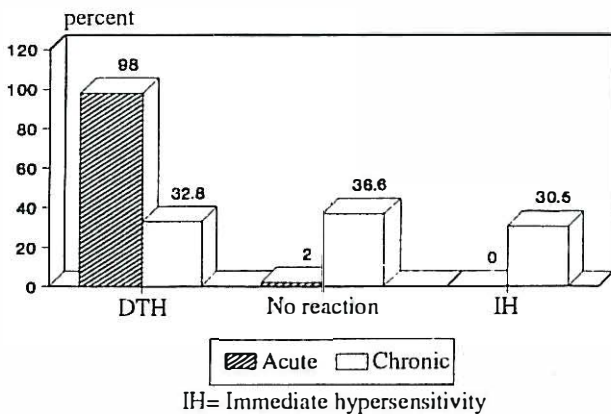


Fig. 5. Comparison of the results of skin test between patients with acute and chronic dermatophytosis.

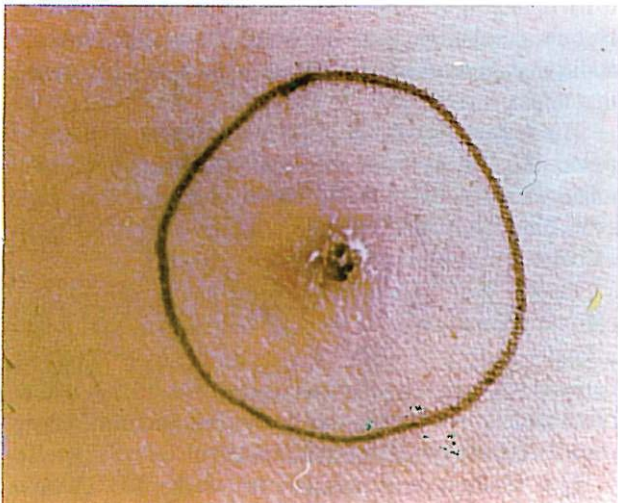


Fig. 6. Delayed-type hypersensitivity reaction, 72 hours after injection of trichophytin in a patient with acute dermatophytosis.

and the microtiter plates incubated for an additional 24 hr, and the cultures were harvested.

Harvesting was done by depositing the lymphocytes on glass fiber filters. Cells were rinsed with saline, fixed with 10% TCA and rinsed with water. Portions of filter strips corresponding to individual wells were placed in vials containing 10 mL scintillation fluid.

Vials were counted in a liquid scintillation spectrophotometer for 2 min.

Statistical Analysis

The Chi-Square test was used for the statistical analysis of the results.

RESULTS

Patients with acute dermatophytosis (group 1), did not have any background diseases, but patients with chronic dermatophytosis (group 2), had histories of other disorders: atopy, 64 patients; diabetes, seven patients; contact dermatitis, four patients; tuberculosis, three patients.

Thirteen patients of group 1 had tinea capitis, 28 had tinea corporis, and 16 had tinea barbae. Most of these patients had severe inflammatory reaction and kerion (Fig. 1,2).

34 patients of group 2 had tinea pedis and tinea unguium, 31 had tinea pedis, 29 had tinea unguium, 24 had tinea manuum, and 13 had tinea manuum and tinea pedis (Fig. 3,4).

Results of Cell-Mediated Immune Response: In Vivo Responses

Results of skin test on the acute infected patients (group 1) and chronically infected volunteers (group 2) were as follows:

Group 1: DTH reactions, 96 patients (98%); no reaction, two patients (2%) (Fig. 5,6). Fig. 7 illustrates the distribution of DTH reactions by size in this group.

Group 2: DTH reactions, 43 patients (32.8%); immediate reaction, 40 patients (30.5%); no reaction, 48 patients (36.6%) (Figs. 5,8 and Table I).

Cell-Mediated Immune Response: In Vitro Responses

Group 1: Positive lymphocyte blastogenic to trichophytin and PHA were observed in 95 (96.8%) and 98 (100%) patients, respectively (Fig. 9).

Group 2: Positive lymphocyte blastogenic stimulation to trichophytin and PHA were observed in 46 (37.4%) and 127 (94.9%) patients, respectively (Fig. 9).

DISCUSSION

Acquired immunity following dermatophyte infection

Cell-Mediated Immunity in Dermatophytosis

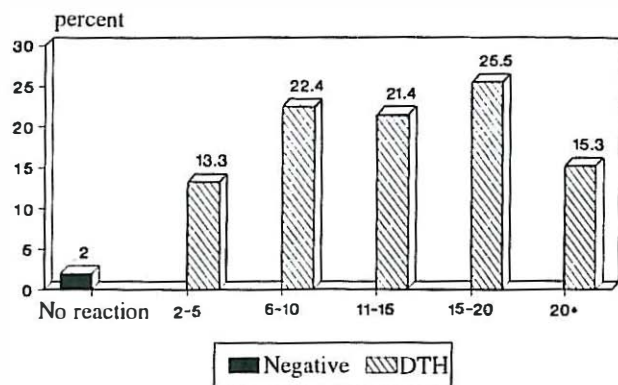


Fig. 7. Relative frequency of DTH responses by size (diameter of 72-hour reaction, mm) in 98 patients with acute dermatophytosis.

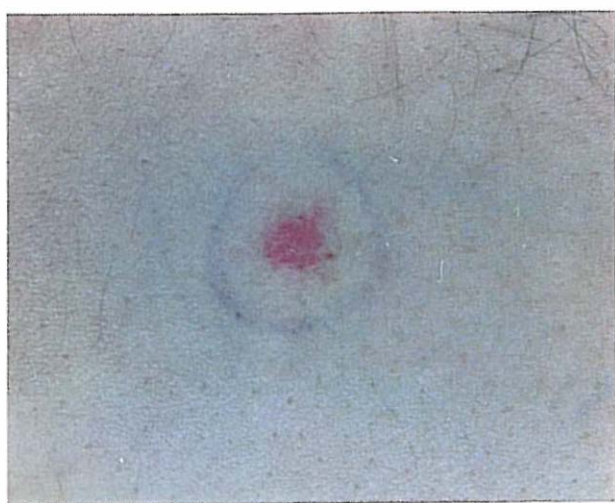

Fig. 8. Immediate hypersensitivity reaction, 20 minutes after injection of trichophytin, in a patient with chronic dermatophytosis.

has been observed in both naturally and experimentally infected man and animals.⁴⁻¹⁸ There is evidence from studies using experimental infections in animals and man that resistance to dermatophyte infection correlates with cell-mediated immunity to fungal antigens.¹⁹⁻²¹ In man, a number of *in vitro* assays of cell-mediated immunity have been carried out.¹ Lymphocyte transformation has been used to demonstrate cell-mediated immunity to dermatophyte antigens in both animals and man.^{1,7,20} Positive lymphocyte transformation responses of peripheral blood lymphocytes to trichophytin in patients with dermatophytosis have been found in several studies.²²⁻²⁶ Several studies have demonstrated that animals experimentally infected with dermatophytes generally develop delayed hypersensitivity to antigens of the infecting agent.¹ Delayed hypersensitivity response appears to be important in the development and clearance of the lesions

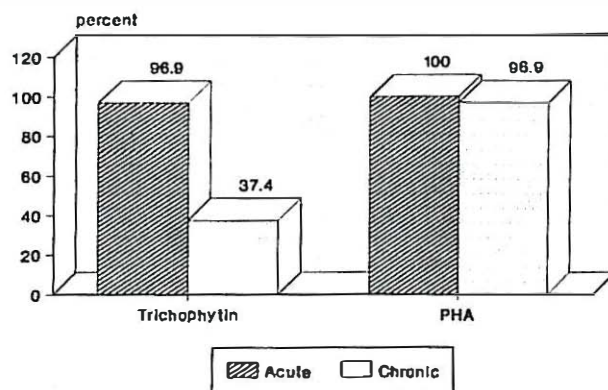


Fig. 9. Comparison of the positive results of lymphocyte transformation test (LTT) between patients with acute and chronic dermatophytosis.

Table I. Analysis of patients with chronic dermatophytosis by type of skin test responses and relation to atopy

Type of skin test responses	Numbers of patients	Numbers of patients with atopic history
Delayed type hypersensitivity	43(32.8)	7(10.9%)
Immediate hypersensitivity	40(30.5%)	36(56.3%)
Nonreactive	48(36.6%)	21(32.8%)
Total	131(100%)	64(100%)

of dermatophytosis.¹

In our study, we have found that a significantly higher proportion of positive delayed-hypersensitivity responses to trichophytin were seen in acute dermatophytosis than in chronic dermatophytosis ($P < 0.01$). This result provides additional support for previous reports which suggested that this occurred.^{11,13,23}

A number of systemic disorders, including connective tissue diseases, systemic corticosteroid therapy, chronic mucocutaneous candidiasis, diabetes mellitus, Cushing's syndrome and hematologic malignancies have been associated with chronic dermatophytosis.²⁷⁻³²

Hanfin et al.²³ found that approximately 50% of their chronic dermatophytosis patients were also atopic or had a family history of atopy. A similar history of atopy in patients with chronic dermatophytosis has been found in other studies,^{33,35} and this combination has been the "atopic chronic dermatophytosis" syndrome.³⁴

Our findings were similar; 64 of the 131 chronic dermatophytosis patients were atopic, whereas no acute dermatophytosis patient had history of atopy or any other disorder.

It seems that most patients with chronic dermatophytosis do not have generalized deficiency of the cell-mediated immunity, that is, their immunological defects are limited to responses against trichophytin.^{24,34}

This report indicates that there are differences in the results of lymphocyte transformation test with trichophytin between lymphocytes of patients with chronic and acute dermatophytosis, which are statistically significant ($p < 0.05$), whereas with PHA, these differences are not observed.

REFERENCES

- Cox RA: Immunology of the Fungal Diseases. CRC Press Inc, 1-20, 1989.
- Grappel SF, Bishop CR, Blank F: Immunology of dermatophytes and dermatophytosis. Bacteriol Rev 38(2): 222, 1974.
- Calderon RA, Hay RJ, Shennan GI: Circulating antigens and antibodies in human and mouse dermatophytosis: use of monoclonal antibody reactive to phosphorylcholine-like epitopes. J Gen Microbiol 133 (Pt 9) (12): 2699, 1987.
- Tadjebakhche H, Khosravi AR: The incidence of the precipitating antibodies in human and animals with dermatophytosis in Iran. In press.
- Kerbs S, Greenberg J, Jesrani K: Temporal correlation of lymphocyte blastogenesis, skin test responses, and erythema during dermatophyte infections. Clin Exp Immunol 27: 531, 1977.
- Cruickshank CND, Wood SR: Studies on trichophytin sensitivity. J Invest Dermatol 35: 219, 1960.
- Green F, Balish E: *Trichophyton mentagrophytes* dermatophytosis in germfree guinea pigs. J Invest Dermatol 75: 476, 1980.
- Lepper AWD: Experimental bovine *Trichophyton verrucosum* infection, the cellular responses in primary lesions of the skin resulting from surface or intradermal inoculation. Res Vet Sci 76: 287, 1974.
- Green F, Lee KW, Balish E: Chronic *T. mentagrophytes* dermatophytosis of guinea pig skin grafts on nude mice. J Invest Dermatol 79: 125, 1982.
- Jones HE, Reinhardt JH, Rinaldi MG: Model dermatophytosis in naturally infected subjects. Arch Dermatol 110: 369, 1974.
- Jones HE, Reinhardt JH, Rinaldi MG: A clinical, mycological, and immunological survey for dermatophytosis. Arch Dermatol 108: 61, 1973.
- Kaaman T: The clinical significance of cutaneous reactions to trichophytin in dermatophytosis. Acta Dermatovener 58: 139, 1978.
- Kaaman T: Cell-mediated reactivity in dermatophytosis: differences in skin responses to purified trichophytin in tinea pedis and tinea cruris. Acta Dermatovener 61: 119, 1981.
- Bloch B: Zur Lehre von den dermatomykosen. Arch Dermatol Syph 93: 157, 1908.
- Greenbaum SS: Immunity in ringworm infections. I. Active acquired immunity with a note on complement fixation tests in superficial ringworm infection. Arch Dermatol 10: 279, 1924.
- Bonk AR, Friedman L, Derbes VJ: Experimental dermatophytosis. J Invest Dermatol 39: 281, 1962.
- Jones HE, Reinhardt JH, Rinaldi MG: Acquired immunity to dermatophytes. Arch Dermatol 109: 840, 1974.
- Kligman AM: The pathogenesis of tinea capitis due to *Microsporum adouini* and *Microsporum canis*. I. Cross observations following the inoculation of humans. J Invest Dermatol 18: 231, 1952.
- Hunjan BS, Cronholm LS: An animal model for cell-mediated immune responses to dermatophytes. J Allergy Clin Immunol 63: 361, 1979.
- Kerbs S, Greenberg J, Jesrani K: Temporal correlation of lymphocyte blastogenesis, skin test responses, and erythema during dermatophyte infections. Clin Exp Immunol 27: 526, 1977.
- Calderon RA, Hay RJ: Cell-mediated immunity in experimental murine dermatophytosis. Immunology 53: 465, 1984.
- Svejgaard E, Thomsen M, Morling N, Christiansen AH: Lymphocyte transformation *in vitro* in dermatophytosis. Acta Path Microbiol Scand Sec. C, 84: 511, 1979.
- Hanifin JM, Ray LF, Lobitz WC: Immunological reactivity in dermatophytosis. Br J Dermatol 90: 1, 1974.
- Hay RJ, Shennan G: Chronic dermatophyte infections. II. Antibody and cell-mediated immuneresponses. Br J Dermatol 106: 191, 1982.
- Kaaman T, Petrini B, Wasserman S: *In vivo* and *in vitro* immune responses to trichophytin in dermatophytosis. Acta Dermatovener 59: 229, 1979.
- Stahl D, Svejgaard E: Lymphocyte transformation *in vitro* in acute dermatophytosis: a follow-up study. Avta Dermatovener 62: 289, 1982.
- Hay RJ: Chronic dermatophyte infections. I. Clinical and mycological features. Br J Dermatol 106: I, 1982.
- Mendel EH: Tinea circinata and onychomycosis (*Trichophyton purpureum*) resistance to griseofulvin during uncontrolled diabetes. Arch Dermatol 82: 1027, 1960.
- Nelson LM, McNiece KJ: Recurrent Cushing's syndrome with *Trichophyton rubrum* infection. Arch Dermatol 80: 700, 1959.
- Canizares D, Shatin H, Kellert AJ: Cushing's syndrome and dermatomycosis. Arch Dermatol 80: 705, 1959.
- Findling JW, Tyrrell JN, Aron DC, Fitzgerald PA, Young CW, Sohnle PG: Fungal infections in Cushing's syndrome (letter to the editor) Ann Intern Med 95: 392, 1981.
- Lewis GM, Hopper ME, Scott MJ: Generalized *Trichophyton rubrum* infection associated with systemic lymphoblastoma. Arch Dermatol 67: 247, 1953.
- Jones HE, Reinhardt JH, Rinaldi MG: A clinical, mycological, and immunological survey for dermatophytosis. Arch Dermatol 108: 61, 1973.
- Sorensen G, Jones HE: Immediate and delayed hypersensitivity in chronic dermatophytosis. Arch Dermatol 112: 40, 1976.
- Jones HE: The atopic-dermatophytosis syndrome. Acta Dermatovener Supple. 92: 81, 1980.