

A CASE REPORT OF COMMON VARIABLE IMMUNODEFICIENCY(CVID) WITH LEUKOCYTES ADHESION DISORDERS (LADS)

A. FARHOUDI, T. SEPEHRZAD, M. RAHMANI, F. YAZDANI, AND
S. ARSHI

*From the Department of Immunology and Allergy, The Children's Hospital Medical Center, Tehran
University of Medical Sciences, Tehran, Islamic Republic of Iran.*

ABSTRACT

A three year old boy with delayed separation of the umbilical cord, recurrent pyogenic infections and common variable immunodeficiency is presented. The immunoglobulin measurement was severely abnormal. To the best of our knowledge, the existence of leukocyte adhesion disorder together with common variable immunodeficiency (CVID) in a patient has not been reported prior to this study. *MJIRI, Vol. 7, No.1, 55-57, 1993.*

INTRODUCTION

Since 1980, several reports of leukocyte adhesion disorders (LADS) in patients suffering from recurrent infections and responding poorly to antibiotics have been published.¹ In September 1988, the first workshop for LADS, during which all kinds of surface glycoproteins were discussed, was held in Germany.³ The description of many types of common variable immunodeficiency (CVID), with early or late onset, revealed unknown or acquired causes. This paper concerns a rare and interesting case of LADS and CVID with an etiological cause due to lack of PMN glycoproteins as well.

a normal vaginal delivery and the umbilical cord was removed surgically on the 35th day of life. The vaccination history was complete with no reaction. Thalassemia minor was diagnosed at 16 months of age. There were no other problems. He is the second child of healthy, non-consanguineous parents with no familial evidence of immunodeficiency. The other sibling is healthy. Three cousins have muscular dystrophy and one uncle has seasonal allergic rhinitis and food allergy. Physical examination on admission revealed pale conjunctiva with congestion of nasal mucosa, massive nasal discharge and purulent postnasal drip.

CASE REPORT

A three year old boy with persistent nasal discharge and nightly cough was referred to our center for further investigations. The symptoms began at the age of 16 months. Despite receiving wide-spectrum antibiotics for long periods, the symptoms persisted. He was admitted to the hospital because of pneumonia, which later led to recurrent episodes of upper respiratory infections. Following the suggestion of an otolaryngologist; adenoidectomy was performed. Diagnosis of a serous otitis media led to an audiometry with normal results. The child was the result of

MATERIAL AND METHODS

Three classes of immunoglobulins were measured by RID (Manciani method). IgE was measured by ELISA. T-cells(s) and B-cell(s) counts were obtained using rosette formation and immunofluorescence (SMIg), respectively. Boyden chamber was used to evaluate neutrophil mobility (chemotaxis). Neutrophil phagocytosis and opsonization were studied by Luminol (chemiluminescence) (LKB). To recognize membrane glycoproteins, APAAP method was performed by alpha and beta monoclonal antibody as follows (Figs. 1-3).

Alkaline phosphatase anti-alkaline phosphatase

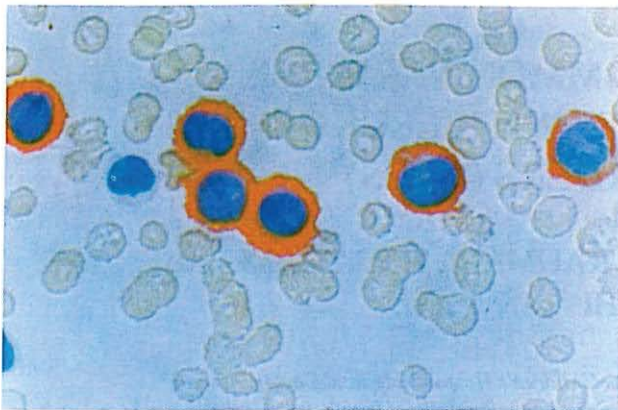


Fig. 1. Normal peripheral blood film by APAAP method.

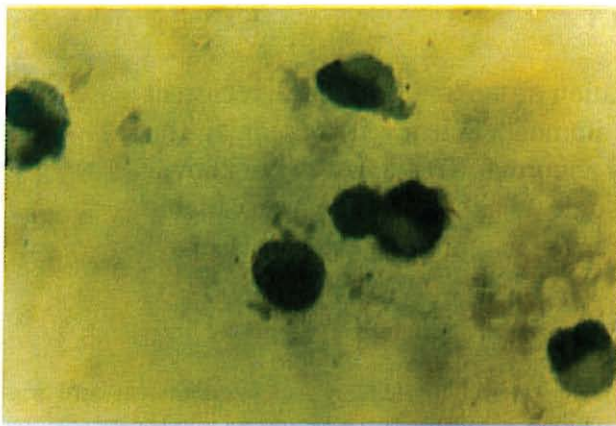


Fig. 2. Defective PBF by APAAP method.

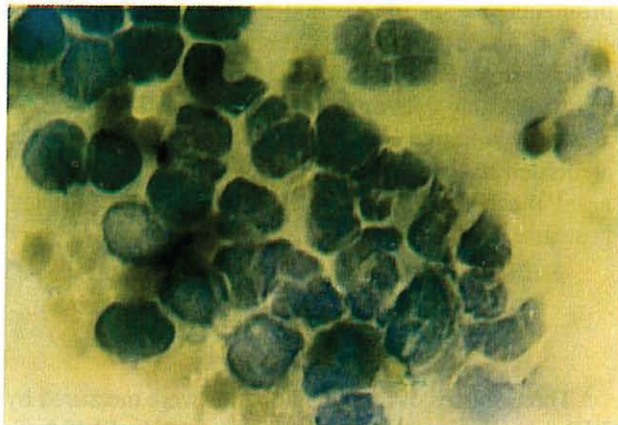


Fig 3. LFA₁(α) deficiency by APAAP method.

(APAAP) staining procedure:

1. The whole blood was mixed with an equal volume of dextran solution.
2. The white cell-rich supernatant was centrifuged.
3. Smears from the white cells were then prepared.
4. The latter was consequently air dried for 2-18 hours.

Fixation took place in acetone; methanol or acetone; methanol: formaline for 90 seconds.

For staining a suitably diluted DAKO, primary mouse monoclonal was added in a moist chamber at room temperature for 30 minutes. The antibody was then lapped off and the slide was placed in TBS for five minutes.

APAAP complex was consequently added and incubated in a moist chamber at room temperature. The slides were placed in TBS for five minutes after tapping the APAAP off. This was followed by the addition of alkaline phosphatase substrate and incubated at room temperature for 10-20 minutes. It was finally washed in TBS followed by water. Cell smears were counter stained with haematoxylin and mounted in an aqueous mounting medium.

RESULTS

Routine blood tests revealed mild anemia (Hb= 11.7g/dL, Hct= 35.5, MCV=21.3) and a normal white blood cell count of 11,600/mm³. Lymphocytes and neutrophil count were normal, but there was mild eosinophilia (812/mm³). IgG and IgA were found to be absent (RID), and IgM was also found to be low at 30 mg/dL. IgE was 27 IU/dL (ELISA). T- cells by rosette formation were normal. B-cell were also normal by immunofluorescence. Isohemagglutinin titer was negative. Anti-rubella, measles and polio (I,II,III) antibodies were not detectable. Complements (C3,C4,CH50) were found to be normal. Neutrophil mobility by Boyden chamber was defective.

Neutrophil phagocytosis and opsonization were studied by Luminol (chemiluminescence). The patient's PMN were added to P.M.A. and the luminol showed low normal chemiluminescence activity.

The patient's serum was added to Baker's yeast, normal PMNs and luminol. It had no luminescence and was found to be defective in comparison with control. Chest X-ray

Table I. Immunologic evaluation

	Patient	Control
IgG	ABSENT	—
IgA	ABSENT	—
IgM	33 mg/dL	—
IgE	27 IU/mL	—
B-CELL	20%	25%
T-CELL	55%	65%
ASOT	ABSENT	—
Isohemagglutinins titer	ABSENT	—
anti-rubella	IgM 1/10 (ELISA)	—
anti-measles	IgG 1/8	—
anti-polio I, II,III	IgG ABSENT	—
Complements	normal	—

Table II. Neutrophil function.

	Patient	Control
Chemotaxis		
-CF	15	25
-CF	50	110
Chemiluminescence		
With PMA:	Low normal	normal
With Baker yeast:	Completely deficient	"

Table III.

Skin tests for hypersensitivity response after 72 hrs

Candida	Negative
PPD	Negative
Shick test	20 X 20 mm erythema
SK-SD	Negative

showed pneumonia and radiograph of sinuses revealed sinusitis. APAAP method performed by alpha and beta monoclonal antibody indicated the absence of surface "MGP" or integrins: LFA1, MAC1, P150.95 (CD11, CD18).⁵ His neutrophils and T cells lacked surface MGP. The results are presented in the Tables, and Figs. 1-3.

Following diagnosis of LAD and CVID, the child was placed on intravenous immunoglobulins and antibiotics as prophylaxis. His HLA-typing is compatible with his brother and will undergo bone marrow transplantation as a last resort.¹

DISCUSSION

Recurrent pyogenic infections, severe deficiency of immunoglobulins and the existence of normal B-cells would lead to the diagnosis of CVID.

Delayed separation of the umbilical cord on the other

hand, in conjunction with recurrent pyogenic infections, chemotactic defect and lack of surface MGP, indicate LAD.^{2,7} CVID and LAD have up to now been dealt with as two distinct and unrelated diseases.⁴

The occurrence of both CVID and LAD in this patient could suggest the existence of a common defect in the shape of surface MGP (integrins).^{2,8}

The lack of surface MGP will cause a neutrophil chemotactic defect resulting in LADs. This insufficiency will also render the production of immunoglobulins by B-cells through detection of cell-to-cell interaction unhelpful.^{6,9}

The particular importance of this report is that it points to the lack of M.G.P. as the fundamental cause of chemotactic defect.⁷

This has also adversely affected the production of gammaglobulins in the patient.⁹

REFERENCES

1. fischer A, Griscelli, C, Blanch S: The leukocyte adhesion deficit. *Lancet*, (ii) 473 Vol, No 1058-1061, 1986.
2. Hogg N: The Leukocyte Integrins. *Immunology Today*, 10(4): 111-114, 1989.
3. Meeting on structure and function of molecules involved in leukocyte adhesion. West Germany, 28, Sept, 1988.
4. Farhoudi A, Eslami MB: Immunodeficiency, Diagnosis and Treatment. Elmipub, Tehran, p 120-135, 1988.
5. Carl G, et al: The mode of action of LFA-1. *Immunology Today* 11(8): 277-80, 1990.
6. Damsky CH, Bernfield M: Cell-to-cell contact and extracellular matrix. *Current Biology* 2(5): 813-14, 1990.
7. Zetter BR, Brightman: Cell motility. *Current Opinion Cell Biology* 2(5): 850-56, 1990.
8. Rourke AM, Mescher MF: T-cell receptor-activated adhesion system. *Current Opinion Cell Biology* 2(5): 888-93, 1990.
9. Noelle RJ, Snow EC: Cognate interactions between helper T-cells and B-cells, *Imm. Today* 11(10): 361-8, 1990.