

## Original Articles

### SUPRAVALVAR AORTIC STENOSIS IN CHILDREN REPORT OF THIRTEEN CASES

SHAHLA ROODPEYMA, M.D. AND AKBAR SHAHMOHAMMADI, M.D.

*From the Department of Pediatrics, Shahid Rajai Heart Hospital, Iran University of Medical Sciences, Tehran, Islamic Republic of Iran.*



#### ABSTRACT

During 15 years from 1975 to 1990, thirteen cases of supravulvar aortic stenosis were admitted at the pediatrics department of Shahid Rajai Heart Hospital, Tehran. All patients were subjected to cardiac catheterization and a angiocardiography. Patients ranged in age from 3.5 years to 14 years with a mean of 8.7 years.

Seventy seven percent of children were male. Eight cases (61.5%) had Williams' syndrome. Hourglass type of supravulvar aortic stenosis was the most common variant (70%), followed by hypoplastic type (15%) and membranous type (5%). Peripheral pulmonary stenosis was the most common associated anomaly and was observed in 23% of patients.

The main purpose of this investigation is to report the results of the study on supravulvar aortic stenosis and its association with Williams' syndrome in a group of Iranian children.

*MJIRI, Vol. 6, No. 4, 241-244, 1993.*

#### INTRODUCTION

Supravulvar aortic stenosis (SVAS) is a congenital narrowing of the ascending aorta that may be localized or diffuse, originating at the superior margin of the sinuses of valsalva just above the level of the coronary arteries.

The clinical picture of supravulvar aortic stenosis may differ in major respects from that observed in the other forms of obstruction of the left ventricular outflow tract. The most important difference is the occasional association of transient idiopathic infantile hypercalcemia, a disease probably related to deranged vitamin D metabolism.<sup>6</sup>

The designation of supravulvar aortic stenosis syndrome or Williams' syndrome has been applied to the distinctive picture produced by coexistence of the cardiac and multiple system disorder.

Other manifestations of this syndrome include mental retardation, "elfin facies" (high prominent forehead, epicanthal folds, underdeveloped bridge of

the nose and mandible overhanging upper lip), narrowing of peripheral systemic and pulmonary arteries, inguinal hernia, strabismus, and abnormalities of dental development. Occasionally there is moderate thickening of the aortic cusps, and valvar pulmonary stenosis may occur in association with the narrowing of peripheral pulmonary arteries.<sup>6</sup> Rarely patients have mitral valve abnormalities.

The exact prevalence of Williams' syndrome is unknown. More than 100 individuals with the syndrome are known to the Williams' Syndrome Association in the United States. The majority of these persons are younger than 20 years of age.<sup>7</sup>

This article reviews the clinical manifestations and the results of catheterization and angiocardiography in group of children suffering from SVAS in order to determine the association rate of SVAS with Williams' syndrome, the prevalence of different pathological types of SVAS and its combination with other cardiovascular anomalies.

## Supravalvar Aortic Stenosis in Children

### MATERIALS AND METHODS

During a period of 21 years between 1975 thirteen children with supravalvar aortic stenosis were admitted at the pediatric department of Shahid Rajai Heart Hospital. The patients' medical records were studied retrospectively.

All the patients were subjected to cardiac catheterization and angiocardiology. Left ventricular, supravalvar area, and aortic arch pressures were recorded. Diagnosis was confirmed by the demonstration of a pressure gradient just above the aortic valve, and a constriction at this level by aortography.

The angiocardiology permitted visualization of narrowed segments of the aorta distal to the obstruction (Figures 1,2). At right heart catheterization, the presence of stenosis of pulmonary valve or peripheral pulmonary arteries was detected by continually recording pressure as the catheter was withdrawn from a peripheral pulmonary artery to the cavity of the right ventricle and by right ventricular angiocardiology.

### RESULTS

The results of study have been summarized and presented in Table I. The youngest and the oldest members of the group were 3.5 and 14 years old respectively, while the average age of the population was 8.7 years. Ten patients were male and three were female, with males comprising 77 percent of the population.

The patients had a history of syncopal attack and faint and in two cases a history of dyspnea and fatigability during exercise had been observed. On physical examination all the patients had an ejection systolic murmur of grade equal to or greater than IV/VI at right upper sternal border accompanied by systolic thrill at suprasternal notch area and carotid arteries.

In three patients (cases 5, 12 and 13) the right arm systolic pressure was greater than that of the left arm with a difference of 10 to 15 mm Hg pressure gradient between the two arms.

Eight of the cases were mentally retarded and had the characteristic facies of the Williams' syndrome and all eight were male (Fig 3).

Chest X-rays revealed mild cardiomegaly in three patients while the remaining ten patients had normal cardiac size. Electrocardiographic tracing of all patients showed left ventricular hypertrophy (LVH).

Cardiac catheterization revealed marked left ventricular aortic pressure gradient which ranged from 164 to 50 mm Hg (median 94.2 mm Hg). Retrograde

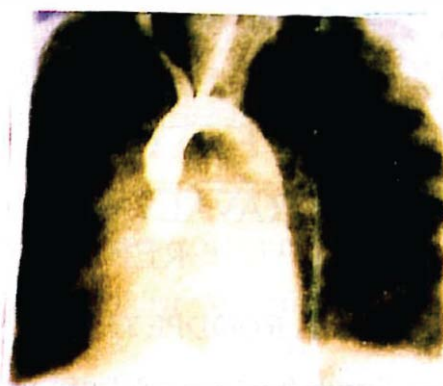

Fig 1: Aortogram in a patient with supravalvular aortic stenosis SVAS showing dilated sinuses of Valsalva and an aortic constriction just above the sinuses.

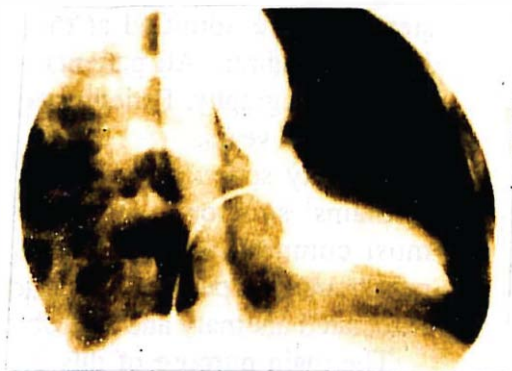


Fig 2: Angiocardiogram in a patient with hourglass type SVAS.

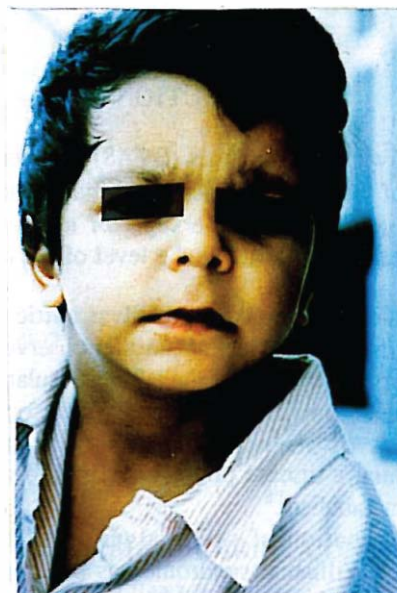

Fig 3: Facial appearance in a patient with Williams syndrome. Note the high prominent forehead, epicanthal folds, and overhanging upper lip.



Table I. Summary of results of study

Case	sex/age year	Facies and intelligence	LV-AO PG(mm Hg)	Angiocardiography
1	M/6	normal	75	Hypoplastic type SVAS-pulmonary valve stenosis-peripheral pulmonary stenosis.
2	F/13	normal	164	Hourglass type SVAS -peripheral pulmonary stenosis.
3	M/10	Elfin Facies-Mentally retarded	130	Hourglass type SVAS
4	F/4.5	normal	60	Hourglass type SVAS
5	F/14	normal	80	Hourglass type SVAS - valvar aortic stenosis.
6	M/6	Elfin Facies-Mentally retarded	50	Hourglass type SVAS
7	M/6	Elfin Facies-Mentally retarded	104	Hypoplastic type SVAS -peripheral pulmonary stenosis.
8	M/6	Elfin Facies-Mentally retarded	100	Membranous type SVAS -valvar aortic stenosis.
9	M/9	normal	90	Hourglass type SVAS -subvalvar aortic stenosis.
10	M/3.5	Elfin Facies-Mentally retarded	90	Discret membranous type SVAS
11	M/4	Elfin Facies-Mentally retarded	75	Hourglass type SVAS
12	M/8	Elfin Facies-Mentally retarded	80	Hourglass type SVAS
13	M/11	Elfin Facies-Mentally retarded	55	Hourglass type SVAS

LV= Left ventricle, AO=aorta, PG=Pressure gradient, SVAS= supravalvar aortic stenosis.

aortogram showed hourglass-type SVAS in nine cases, hypoplastic type in two and membranous type in two other cases.

Angiocardiography indentified peripheral pulmonary stenosis in three, valvar pulmonary stenosis in one, valvar aortic stenosis in two and subvalvar aortic stenosis in one case. Eight patients have been operated upon. In one out of eight (case 1) who had a long segment atretic ascending aorta and pulmonary valve and peripheral stenoses, operation did not progress successfully due to technical difficulties. This patient later experienced post-pericardiotomy syndrome as a complication of the operations. In one of the eight cases, aortic valve was replaced in addition to repair of hourglass type SVAS. Cases 2 and 5 who had the most severe form of stenosis underwent post-operative cardiac catheterization one month after surgery. Their LV-AO pressure gradients had dropped dramatically and reached 40 and 30 mm Hg respectively. Six patients were lost to follow up. Seven others have a regular follow up ranging from four to eight years. Case no. 10 developed moderate aortic stenosis five years after surgical repair of SVAS. Six other patients have satisfactory clinical conditions.

## DISCUSSION

Supravalvular aortic stenosis (SVAS) may occur as an isolated autosomal dominant trait or as a feature of Williams' syndrome (WS). It has been suggested that a defect in calcitonin function may play a role in Williams' syndrome.<sup>2</sup> Some authors consider WS to be due to more severe expression of the gene defect that causes isolated SVAS. Although some believe that

autosomal dominant SVAS is part of the spectrum of WS, others believe that these are separate entities. Ensing, et al<sup>4</sup> demonstrated complete penetrance with extremely variable expression in a family with autosomal dominant SVAS. In our patients familial histories were incomplete for reaching a conclusion.

Friedman<sup>6</sup> suggested that in contrast to the other forms of aortic stenosis, there appears to be no sex predilection in SVAS. As it is apparent in this study SVAS is more common in males than females. Male preponderance in this study was more prominent in the patients with WS (8/8) than in those with SVAS (10/13).

When supravalvular aortic stenosis is present, the systolic and mean blood pressures may be higher in the right arm than in the left arm or three other extremities. This phenomenon has been attributed to the tendency of the aortic jet stream to adhere to the wall of the ascending aorta (coanda effect) with selective streaming of blood into the innominate artery. In our study coanda effect was observed in three (23%) patients.

Frequency of WS in patients with SVAS in our series was 61.5%, higher than that reported (50%) by other investigators.<sup>9</sup> Pagon, et al<sup>10</sup> evaluated nine children with Williams' syndrome for physical, neurodevelopmental and behavioral characteristics to record the natural history of this disorder. The study subjects ranged in age from 10 to 20 years. All but one child had evidence of SVAS on echocardiography. In our study all eight patients with WS had evidence of SVAS on angiocardiography. Morris, et al<sup>8</sup> evaluated 13 adult patients with WS. Adults in their study had progressive multisystem medical problems. Cardiovascular complications were common (12/13) including hypertension (8), SVAS (9), aortic hypoplasia

(3), pulmonic artery stenosis (4), peripheral stenoses (3), and mitral valve prolapse (2). In our survey cardiovascular complications in WS patients were as follows: SVAS (8), peripheral pulmonary stenosis (1), valvar aortic stenosis (1), and the associated cardiovascular anomalies in the whole group with SVAS were as follows: peripheral pulmonary stenosis (3), pulmonary valve stenosis (1), valvar aortic stenosis (2), subvalvar aortic stenosis (1).

Supravalvar aortic stenosis may be separated into three categories, although some patients may have findings of more than one type. Most common is the hourglass type, in which there is a constricting annular ridge at the superior margin of the sinuses of valsalva. The membranous type is produced by a fibrous or fibromuscular semicircular diaphragm. The hypoplastic type is characterized by uniform hypoplasia of the ascending aorta. O'Conner, et al<sup>9</sup> reported SVAS in six patients aged 1.5 to 12 years. Three patients (50%) had WS. In two other patients, the stenosis was familial. The angiographic/anatomic subtype of deformity was hourglass in four patients, diffuse in one, and membranous in one. Aoyagi, et al<sup>1</sup> reported five surgically-treated cases of SVAS. Preoperative cardiac catheterization revealed left ventricular-aortic pressure gradient ranged from 20 to 180 mm Hg (median 80.2 mm Hg), and retrograde aortogram showed localized (hourglass type) SVAS in all cases. In our study, the three types of SVAS in order of frequency were hourglass (9), hypoplastic (2), and membranous (2), in agreement with those reported by other workers. In our report, eight patients have been operated upon. In one of them, operation was not successful. In seven others, the stenosis was relieved by aortoplasty in addition to aortic valve replacement in a 14 year old female. Six patients were lost to follow up. Seven others, including two postoperative cases, are in good clinical condition at a mean follow up of six years.

Wren, et al<sup>11</sup> suggested that SVAS is usually a progressive lesion, with an increase in left ventricular outflow tract pressure gradient related to poor growth of the ascending aorta. Pulmonary artery stenosis usually improves and only rarely limits prognosis. It seems likely that the aorta and the pulmonary arteries manifest different pathologic responses to common genetic or metabolic abnormality.<sup>5</sup> The association of Williams' syndrome with a wide range of peripheral vascular

anomalies, including stenosis and hypoplasia of systemic and pulmonary arteries has been reported. The spectrum of abnormalities include renal artery stenosis, long segment narrowing of the aorta, coronary arteries narrowing and myocardial infarction, discrete coarctation of the aorta and systemic hypertension, all of which may occur alone or together and appear gradually.<sup>3</sup> One of our patients developed valvar aortic stenosis during the course of his illness.

## REFERENCES

1. Aoyagi S, Kosuga K, Lanaka K, Ando F, Hara H, Oishi K: Surgical treatment of supravalvular aortic stenosis. *Kyobu-Geka* 43: 404-7, 1990.
2. Bennett CP, Bum J, Moore GE, Chambers J, Williamson R, Wilkinson J: Exclusion of calcitonin as a candidate gene for the basic defect in a family with autosomal dominant supravalvular aortic stenosis. *J Med Genet* 25: 311-2, 1988.
3. Daniels S, Loggie J, Schwartz D, Strife J, Kaplan S: Systemic hypertension secondary to peripheral vascular anomalies in patients with Williams' syndrome. *Journal of Pediatrics* 106: 249-151, 1985.
4. Ensing GJ, Schmidt MA, Hagler DJ, Michels VV, Carter GA, Feldt RH: Spectrum of findings in a family with nonsyndromic autosomal dominant supravalvular aortic stenosis: a Doppler echocardiographic study. *J Am Coll Cardiol* 13: 413-9, 1989.
5. French J: Aortic and pulmonary artery stenosis: improvement without intervention: *JACC* 15: 1631, 1990.
6. Friedman W: Aortic Stenosis. In: Adams FH, Emmanouilides GC, (eds). *Moss Heart Disease in Infants, Children and Adolescents*. Baltimore; Williams and Wilkins, 236-40, 1989.
7. Greenberg I: Williams' Syndrome. *Pediatrics* 84: 922-3, 1989.
8. Morris CA, Leonard CO, Dilts C, Demsey SA: Adults with Williams' syndrome. *Am J Med Genet Suppl* 6: 102-7, 1990.
9. O'Connor WN, Davis JB JR, Geissler R, Cottrill CM, Noonan JA, Iodd EP: Supravalvular aortic stenosis, Clinical and pathologic observations in six patients. *Arch Pathol Lab Med* 109: 179-85, 1985.
10. Pagon RA, Bennett FC, Laveck B, Stewart KB, Johnson J: Williams' syndrome. Features in late childhood and adolescence. *Pediatrics* 80: 85-91, 1987.
11. Wren C, Oslizlok P, Bull: Natural history of supravalvular aortic stenosis and pulmonary artery stenosis. *J Am Coll Cardiol* 15: 1625-30, 1990.