

## DISTANT INFECTIONS CAUSED BY THROMBOPHLEBITIC COMPLICATIONS OF CHOLESTEATOMA

N. MOKHTARI, M.D., AND M. NAGHIBZADEH, M.D.

*From the Department of Otolaryngology, Ghaem Medical Center, Mashad University of Medical  
Sciences, Mashad, Islamic Republic of Iran.*

### ABSTRACT

The report of two cases of chest and kidney infections reminds of the possibility of distant infections caused by thrombophlebitic complications of cholesteatoma.

Deep neck infection, mediastinitis, pleural empyema, pulmonary abscesses and hematogenic microabscesses of kidney have been proved by clinical, radiologic and laboratory examinations in two cholesteatoma patients. The clinical course of distant infections could be terminated by effective surgical elimination of contaminated thrombi from sigmoid sinus during a mastoid surgery.

*MJIRI, Vol. 6, No. 4, 299-301, 1993.*

### INTRODUCTION

Cholesteatoma is still a major concept in the otolaryngology texts and the everyday ENT practice. The availability of antibiotics and modern otologic surgical skills have reduced the incidence of the cholesteatomas' major complications.<sup>2,3,5</sup> Today's physicians may remember few of the complications of cholesteatoma. If an unusual complication is developed, its diagnosis is difficult to make. To know the cholesteatoma as a factor is even more difficult. The senior author has reported sixteen cases of sigmoid sinus involvement,<sup>4</sup> pointing to the effective method of treatment after a due suspicion to make early and intraoperative diagnosis. The recent medical literature is lacking the significance of these clinical entities. The result of this ignorance is to drop the cholesteatoma and thrombophlebitis from the list of differential diagnosis. Teichgraeber and Sneed<sup>4,6</sup> have reported their cases and the report of 23% mortality rate from thrombophlebitis within the lateral sinus, is an alarming point. Our previous cases not producing mortality, have increased the patient hospitalization days<sup>4</sup> and expenses. The

multidisciplinary approach and our aggressive method of treatment could save the lives of patients suffering this highly morbidious problem.

This presentation is to report the significance of cholesteatoma and its complications to our medical profession and the other medical specialties. Practicing physicians in the fields of infectious diseases, pediatricians, internists and every one who is involved with an unknown hematogenous infection has to be aware of thrombophlebitic involvement in the course of bone-eroding cholesteatoma of middle ear and mastoid.

### REPORT OF CASES

The report of two cases is the basis for this presentation. The far distant infectious problems that are diagnosed in these two patients brings us back to our original profession as a physician to treat the patient, not the disease. We may dare to replace the sentence "Pus somewhere, pus nowhere, pus under the diaphragm" with our sentence, "pus somewhere, pus nowhere, pus within the sigmoid sinus."

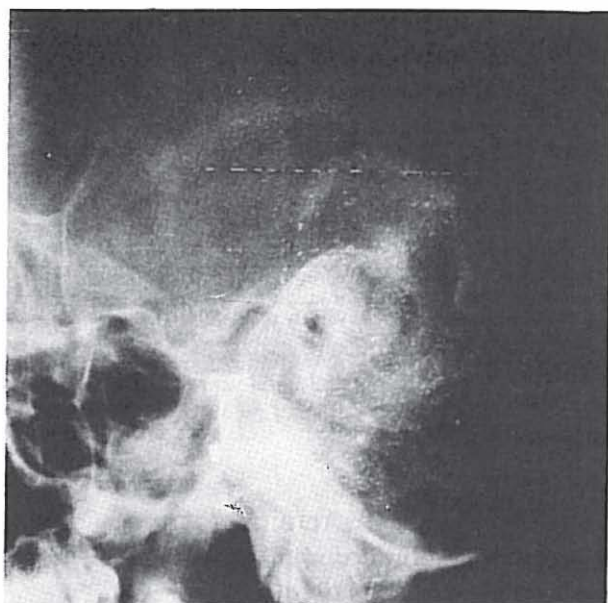

Fig. 1. Mastoid x-ray from case 1.

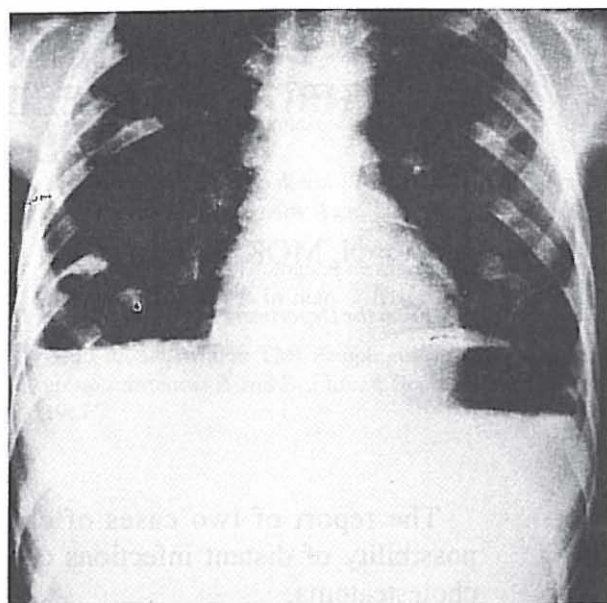


Fig. 2. Chest film in case 1.

#### CASE 1

A 9-year-old boy from a low socioeconomic class presented to the ENT department of Ghaem Medical Center in Mashhad, with an outpatient diagnosis of deep neck infection. His opening clinical scene with high fever, malaise and tenderness over his left side of neck made us to incise and drain the neck via a left lateral cervical oblique incision. The diagnosis of cholesteatoma in his left mastoid was made by otoscopy and x-ray examination (Figure 1). While waiting for his condition to improve for doing a mastoidectomy, a night report suggested an acute mediastinitis. The child had severe sweating and shortness of breath. A chest film (Figure 2) made the diagnosis of pleural effusion and/or empyema. The patient being on his original antibiotic coverage, underwent a right chest tube insertion, draining pus. The same bacteria that were previously cultured from the neck-streptococci-were obtained.

During his postoperative days after his chest tube insertion, he noticed pain in the region of his kidney. Urinalysis showed proteinuria and hematuria. He did lose several pounds of weight. Antibiotic coverage with penicillin and chloramphenicol continued until chest cleared up. He underwent a left mastoidectomy after we noticed a complete air-bone gap of 60 dB in his hearing work up and an obstructed lateral sinus confirmed with the Toby-Ayer test. His canal-wall down mastoidectomy revealed the destruction of sinus plate. The sigmoid sinus opened-up in a longitudinal direction and the infected thrombus was evacuated from the sinus until free blood was noticed and bleeding controlled.

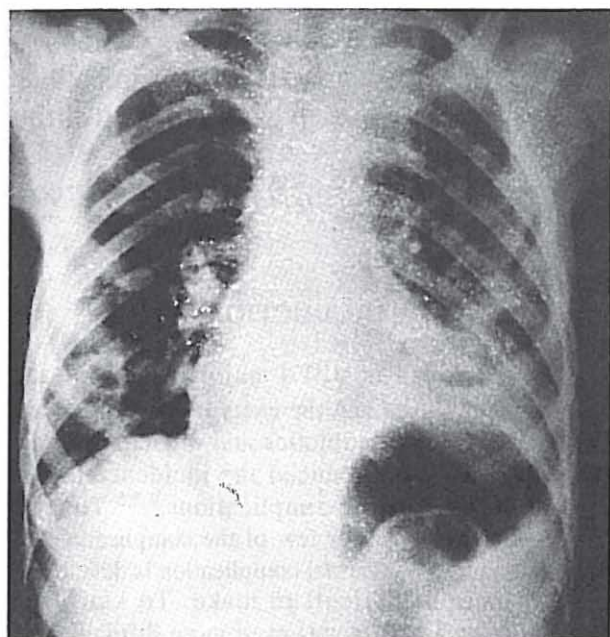


Fig. 3. Chest film in case 2 with multiple pulmonary abscesses.

This patient's final discharge note presents a healthy child being in good condition without any neural deficit. A clear chest and normal urinalysis with open mastoid cavity was the result of multi-disciplinary treatment.

#### CASE 2

A 19-year-old male was transferred to our ENT ward from Department of Pulmonary Medicine after he had been admitted and treated for multiple pulmonary abscesses. Otorrhea and tenderness over mastoid was

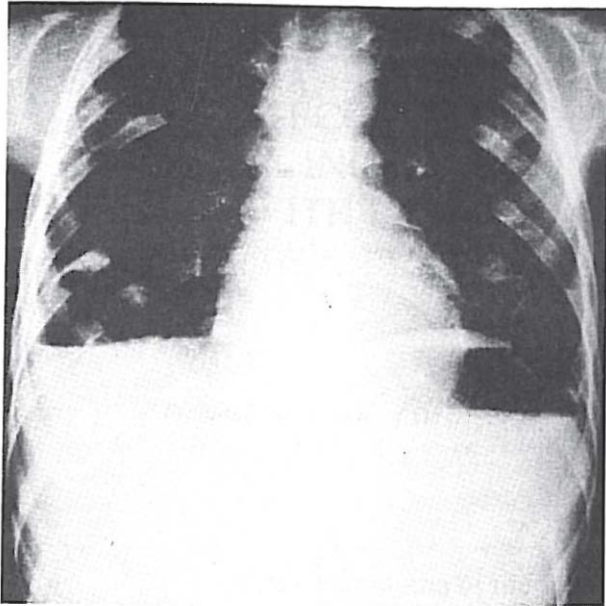


Fig. 4. Chest film in case 2 at the time of discharge.

noticed by the internist. He was on antibiotic regimen and postural drainage with some degrees of improvement, when we decided to start our otologic work-up and intervention. A conductive hearing loss and an eroded sinus plate in standard mastoid films, in a patient with the distant pulmonary infection and mastoid abscess prompted the evacuation of mastoid from the cholesteatoma (Fig. 3,4). During a canal wall down mastoidectomy the sub-periosteal mastoid abscess was drained. The sinus plate was missing and replaced by periphlebitic abscess and granulation tissues. After eradication of the diseased tissues the sigmoid sinus was incised in longitudinal direction and the thrombus evacuated from sinus to let free blood flow. The bleeding was controlled with an antibiotic impregnated pack. This patient was also discharged from the hospital in good condition. His chest film at the time of discharge is shown in Fig. 5.

## DISCUSSION

Distant infections within the parenchyma of any organ will occur whenever the septic emboli enters the blood stream from a vein involved with infectious process. This is a well known process being discussed in pathology texts. Physicians may forget that the same process may happen in the body of their patient who is under their treatment for a localized disease. This is especially true when the localized infection is close to a large vein. We are all familiar with thrombophlebitis of the lower extremities in trauma and gynecology patients. In head and neck, the internal jugular vein and the large intracranial sinuses are also venous structures that can be involved when they are in close proximity of an infectious process.

The present article may promote the alertness of physicians to the aforementioned pathologic process. The proximity of the sigmoid sinus to the infected mastoid air cells makes it quite possible. Thrombophlebitis of the sigmoid sinus while a complication belonging to the historical medicine, is still being reported as sporadic cases. If the sigmoid sinus can be involved with infection, its septic emboli can reach every organ receiving the infected blood.

## REFERENCES

1. Ludman H: Complications of suppurative otitis media. In: Scott-Brown Textbook of Otolaryngology, 5th. edition, pp. 270-275, London Butterworths, Co. 1987.
2. Goycoolea M V: Complications of suppurative otitis media. In: Paparella, Textbook of Otolaryngology. 3rd edition, Philadelphia, W.B.Saunders Co, 1991.
3. Glasscock M.E: Intracranial complications of otitis media.. In: Surgery of the Ear, 5th edition, Philadelphia, W.B.Saunders Co, pp. 259-267, 1990.
4. Mokhtari N A: Sigmoid sinus involvement in chronic middle ear infections. *Laryngoscope* 98(3): 310-2, 1988.
5. Teichgraeber F, et al: Lateral sinus thrombosis, a modern prospective. *Laryngoscope* 744, 1982.
6. Sneed W F: Lateral sinus thrombosis. *Am J Otol* 258, 1983.