

IMMUNODIAGNOSTIC TESTS IN HYDATIDOSIS OF THE LUNG

J. TAVAKOLI, Z. HAGHI, AND S. ZEHTABCHI

From the Departments of Immunology and Thoracic Surgery, Ghaem Hospital, Mashhad University of Medical Sciences, Mashhad, Islamic Republic of Iran.

ABSTRACT

Laboratory diagnostic tests are useful in diagnosis of hydatidosis of the lung. In this study, we compare the diagnostic values of these immunodiagnostic tests with the clinical evidence of hydatid disease. Application of these tests, especially indirect hemagglutination and bentonite flocculation, is shown to be very useful in diagnosis of the disease, of course in combination with clinical findings.

MJIRI, Vol. 6, No. 2, 101-103, 1992

INTRODUCTION

Hydatid disease of the lung is considered to be one of the most common diseases in Iran. The majority of patients with hydatid cyst are from the rural and poor population. Clinical diagnosis is based upon the presence of a slowly growing cystic tumor, history of residence in an endemic area, and close association with dogs. Various types of scanning procedures of the lung usually detect an uncalcified cyst.

Laboratory diagnostic tests, of which there are many, are useful in diagnosis. The aim of this study which was done in the Ghaem Medical Center at Mashhad University of Medical Sciences was to compare the diagnostic values of these immunodiagnostic tests with the clinical evidence of hydatid disease of the lung.

MATERIALS AND METHODS

A total of 30 hospitalized patients with clinical and radiological evidence of hydatid disease of the lung were collected. These patients were diagnosed as hydatidosis of the lung by both a surgeon and a pathologist. The patients consisted of 19 males (63%), aged four-50 years. Chest x-ray was done for all of the patients and other imaging procedures like tomography, liver and spleen scanning and C. T. scan was done for some of the patients to find probable cysts in other parts of the body.

Hematological assays consisted of CBC and ESR. All patients underwent the IHA (indirect hemagglutination), BF (bentonite flocculation test) and Casoni's skin test. Total serum IgE was measured for all of the patients.

Casoni's test: In this test, 0.1 cc of ecchinococcal antigen (Behring) is injected intradermally with a tuberculin syringe. The reaction is evaluated after 15 minutes (fast reaction) and also after 24 hours (late reaction). Criterias for interpretation of reactions consist of erythema, edema, and diameter of induration. For positive results, an induration greater than 5mm diameter is needed. The reaction which is seen after 24 hours usually is an erythematous indurated area that occasionally spreads to all of the forearm and may persist for several days.

Indirect hemagglutination test: This test is performed as a qualitative (screen) and quantitative (Behring) test. For screening, 5ml of the patient's serum is mixed

Table I. Clinical manifestations in patients with hydatid cyst of lung

Signs	Percent
Cough	83
Sputum	72
Dyspnea	66
Chest pain	62
Fever	60
Hemoptysis	43
Chills	23
Salty-tasting sputum	20
Foamy sputum	16
Vomiting	13

Immunodiagnosis in Hydatidosis of the Lung

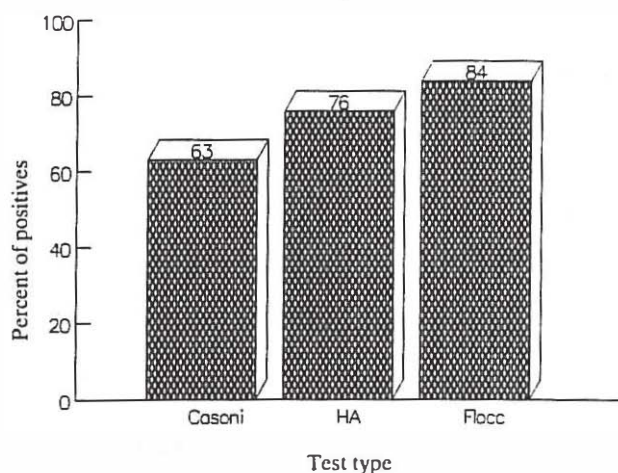


Fig. 1. Comparison of various immunodiagnostic tests.

with 100 ml of IHA reagent (stabilized sheep erythrocytes sensitised with soluble, purified antigen). Results were read as positive (complete agglutination of cells) or negative (sedimentation of cells). All positive cases were followed by a quantitative test, in which the patient's serum was diluted up to 1:512.

Bentonite flocculation test: A small amount of antigen-coated Bentonite particles was added to 0.1 ml samples of diluted serum (1:5, 1:10, 1:20). After 15 minutes of rotation, the degree of aggregation of the particles was estimated under low power magnification. Results were read as follows: 4+ reaction (all particles are agglutinated), 3+ reaction (75% of the particles are agglutinated), 2+ reaction (50% of the particles are agglutinated), 1+ reaction (25% of the particles are agglutinated). A 3+ or 4+ agglutination was considered positive.

Total IgE: Serum total IgE was determined by using an enzyme immunoassay system (Enzygnost IgE monoclonal, Behring). Titers greater than 300 IU/ml were considered significant.

RESULTS

Of 30 patients, 23% were housewives, 20% farmers 13% students, 10% carpetweavers and 26% had other occupations. Most of the patients were from Mashhad (26%) and in the first 20 years of life. All had continuous contact with dogs or domestic animals in their histories.

Table II. Complications in patients with hydatid cyst of lung

Infection	62%
rupture into bronchus	16%
Bronchopleural fistula	20%
rupture into pleural cavity	14%

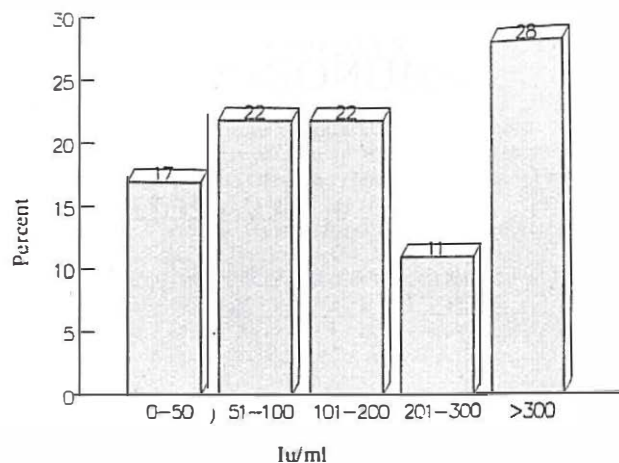


Fig. 2. Titer of total IgE in patients with hydatidosis.

Clinical presentation is shown in Table I. Cough was the most prominent clinical presentation in our patients (83%). Table II demonstrates the complications of hydatid cyst in the patients we studied. 87% of the cases had single cysts, following by 10% and 3% for two and multiple cysts, respectively. 60% of the patients had cysts in the right lung.

In the chest x-ray of the patients, pleural effusion was seen in 60% of the cases (Table III). Only 37% of the patients had a round and homogenous density (an intact cyst) in their radiograph. In hematological examination of patients, eosinophilia (eosinophilis > 5%) was seen in 43% of patients and eosinophilia more than 20% was seen in only 6.5%. Leukocyte count in 32% of cases was above 11,000. Although ESR is not a specific test, it was between 20-50 mm/hr in 47% of patients.

Figure 1 indicates the percent of positive cases for serum immunological and Casoni's tests. Serum total IgE of the patients is shown in Fig. 2.

DISCUSSION

Hydatid cyst can persist in the body for many years (even 20 years) without any manifestation. Normally the age of the patients is in the range of 30-50 years in most areas of the world. However in this study, most of

Table III. Chest x-ray findings in patients with hydatid cyst of lung

Pleural effusion	60%
Round homogenous density	37%
Non-homogenous density	27%
Air-fluid level in lungs	23%
Water-lilly sign	23%
Shift of heart and mediastinum	10%
Crescent sign	7%
pneumothorax	7%

the patients were in the range of 10-19 years old. Clinical presentation in most of our patients was non-specific, since productive cough, dyspnea, and chest pain may be seen in many kinds of pulmonary diseases. Most of our patients had presented with a complication of hydatid cyst such as infection, rupture of cyst or bronchopulmonary fistula. In these conditions as expected, radiologic findings were also nonspecific. Pleural effusion was the prominent radiographic sign in 60% of the patients and typical signs of hydatid cyst were seen in only 37% of cases.

Many types of tests have been used successfully for the serological diagnosis of hydatid disease. In this study the IHA, BF and Casoni's test were evaluated for use in the serodiagnosis of hydatid disease. Sera producing high IHA titers ($>1:512$) are usually positive with BF. However the significance of low IHA titers is equivocal, as they have occurred with sera from patients with collagen disease, liver cirrhosis and with other parasitic infections.

The specificity is high only when titers of 1:512 and above by IHA, and 3+ and above by BF are considered positive. In contrast to IHA and BF tests, Casoni results had less sensitivity. This may be because of difficulty with skin tests. Casoni's test however shows as high as 18 percent false-positive results.

The present study demonstrates that the BF test has the greatest sensitivity for detection of hydatidosis. IgE is one of the known human immunoglobulins whose

protective role against parasitic infections in man has been confirmed. In our study, 28% of patients had high serum total IgE, but most of them were in the normal range (up to 300 IU/ml).

In conclusion, the present study using serological tests for diagnosis of hydatid disease showed that using either IHA or BF in combination with clinical findings can help to make an accurate and easy diagnosis of hydatid cyst.

REFERENCES

1. Cherubin: Non-specific reaction to Casoni antigen. *Am J Trop Med Hyg* 18:387-390:1967.
2. Fischman A: Flocculation tests in hydatid disease. *J Clin Pathol* 13:72-75:1960.
3. Kagan I G, Norman L, Allain D S, Goodchild C G: Studies on echinococcosis: non-specific serologic reactions of hydatid fluid antigen with serum of patients ill with disease other than echinococcosis. *J Immunol* 84:635-640, 1960.
4. Kagan IG: A review of serological tests for the diagnosis of hydatid disease. *Bull WHO* 39:25-37,1970.
5. Lass N, Laver Z, Olengy J: The immunodiagnosis of hydatid disease: post-operative evaluation of the skin tests. *Ann Allergy* 31:430-436,1973.
6. Norman L, Osadun EH, Allain D S: A bentonite flocculation test for the diagnosis of hydatid disease in man and animals. *Am J Trop Med Hys* 3:46-50,1980.
7. Schantz, et al: Serologic cross-reactions with sera from patients with echinococcosis and cysticercosis. *Am J Trop Med Hyg* 29:609-612:1980.