

Basic Science In Medicine

CORRELATION BETWEEN ELECTROCARDIOGRAPHIC AND HISTOPATHOLOGICAL CHANGES IN ISOPRENALINE-INDUCED MYOCARDIAL INJURY

KESHAV ANAND, MBBS, MD,* SAROJ PANDE, MBBS, MD,** AND
R.K. GUPTA, MBBS, MD.***

From the *Dept. of Physiology, Medical School, Kerman University of Medical Sciences, Kerman, **Dept. of Physiology, Maulana Azad Medical College, New Delhi, India, and ***Dept. of Pathology, Medical School, Kerman University of Medical Sciences, Kerman, Islamic Republic of Iran.

ABSTRACT

Myocardial injury was induced in 25 dogs by infusing isoprenaline, 2-4 microgram per kg per minute for the duration of six hours. 10 dogs served as controls which received only physiological saline. Animals receiving isoprenaline 2 microgram per kg per minute were labelled as experimental group A and other receiving microgram per kg per minute as experimental group B. Histopathological observations in experimental groups A & B showed subendocardial haemorrhage in the papillary muscles and apex of left ventricle as early as two-three hours of infusion. Focal lesions characterized by congestion, dilatation and extravasation of blood was observed near necrotic myocardium. Group A animals showed only severe tachycardia while in group B myocardial infarction in 80% and only ischaemic changes in 20% of animals were observed. Out of animals in group B, 37.5% developed myocardial infarction after two hours of infusion while remaining 62.5% developed changes after four hours. Histopathological changes were very well correlated with ECG findings observed in the present study.

MJIRI, Vol. 4, No. 4, 287-291, 1990

INTRODUCTION

Urbanisation and industrialisation have brought in their wake, tension and worries which have led to a steady increase in incidence of myocardial infarction (MI) which has reached epidemic proportions. This is the most killing and disabling disease of modern man in this era. Physicians have come to rely greatly on ECG, though it is well known that there are patients with MI in whom ECG does not show any abnormality. The WHO Expert Committee on Cardiovascular Disease and Hypertension (1954)¹ considered that out of all the investigations available, perhaps none is as helpful as electrocardiography. Myocardial lesions induced by

means other than vascular occlusion have been the subject of intensive study during recent years. Chappel, et al (1951)³ observed that animals receiving doses greater than one fourth the lethal dose of isoproterenol showed severe lesions in the lungs, brain, liver and kidney consistent with the picture of severe shock. These lesions were characterised by pulmonary oedema and haemorrhage and cerebral oedema. In dogs given prolonged infusion of norepinephrine, the lesions consisted of focal myocardial necrosis, accumulation of inflammatory exudate and epicardial hemorrhage. Chappel and associates (1959)² studied the comparative cardiac necrotising activity of isoprena-

EKG and Pathologic Changes in Myocardial Injury

Table I. Morphological grading of myocardium after isoprenaline-induced myocardial injury in dogs

Grade 0	No lesion.
Grade I	Mottling of the apex and part of left ventricle with dark red streaks.
Grade II	Focal haemorrhage limited to apex.
Grade III	Focal subendocardial haemorrhage mainly in papillary muscles and apex and extending to interventricular septum.
Grade IV	Focal haemorrhages in the papillary muscles of left ventricle and atrioventricular valve cusps, extending to the right ventricle and auricle.

line in rats. Cardiotoxic action of isoprenaline which induces an infarct-like necrosis, has been of particular interest since standardized doses consistently produce myocardial lesions of reproducible severity (Rona, et al, 1954).⁴ Rona, et al (1962)⁵ from their experimental studies on rats, showed that isoprenaline produced an infarct-like necrosis of ventricular myocardium. Kraikitpanitch, et al (1976)⁶ induced myocardial injury in mongrel dogs by infusing epinephrine at the rate of 4 µg/kg/min for six hours at a flow rate of 2 ml per minute. Jennings, et al (1960)⁷ reported classical ST-segment elevation in myocardial necrosis in leads I, III and aVF in dogs after occluding the circumflex branch of coronary artery. Norman, et al (1961)⁸ studied ECG changes in 10 rats in which left coronary had been ligated. Anterior and apical transmural infarction were found to reliably produce alterations in the ECG consisting of Q wave deformity, increased amplitude of R wave, lengthening of QT interval and QR or QS configuration.

The present study has been aimed to define more clearly the correlation of electrocardiographic and histopathological changes in experimentally-induced myocardial infarction which closely resembles the myocardial infarction in human beings.

MATERIAL AND METHODS

This work was conducted on 35 dogs, dividing them into two groups. The control group comprising of 10 dogs received continuous infusion of physiological saline at the rate of 2 millilitres per minute for six hours. The experimental group of 25 dogs, subdivided into experimental group A consisting of five animals (low dose group) received 2 µg/kg/min and experimental group B comprised of 20 dogs (high dose group) received 4 µg/kg/min for the duration of six hours.

After six hours of infusion, or after the death of the animal during the procedure, the animals were sacrificed and hearts were removed and injected with 10% sucrose solution through the aorta. They were cut open and washed with physiological saline and were evaluated morphologically for gross lesions as given in Table I.

Table II. Microscopic grading of myocardium after isoprenaline-induced myocardial injury in dogs.

Normal	No change.
Mild change	Focal involvement of myocardium showing loss of striations and fatty vacuoles.
Moderate Change	Focal involvement of myocardium showing necrosis and leukocytic infiltrations.
Severe Change	Focal changes seen in myocardium. The myocardial fibres showing abnormal staining capillary dilatation and haemorrhage and oedema in the interstitium. Vacuolar and fatty degeneration, granular disintegration and hyaline necrosis of muscle fibres.

Samples of myocardium showing massive haemorrhage and necrotic changes were taken for histological study. After dehydration in different grades of alcohol, cleaning was done in cedar wood oil. Paraffin blocks were made and frontal sections of the myocardium were cut and stained with hematoxyline and eosin. The severity of lesions were graded microscopically as shown in Table II.

Diagnostic criteria for defining myocardial ischaemia and infarction based on ECG pattern were taken as alterations in ST-segment, T-wave changes and significant Q wave or development of QS wave complex with ST and T wave changes.

RESULTS

Electrocardiogram: No alterations from the standard ECG pattern were noted in the control group, which only received physiological saline infusion. In the experimental group of five animals which were given two microgram isoprenaline infusion per kilogram per minute for six hours, ST and T-wave changes were noted as a result of profound tachycardia (Fig. 1) and no specific infarction pattern was observed even after six hours. In exp. group B (high dose group) 16 animals (80%) showed definite changes indicative of myocardial infarction and the remaining four dogs (20%) showed ischaemic changes by means of ST-segment and T-wave alterations. With respect to time course, six animals (37.5%) out of the sixteen dogs developed changes characteristic of infarction within two hours of isoprenaline infusion, whereas the remaining ten dogs (62.5%) developed changes only after four hours. As regards location of infarction, 12 animals (75%) showed changes in ECG indicative of inferior wall infarction (Fig. 2) whereas in four animals (25%) infarction was confined to the anterior wall (Fig. 3).

Histopathological changes:

Macroscopic: No significant changes were observed in hearts from control animals after six hours of infu-

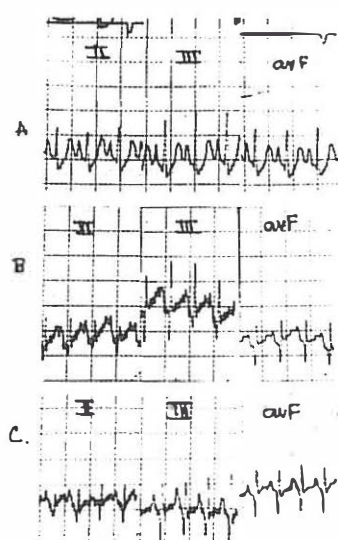


Fig. 1. EKG showing tachycardia alone even after 4 hours of infusion of isoprenaline ($2 \mu\text{g/kg/min.}$) The ST segment changes are due to profound tachycardia. (Heart rate 300 beats/minute).

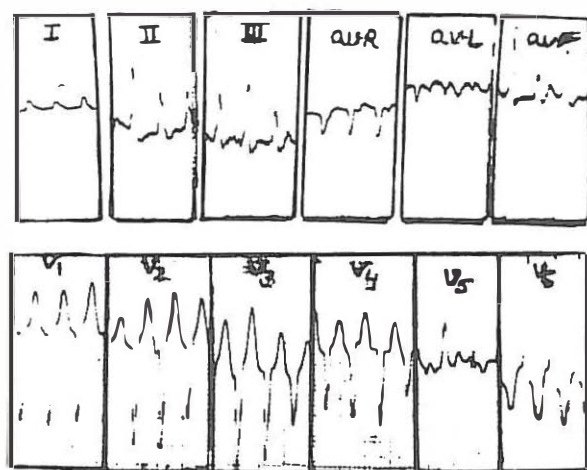


Fig. 2. EKG at basal level (A) and after 2 hours of isoprenaline infusion showing inferior wall infarction (B) which persists at 4 hours of infusion (C).

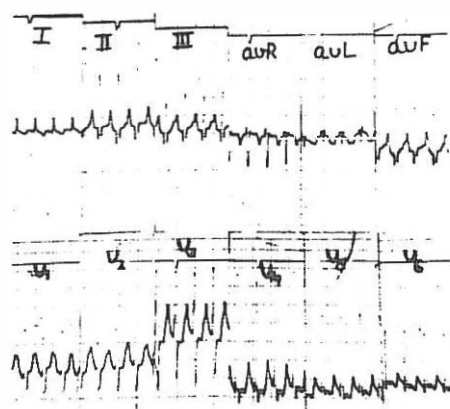


Fig. 3. EKG after 4 hours of infusion showing anterior wall infarction and a few occasional ventricular ectopic beats (aVF and V_5).

Table III. Macroscopic picture of the myocardium

Grade	Control	Experimental	
		A	B
0	10	-	-
I	-	4	1
II	-	1	5
III	-	-	9
IV	-	-	5

sion with physiological saline. In the two experimental groups A and B, infused with 2 and 4 microgram doses of isoprenaline respectively, a marked increase in heart weight as compared to control was observed. As shown in Table III, changes in myocardium were more marked in the group of animals which had received the higher dose of isoprenaline. These changes comprised of subendocardial haemorrhage in the papillary muscles and apex of the left ventricle and occasional haemorrhage in the mitral cusps, right ventricle and auricle.

Microscopic: The microscopic lesions in the hearts of isoprenaline treated dogs consisted of subendocardial haemorrhage which was focal in character. The myocardium also showed focal lesions, characterized by swelling of the myocardial fibres, (Fig.4), variable degree of necrosis and leukocytic and histiocytic infiltration (Fig.5). The interstitium near the area of myocardial necrosis showed oedema, capillary congestion and dilatation and extravasation of blood at many places (Fig.6). These lesions have been classified as mild, moderate and severe as described under material and methods. Of the animals belonging to experimental group A (five animals) "low dose group", three (60%) were found to have mild changes in the myocardium.

Of the 20 animals comprising the high dose group (experimental group B), 12 animals (60%) were observed to have marked changes in the myocardium, even when the animal died of myocardial infarction before the experiment was over i.e. between two to four hours. Six dogs (30%) showed moderate changes and two animals (10%) showed only slight changes.

DISCUSSION

Electrocardiographic Changes: Isoprenaline being a beta-adrenergic stimulant has a positive chronotropic and inotropic effect on the heart. Consistent with this concept, tachycardia was observed in all the animals treated with isoprenaline. Besides this, other electrocardiographic changes were also observed in the experimental group animals. The uniformity of polariza-



Fig. 4. Microphotograph shows swollen myocardial fibres with fatty vacuoles (H & E X 400.).

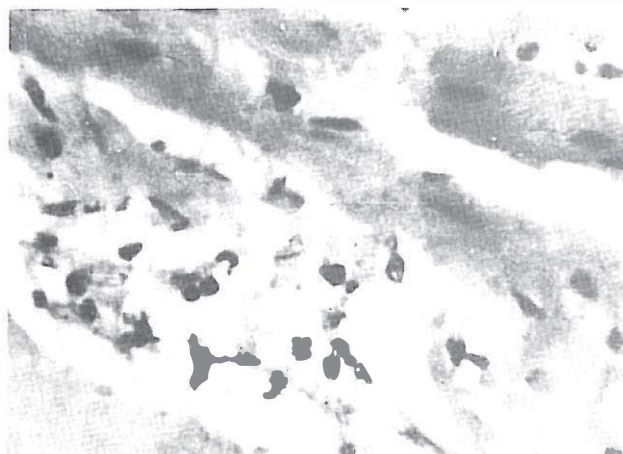

Fig. 5. Microphotograph shows swollen myocardial fibres with necrosis. (H & E X 400).

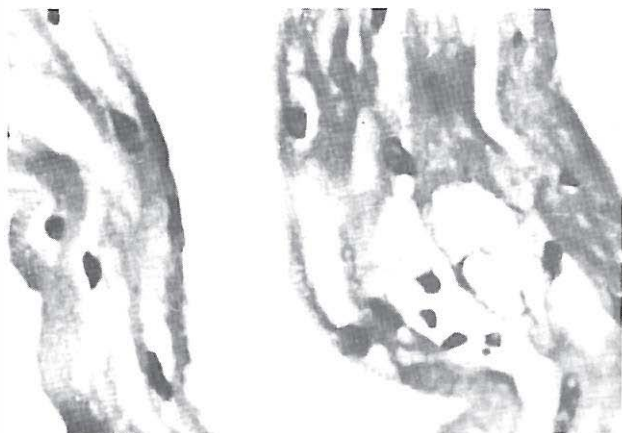

Fig. 6. Microphotograph shows marked interstitial oedema with dilated capillaries in between the myocardium. (H & E X 100).

tion during electrical diastole of ventricles and also the repolarization process appeared to be affected in most of the ECG recordings, as there were ST-segment deviation and T-wave changes similar to those of myocardial ischaemia. The low dose group comprising of five animals only showed marked tachycardia. Sixteen (80%) out of 20 animals in experimental group B showed definite changes indicative of myocardial infarction.

As regards time sequence, six animals (37.5%) showed changes of myocardial necrosis within two hours of isoprenaline infusion and the remaining ten (62.5%) developed changes four hours after infusion. Inferior wall infarction was seen in 12 animals (75%) while four (25%) showed anterior wall infarction. Four animals in experimental group B (high dose group) only showed supraventricular tachycardia with ST segment and T wave changes. Mahajan, et al (1976)⁹ produced myocardial infarction in monkeys by intravenous infusion of noradrenaline at the rate of 20 microgram/kg/minute and observed ST, T changes due to tachycardia in most of the animals. In some animals they observed abnormal Q and QS patterns revealing recent acute myocardial infarct. Hill, et al (1960)¹⁰ produced electrocardiographic changes characteristic of myocardial ischaemia and focal subendocardial necrosis by isoprenaline administration in rats. Chopra and Nag (1972)¹¹ reported myocardial damage in left ventricle of dogs within a few seconds after coronary ligation. Ganguly, et al (1987)¹³ observed in their experimental study that increased norepinephrine levels in plasma is associated with functional, biochemical and ultrastructural alterations in cardiac cells. The extent of the increase in catecholamine levels is now known to be related to the severity of the infarction and to the development of arrhythmias.¹⁴ Mueller & Thoenen (1971)¹⁵ observed that isoproterenol-induced myocytolysis in heart muscle is associated with an increased turnover of norepinephrine as a result of increased release of a physiologically active neurotransmitter.

Histopathology: Chappel, et al (1951)³ reported increase in heart size and weight in rats treated with high dose of isoprenaline (82 mg/kg body weight). Infarct-like myocardial lesions involving the apex, lower part of left ventricle, interventricular septum and occasionally the right ventricle were also observed. Histology revealed hyaline necrosis of myocardial fibres with marked fatty changes, leukocytic reaction and sequestering interstitial oedema. Small doses were not found to produce gross lesions in the heart. Subendocardial heamorrhage and fuchsinophilic degeneration of conductive tissue were reported by Szakacs and Mehlman (1960)¹² in dogs treated with norepinephrine at a rate of 1 microgram per kg body weight per minute

for 10 hours. Ganguly, et al (1989)¹⁶ and Rossi & Carillo (1985)¹⁷ observed the enlargement of the myocardial muscle mass and cardiac hypertrophy in patients when the catecholamine activity increases. Macroscopic appearance of the myocardium in experimental dogs in the present study suggested endocardial haemorrhage in papillary muscles, which was confirmed by the microscopic picture of focal subendocardial haemorrhage. Capillary haemorrhage, especially in the subendocardium seen in the present series could be explained on the basis of the profound and prolonged ventricular tachycardia which was observed in the experimental animals in the present study. The tachycardia prevents capillary blood flow in the subendocardial area where the pressure gradient is the highest. Under the stress of mounting oxygen debt, the walls of the blood vessels in the capillary muscles become permeable and allow blood to escape into the surrounding tissues. In the end it could be stated that appearance of subendocardial haemorrhage and other histological changes in the cardiac tissue, and the electrocardiographic events are a train of events initiated by tachycardia and set in motion by hypoxia and end in a well-defined myocardial necrosis simulating human myocardial infarction.

ACKNOWLEDGMENT

The authors are grateful to Dr. O.P. Bagga, Professor and Head of the Dept. of Physiology, Lady Hardinge Medical College, New Delhi for his input at various stages of this project, and Dr. S. Chawala, principal and medical superintendent, L.H.M.C. New Delhi, for encouragement and providing facilities for this work.

REFERENCES

1. World Health Organisation Expert Committee on Cardiovascular Diseases and Hypertension Tech. Report Series, WHO, No 168, pp.18, 1959.
2. Chappel C I, Rona G, Balazs J, Gandry R: Comparision of cardiotoxic actions of certain sympathomimetic amines. *Canad J Biochem Physiol* 37 35, 1959.
3. Chappel C I, Rona G, Balazs T, Gaudry R: Severe myocardial necrosis produced by isoproterenol in the rats. *Arch Internal Pharmacodyn* 122-123, 1951.
4. Rona G, Chappel CI, Valazs T, Gaudry R: Infarct-like myocardial lesions and other toxic manifestations produced by isoproterenol in rats. *A M A Arch Pathol* 67, 443.
5. Rone G, Chappel C I, David S K: The pathogenesis of atrial infarction, experimental data. *Am J Pathol* 41(4), 1962.
6. Kraikitanitch S, Haygood C C, Baxter D J, Aniece A, Yunique R, Lindeman D: Effects of acetylsalicylic acid, dipyridamole and hydrocortisone on epinephrine induced myocardial injury in dogs. *Am Heart J* 92(5) 615, 1976.
7. Jennings R B, Sommers H M, Smyth G A: Myocardial necrosis induced by temporary occlusion of the coronary artery in the dogs. *Arch Pathol (Chicago)* 70, 68, 1960.
8. Norman S J, Robert D S, Priest E, Benditt E P: Electrocardiogram in the normal rat and its alterations with experimental coronary occlusion. *Circ Res* 9, 282, 1961.
9. Mahajan V, Kumar M, Chakravarty R N, Wahi P L: Studies of cardiovascular effects of nor-adrenaline in monkeys. *Bull P G I* 10,2, 1976.
10. Hill R, Howard A N, Gresham G A: The electrocardiographic appearances of myocardial infarctions in rats. *Brit J Experimental Path* 41,633, 1960.
11. Chopra H L, Nag K N: Enzyme study in experimental myocardial infarction in dogs. *Ind Heart J* 24, 31, 1972.
12. Szakacs J E, Benjamine M: Pathologic changes induced by L-norepinephrine: Quantitative aspects: *Am J Cardiol* 5, 619 1960.
13. Ganguly PK, Dalla KS, Beamish RE, Innes IR, Dhalla NS: Involvement of catecholamines in the development of diabetic cardiomyopathy. In: Dhalla NS, Singal PK, Beamish RE, (eds). *Pathophysiology of Heart Disease*. Boston: Martinus Nijhoff Publishing P.237-48, 1987.
14. Bertel O, Buhler FR, Vaitsch G R, Burkart F: Plasma adrenaline and noreadrenaline in patients with acute myocardial infarction. Relationship to ventricular arrhythmias of varying severity. *Chest* 82:64-8, 1982.
15. Mueller RA, Thoenen, H: (1971): Cardiac catecholamine synthesis turnover and metabolism with isoproterenol-induced myocytolysis. *Cardiovasc Res* 5:364-70, 1971.
16. Ganguly PK, Lee SL, Beamish RE, Dhalla NS: Altered sympathetic system and adrenoceptors during the development of cardiac hypertrophy. *Am Heart J (In press)*, 1989.
17. Rossi MA, Carillo SV: Does norepinephrine play a central causative role in the process of cardiac hypertrophy?. *Am Heart J* 109:622-4, 1985.