

THALLIUM-201 STRESS TEST IN 156 PATIENTS WITH SUSPECTED CORONARY ARTERY DISEASE

FEREIDOON NOOHI, S. HASSAN FIROOZABADY, FEREIDOON
RASTGOO, AHMAD MOHEBBI, FARZAD ABBASPOUR, MAJEED
DEHGHAN AND NAHID YAGHOOBI

*From the Departments of Nuclear Medicine and Cardiology, Shahid Rajai Cardiovascular Center,
Tehran, Islamic Republic of Iran.*

ABSTRACT

Currently, myocardial Tl-201 scintigraphy is most often performed in conjunction with exercise stress testing in patients with suspected or known CAD. Stress thallium tests were performed for 156 patients with and without old myocardial infarctions complaining of chest pain. All of them underwent contrast coronary angiography. Perfusion defects were mostly manifested as reversible defects (R). Sensitivity of visual detection was generally 93%. The anteroseptal wall and septum showed defects more often than the other segments in patients with LAD stenosis. The inferolateral walls showed the least defects in RCA involvement. There was a significant difference between mean stenosis of LADs ($90 \pm 10\%$) and CXs ($82 \pm 11\%$) ($P < 0.0005$), making sensitivity of detection low for stenosed CX arteries.

MJIRI, Vol. 9, No. 4, 295-299, 1996.

INTRODUCTION

Since 1975 thallium-201 (Tl-201) has been widely employed as a radiopharmaceutical for imaging of the heart and assessment of regional myocardial perfusion.^{1,2} Thallium-201 accumulates in the heart proportional to myocardial blood flow and myocardial mass.^{3,4} The most consistent observation is that the presence and extent of transient Tl-201 defects, as a marker of jeopardized viable myocardium, predicts important future cardiac events.⁵ In a large group of patients with suspected but not documented coronary artery disease, it was seen that among clinical and scintigraphic variables the number of reversible Tl-201 defects was the best predictor of future cardiac events.⁶

Thallium is a metallic element with biological properties similar but not identical to those of potassium. The distribution of thallium ions following intravenous administration is primarily intracellular.⁷ There is rapid clearance of the tracer from the blood pool 15 minutes after injection. It moves from cell to cell and site to site in the body. Studies with Tl-201 and K-42 suggest that both ions rely on Na^+/K^+ -ATPase-dependent active transport for cell

entry.⁸ Currently, myocardial Tl-201 scintigraphy is most often performed in conjunction with exercise stress testing in patients with suspected or known coronary artery disease. Sensitivity and specificity for detection of physiologically significant stenosis employing quantitative planar or single photon emission computed tomography (SPECT) Tl-201 scintigraphy is in the range of 85% to 90%. Perfusion defects observed on initial post-exercise images can be indicative of either transient exercise-induced ischemia or scar tissue. To differentiate between the two, delayed images are necessary in order to assess whether or not redistribution has occurred. An initial defect showing complete or partial redistribution indicates ischemia and viability, whereas a persistent defect is suggestive of previous scar formation.¹⁰⁻¹³

MATERIALS AND METHODS

Patient population

Thallium-201 imaging results were compared with clinical, exercise electrocardiographic and angiographic data in a series of 156 consecutive patients who were referred to

Thallium Stress Test in CAD

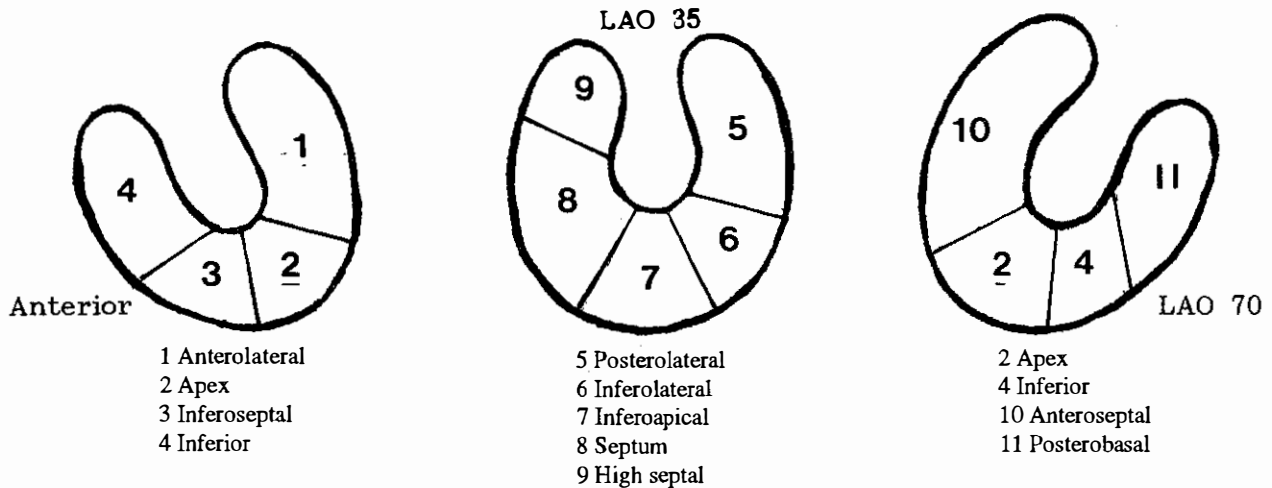


Fig. 1. Diagram of the standard segmentation scheme used for scoring Tl-201 scintigrams. The anterior view contains the anterolateral, apex, inferoseptal and inferior segments. The 35° left anterior oblique view (LAO 35°) includes posterolateral, inferolateral, inferoapical, septal and high septal segments. The LAO 70° view contains apex, inferior, anteroseptal and posterobasal segments.

the department of nuclear medicine with and without a history of myocardial infarction for evaluation of chest pain. Patients were divided into two groups, 1) those presenting with known or suspected coronary artery disease, and 2) post-myocardial infarction. Angiography was performed for all patients just 2 days after thallium scanning. The study group consisted of 121 males and 35 females with an overall age of 49 ± 9 yr (mean \pm SD, range 33 to 70 yr). Their characteristics are depicted in Table I.

Table I. Patient characteristics.

Number of patients	156
Gender	121 men (78%), 35 women (22%)
Mean age	49 yr. (range 30 to 70 yr.)
Women	49 yr (range 32 to 61)
Men	49 yr. (range 30 to 70)
OMI	77 pts.
Chest pain	Typical 105 Atypical 48

Cardiac catheterization

Standard coronary angiography was performed by percutaneous transfemoral approach using Judkins' method. The pressure of the left ventricle and aorta was measured; then ventriculography was performed in a right anterior oblique (RAO) view. In case of a left ventricular aneurysm the dye was injected in a left anterior oblique (LAO) view as well. Selective coronary angiography was performed in RAO, cranial and caudal positions. All images were recorded on 35 mm film at 50 frames/sec, reviewed on a Tagarno projector and interpreted by consensus of two independent observers. Stenoses of coronary vessels were coded according to criteria of the American Heart Association.¹⁴ Significant stenoses of coronary vessels were defined as a reduction of $>70\%$ in luminal diameter of at least one of the three major epicardial coronary vessels.

Exercise protocol

Patients underwent calibrated couch ergometer testing using the symptom limited exercise pulse pressure product (PPP) protocol with stepwise increased workload. A positive electrocardiogram (ECG) was defined as a horizontal or downsloping ST segment depression of >2 mm. Exercise

Table II. Variety and number of defects in 590 segments related to significantly stenosed LADs (≥ 75).

	I	R	F	P	Total
Anterolateral	1	4	1	7	13
Anteroseptal	10	17	13	16	56
High septal	2	2	1	2	7
Septum	6	23	10	13	52
Apex	2	8	6	7	23
Total	21	54	31	45	151

I= irregular
R= redistributed
F= fixed
P= partially redistributed

started from 25 kilowatts, increasing by 25 kilowatts every 2 minutes. Beta-blocking agents and calcium channel blockers were stopped 2 days and digitalis derivatives 1 week before the test.

At maximum exercise, a dose of 75 MBq (2mCi) of Tl-201 was injected through an indwelling intravenous cannula and exercise was continued for 1 more minute.

Table III. Variety and number of defects in 415 segments related to significantly stenosed RCAs (≥ 70).

	I	R	F	P	Total
Inferior (ant.view)	2	3	6	4	15
Inferior (lat.view)	1	5	3	4	13
Inferolateral	0	3	4	1	8
Apex	1	4	3	5	13
Inferoapical	1	9	8	4	22
Total	5	24	24	18	71

Table IV. Variety and number of defects in 202 segments related to significantly stenosed CXs (≥ 70).

	I	R	F	P	Total
Posterolateral	0	5	2	5	12
Posterobasal	0	4	4	1	9
Total	0	9	6	6	21

Table V. Results of coronary angiography and TI-201 stress tests in 105 patients with typical chest pain.

Symptom	Scan Positive	Scan Negative
Typical	105	101
Angio positive	96 (96/105) (91%)	95 (95/96) (98%)
Angio negative	9 (9/105) (8%)	6 (6/9) (66%)
Atypical	48	39
Angio positive	31 (31/48) (64%)	28 (28/31) (90%)
Angio negative	17 (17/48) (35%)	4 (4/17) (23%)

Table VI. Variation of factors causing false-positive thallium scans in six patients with normal coronaries.

Case	Factors
First	Hypertension, Diabetes
Second	High septal defect (one view)
Third	ST change, Severe angina (X-disease)
Fourth	Moderate lesion
Fifth	Cardiomyopathy
Sixth	LBBB

Thallium myocardial imaging

Planar myocardial perfusion imaging was performed with an Anger camera Picker SX-200 large view field, low energy, general purpose collimator with energy window centered on the 75 keV photon peak of TI-201. Images were obtained in LAO (30 degrees), left lateral (70 degrees) and

anterior projections in the supine position. Initial and 4 hr delayed images were obtained by 500000 counts per image. Eleven myocardial regions were defined from the three views: anteroseptal, anterolateral, apex, inferoapical, inferior, inferoseptal, posterolateral, posterobasal, inferolateral, high septal and septum (Fig. 1).

Statistical analysis

Degrees of coronary stenosis are expressed as mean +1 SD percent, and differences in LAD, RCA and CX were analyzed using the Student's t-test. Probability values of less than 0.05 were considered significant.

RESULTS

Of 156 patients, 130 had significant narrowing of at least one major coronary artery. 121 of them (121/130) had perfusion defects in at least two views (sensitivity 93%). A perfusion defect was seen in 108 out of 114 patients with significantly stenosed LADs (94%) and in 75 out of 80 patients with significant RCA stenosis (93%). Defects were demonstrated in 89 out of 93 patients (95%) with significantly stenosed CX arteries as well. In 81 patients (62%, 81/130) significant stenosis of all three major coronary vessels was present; 38 patients (29%, 38/130) had significant stenosis of two major coronary vessels, and in the remaining 11 (8%, 11/130) only one coronary vessel was significantly stenosed. Good collateral circulation was observed in 81% (44/54) of all completely occluded coronary arteries. Of the 1430 myocardial segments related to the 130 involved patients, the perfusion defect in 243 related segments was classified as irregular (I) in 26 (10%); redistributed (R) in 87 (35%); fixed (F) in 61 (25%) and partially redistributed (P) in 70 (28%). Tables II, III and IV show involved segments in the territory of each major coronary artery.

In 302 significantly stenosed major coronaries, LADs were determined to have significant reduction of luminal diameter in 118 patients (90% + 10% (mean + SD)), RCAs in 83 patients (86%+12%) and Cx in 101 patients (82%+11%) (Fig. 2).

Chest pain or chest discomfort was the main and most common symptom in our group of patients (98%, 153/156). 105 patients presented with typical chest pain and 48 patients with atypical chest pain. Coronary artery disease was documented by angiography in 96 of these patients (96/105, 92%), while only 9 patients showed no significant coronary narrowing (9/105, 8%) (Table V). In 48 patients with atypical chest pain, 31 of them (31/48, 64%) had coronary artery disease (CAD), while 17 patients (17/48, 36%) showed no evidence of CAD. The thallium scan of these patients revealed perfusion defects in 32 out of 48 patients (32/48, 66%).

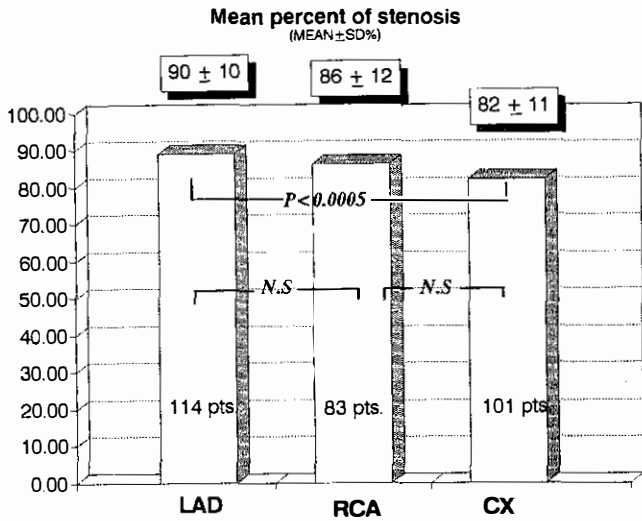


Fig. 2. Percent of stenosis in the three major coronaries. There is a significant difference between mean stenosis of LAD and CX arteries ($P < 0.0005$).

DISCUSSION

Although 25% of defects were manifested as fixed, perhaps implying an old myocardial infarction, lack of redistribution may not necessarily indicate scar tissue.¹⁵ Ten percent of the group showed irregular defects. A number of cardiomyopathies are studied with TI-201 to determine the absolute uptake as a function of total myocardial mass or to define areas within the myocardium that become dysfunctional and replaced by fibrosis or are necrotic. The irregular defects in our study were seen as redistributed, partially redistributed and fixed defects.

A small number of true negative cases had angiographically documented normal coronaries (26/156). Six of them (6/26) had factors causing false positive results (Table VI). Concerning this fact, the calculated specificity could not be statistically reliable. The high sensitivity of visual detection in this study may represent the abundance of multivessel disease in our group of patients.

There is a significant difference between LAD stenosis (90% ± 10%) and reduction of luminal diameter of CX arteries (82% ± 11%) ($P < 0.0005$) (Fig. 2). Regarding this difference and with respect to the fact that most of our patients have 2 v.d. and 3 v.d., during stress, ischemia of LAD territories was manifested as significant ST depression and severe angina at a time when there was no evidence of ischemia in the territory of CX. This fact may decrease the sensitivity of this test for CX, as this may be the case in our study.

Table II shows that the anteroseptal wall and septum demonstrate perfusion defects much more commonly than the other segments. Table III implies that the inferolateral segment has the least rate of defects and may not be reliable

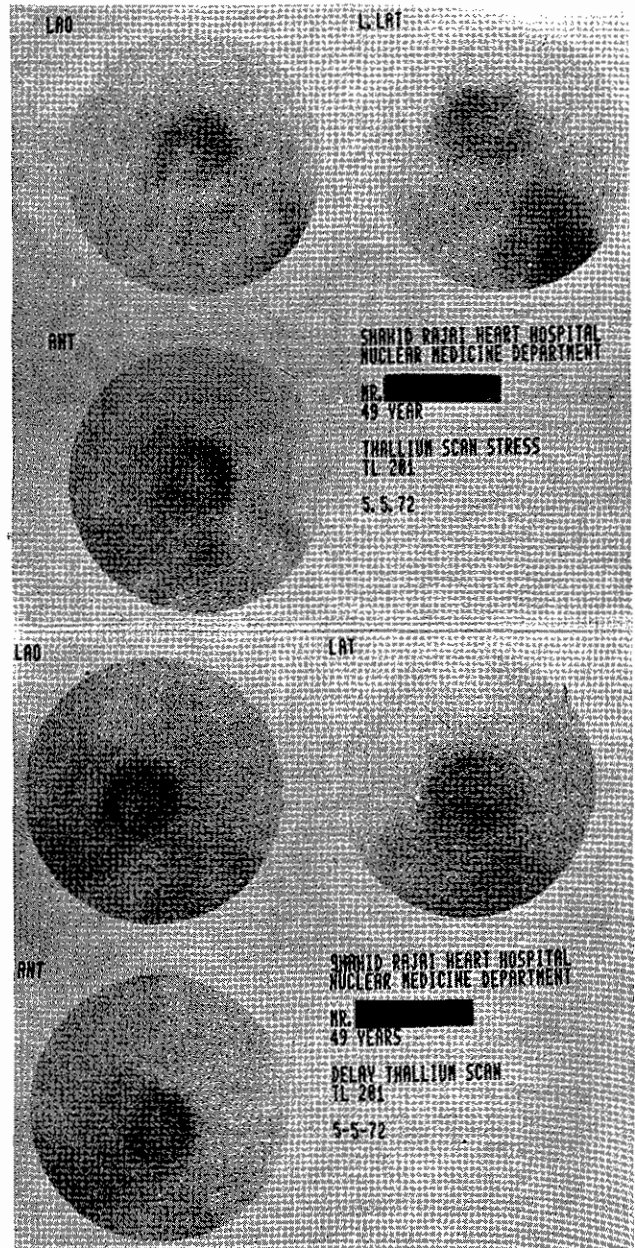


Fig. 3. Initial (left images) stress and 4-hour delayed (right images) planed thallium scintigram showing reversible perfusion defects involving the inferior wall and apex in a 49 year old man. Coronary angiogram (not shown) revealed a significant stenosis in the middle portion of RCA.

for evaluating ischemia of the other segments related to RCA. Although CX's relative regions are small in number, nevertheless as seen in Table IV posterolateral and posterobasal segments did not differ significantly in showing defects.

REFERENCES

1. Bradley-Moore PR, Lebowits E, Greene MW, Atkins HL,

- Ansari AN: Thallium-201 for medical use. II: biologic behavior. *J Nucl Med* 16: 156, 1975.
2. Wackers FJTH, van der Schoot JB, Busemann Sokole E, Samson G, Niftrik GJC, Lie KI, Durrer D, Wellens HJJ: Noninvasive visualization of acute myocardial infarction in man; thallium-201. *Br Heart J* 37: 741, 1975.
 3. Strauss HW, Harrison K, Langan JK, Lebowitz E, Pitt B: Thallium-201 for myocardial perfusion. *Circulation* 51: 641, 1975.
 4. Wackers FJTH, Kaly JW, Laks H, Schnitzer J, Zaret BL, Geha A: Pathophysiologic correlates of right ventricular thallium-201 uptake in a canine model. *Circulation* 64: 1256, 1981.
 5. Brown KA: Prognostic value of thallium-201 myocardial perfusion imaging in patients with unstable angina who respond to medical treatment. *J Am Coll Cardiol* 17: 1053, 1991.
 6. Ladenheim ML, et al: Extent and severity of myocardial reperfusion as predictors of prognosis in patients with suspected coronary artery disease. *J Am Coll Cardiol* 7: 464, 1986.
 7. Mullins LJ, Moore RD: The movement of thallium ions in muscle. *J Gen Physiol* 43: 759, 1960.
 8. Gehring PJ, Hammond PB: The interrelationship between thallium and potassium in animals. *J Pharmacol Exp Ther* 155: 187, 1967.
 9. Kotler TS, Diamond GA: Exercise thallium-201 scintigraphy in the diagnosis and prognosis of coronary artery disease. *Ann Intern Med* 113: 684, 1990.
 10. Berger BC, et al: Quantitative thallium-201 exercise scintigraphy for detection of coronary artery disease. *J Nucl Med* 22: 585, 1981.
 11. Maddahi J, et al: Improved noninvasive assessment of coronary artery disease by quantitative analysis of regional stress myocardial distribution and washout of thallium-201. *Circulation* 64: 924, 1981.
 12. Wackers FJTH, et al: Quantitative planar thallium-201 stress scintigraphy; a critical evaluation of the method. *Semin Nucl Med* 15: 46, 1985.
 13. Watson DD, et al: Spatial and temporal quantitation of plane thallium myocardial images. *J Nucl Med* 22: 577, 1981.
 14. Austen WG, Edwards JE, Frye RL, et al: A reporting system on patients' evaluation for coronary artery disease: reports of the ASHOC Committee for grading of coronary artery disease, Council on Cardiovascular Surgery, American Heart Association. *Circulation* 51: 7-34, 1975.
 15. Liu P, Kiess MC, Okada RD, Block PC, Strauss HW, Pohost GM, Boacher CA: The persistent defect on exercise thallium imaging and its fate after myocardial revascularization: does it represent scar or ischemia? *Am Heart J* 110: 996-1001, 1986.