

TREATMENT OF SPONTANEOUS INTRACRANIAL HEMORRHAGE USING UROKINASE

A.R. BIRJANDI,* M.D., AND S. ZABIHYAN,** M.D.

From the Department of Neurological Surgery, Ghaem Medical Center, Mashhad University of Medical Sciences (MUMS), Mashhad, I.R. Iran.

ABSTRACT

Twenty patients with intracranial hematoma (ICH or IVH) were treated with direct infusion of urokinase through a catheter.

Reduction of hematoma volume was observed within a few days. Twelve patients showed good or excellent outcome. No infection or rebleeding was observed.

MJIRI, Vol. 14, No. 3, 245-248, 2000.

Keywords: Intracerebral hematoma, Treatment, Urokinase, Hypertension.

INTRODUCTION

Intracerebral hemorrhage (ICH) has been a clinical problem for as long as there have been physicians. There are numerous references in the Hippocratic writings (400 B.C.) referring to ICH and SAH.⁵

Since CT scan has become the main diagnostic method for intracranial lesions, spontaneous ICH as a cause of stroke is recognized more frequently than previously, and it needs more active intervention on behalf of neurosurgeons. Autopsies have shown that these lesions are as common as SAH,⁷ a problem of special interest to neurosurgeons.

Mortality rates of SICH are high, and either surgical or conservative management reviews suggest only about 50 percent survival in hospitalized patients.⁶

In this study, the authors lysed and removed clots (IVH or ICH) by administration of urokinase (UK) via a catheter. The methods and results are reported here.

MATERIALS AND METHODS

This series included 20 patients (6 female and 14 male, aged 38-82 years, mean: 57.7 years) with SICH, with or without associated IVH. IVH was the prominent pathology

in 3 patients, so the treatment protocol focused on removal of IVH (cases no. 1,5,12). The Glasgow Coma Scale was between 6 and 12. In each patient treatment was begun within the first 48 hours of ictus.

A parenchymal or ventricular large bore catheter was placed in each patient, and after initial drainage of the hematoma (5-10 cc), UK was infused (5000-10000 IU) and the catheter was clamped.

Infusion was given every 8-12 hours. Before each infusion the drain was opened. After free drainage of lysed clots gentle irrigation with normal saline was performed. Then UK was infused again, and the drain was clamped.

A CT scan was obtained immediately after placement of the catheter, and repeated every day or as required.

Therapy was continued until clearance of the hematoma on CT scan, and then the drain was removed. Narrow spectrum antibiotics, antiepileptics and antihypertensive drugs were given in all patients.

The time for clearance, complications and patient outcome were studied for each case (Table I).

RESULTS

The time required for clearance of the hematoma ranged from 4 to 7 days (Mean: 5 days).

Five patients exhibited excellent recovery without significant neurological deficit. Five patients recovered with mild neurological deficit (aphasia, hemiparesis). Two patients had a fair outcome with disabling neurological sequelae. Eight patients died, seven cases died before clear-

Correspondence: A.R. Birjandi, M.D., Department of Neurological Surgery, Ghaem Hospital, Mashhad, Iran, 91735. Fax: 51-821670, Tel: 51-821670, 09115155969, P.O. Box: 91375-4685.

*Associate Professor of Neurosurgery

**Resident of Neurosurgery

Treatment of ICH Using Urokinase

ance of the hematoma on CT scan (Table I). Two deaths were due to unrelated causes.

No infection or rebleeding of any kind due to UK infusion therapy was observed in this series except one case with a small contusion at the site of catheter entrance that was unrelated to UK infusion (case no. 16). Pneumocephalus developed in two during irrigation but was too mild to require further treatment (cases no. 17, 20).

DISCUSSION

Urokinase has been used extensively for the treatment of cerebral thrombosis,²⁻⁴ but only rarely for hemorrhagic disease. The safety of intracerebral administration of UK has been investigated in animal studies.^{6,11} In one experimental study using intraventricular UK in dogs, the time for disappearance of clots was 3-6 days; but it took 38-65 days in those nontreated.¹¹ This clot lysis time was significantly reduced in the treated group. In our subjects the clot lysis time for ICH was 2-7 days (mean: 5 days) and 4-6 days (mean: 5.3 days) for IVH.

Cisternal irrigation with UK to remove subarachnoid clots has been reported.^{6,10,11}

Early and complete removal is the goal of ICH therapy. The optimal approach must be rapid, using a

simple method with a high success rate. To reach this aim, minimally invasive methods, including stereotactic aspiration, endoscopic aspiration, and ultrasonic aspiration have been developed by some surgeons.^{5,6,8} The addition of fibrinolytic drugs, either first generation (UK) or second generation (tPA) forms, are facilitated by aspiration and irrigation in each of the above methods.

Doi et al. first reported their experience in using UK for treatment of hypertensive ICH, and after that this method was tried by other surgeons to treat ICH and IVH.^{1,6,8,9,11,12}

In rapid expansive hypertensive ICH, which is a rare condition (3% of HICH), early stereotactic evacuation with UK irrigation is more dangerous than open surgery. This point must be kept in mind during the acute phase of hypertensive

Bleeding complications have been reported by using UK (4%);⁸ and some have reported that this complication is less common with tPA (0.68%).⁹

In our series there was no bleeding complication, and we believe this was probably due to using the free drainage method instead of aspiration.

It has been suggested that for clots of more than 30 mL with a moderate degree of neurological impairment, acute aspiration along with fibrinolytic agents will lead to improved outcomes. Larger clots causing more severe

Table I. Case summary: outcome and complications.

Case No.	Age/ Sex	Interval before treatment(Hours)	GCS	Prominent hematoma on CT	Time for clearance (Days)	Outcome	Complication
1	45/M	24	10	IVH	4	Excellent	
2	55/F	10	6	ICH		Death	On 3rd day
3	60/M	24	9	ICH	5	Excellent	
4	82/M	36	6	ICH		Death	On 3rd day
5	38/M	12	10	IVH	6	Good	
6	65/F	6	6	ICH		Death	
7	55/F	4	10	ICH	6	Good	
8	50/F	12	8	ICH	5	Excellent	
9	49/M	12	9	ICH	7	Excellent	
10	60/M	6	8	ICH	7	Excellent	
11	68/M	36	7	ICH		Death	On 3rd day
12	60/M		9	IVH	6	Good	
13	60/M	48	9	ICH		Death	On 5th day
14	50/F	24	10	ICH	2	Good	
15	60/F	24	8	ICH	4	Fair	
16	45/M	24	11	ICH	5	Death	Renal Fail/Cont.
17	70/M	24	7	ICH		Death	Pneumocephalus
18	55/M	12	6	ICH		Death	Renal Failure
19	60/M	30	9	ICH	4	Excellent	
20	63/M	12	8	ICH	5	Good	Pneumocephalus

ICH: Intracerebral hematoma
M: Male F: Female

IVH: Intraventricular hematoma
Cont: Contusion

CTS: CT Scan

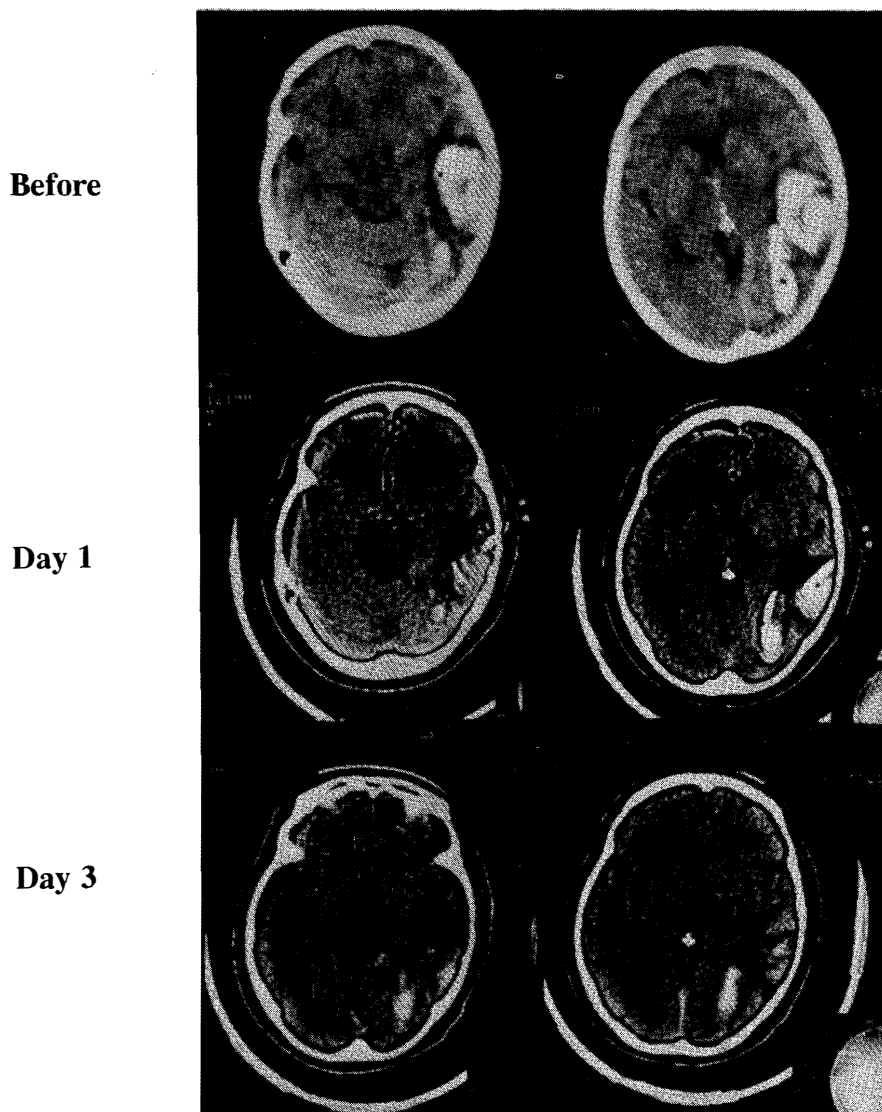


Fig. 1. CT findings in case 15 before and after urokinase infusion therapy.

clinical impairment require more rapid removal by open surgery.^{7,8}

In ICH series the mortality rate is similar to that with craniotomy but the outcome was better in those who survived,⁸ while using UK in the treatment of IVH seems to reduce mortality and the risk of delayed hydrocephalus.^{11,12}

In our study the mortality rate was 47% for ICH treatment and there were no deaths in those with IVH.

Treatment of spontaneous ICH using fibrinolytic agents is an area that needs further experience, but we believe that although this method did not decrease the mortality rate significantly, it did improve outcome, decrease duration of hospitalization, and as a result diminish complications of prolonged coma and hospitalization.

Finally, we hope that in the future victims of spontaneous ICH will be rapidly referred to appropriate cen-

ters for rapid and simple removal of clots using this less invasive method.

REFERENCES

1. Bae HG, et al: Rapid expansion of hypertensive intracerebral hemorrhage. *Neurosurgery* 31 (1): 35-41, 1992.
2. Benes V, et al: Effect of intra-arterial tPA and urokinase on autologous arterial emboli in the cerebral circulation of rabbits. *Stroke* 21 (11): 1594-1600, 1990.
3. Brott T: Thrombolytic therapy for stroke. *Cerebrovasc Brain Metab Rev* 3(2): 91-113, 1991.
4. Fagan SC, et al: Brain attack, an indication for thrombolysis? *Ann Pharmacother* 26(1): 73-80, 1962.
5. Hamilton MG: Intracerebral hematomas, In: Carter P, Spetzler RE, (eds.), *Neurovascular Surgery*, New York: McGraw-Hill,

Treatment of ICH Using Urokinase

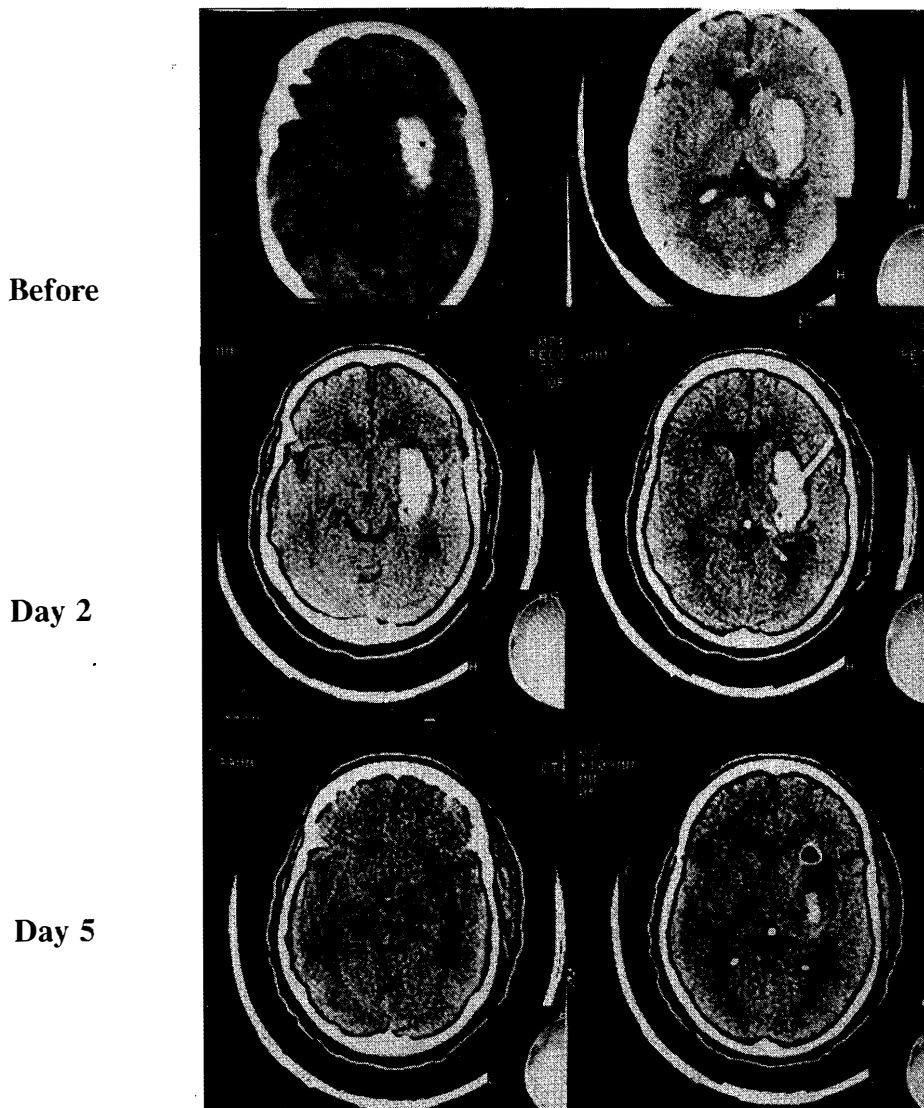


Fig. 2. CT findings in case 16 before and after urokinase infusion therapy.

pp. 477-496, 1994.

6. Kaufman HH: Spontaneous intraparenchymal brain hemorrhage, In: Wilkins RH, Rengachary SS, (eds.), *Neurosurgery*, New York: McGraw-Hill, pp. 2569-2585, 1996.

7. Kaufman HH: Intracerebral hematoma. *Neurosurgical Consultations* 4 (23): 1-6, 1993.

8. Kaufman HH: Stereotactic aspiration with fibrinolytic and mechanical assistance, In: Kaufman HH, (ed.), *Intracerebral Hematoma*. New York: Raven Press, pp. 181-185, 1992.

9. Proner J, et al: Ruptured AVM complicating thrombolytic therapy with tPA. *Arch Neurol* 74 (1): 105-6, 1990.

10. Shaffrey ME, et al: Nonoperative treatment of aneurysmal subarachnoid hemorrhage, In: Youmans JR, (ed.), *Neurological Surgery*, Philadelphia: Saunders, pp. 1264-71, 1996.

11. Shen PH, et al: Treatment of intraventricular hemorrhage using urokinase. *Neurol Med Chir* 30: 329-333, 1990.

12. Todo T: Treatment of severe intraventricular hemorrhage by intraventricular infusion of urokinase. *J Neurosurgery* 74: 81-86, 1991.