

## The relation of ST segment deviations in 12-lead conventional Electrocardiogram, right and posterior leads with the site of occlusion in acute inferior myocardial infarction

Shahrokh Karbalaie<sup>1</sup>, Kaveh Hosseini<sup>2</sup>, Ali Bozorgi<sup>3</sup>

Received: 8 January 2014

Accepted: 10 June 2014

Published: 23 September 2014

### Abstract

**Background:** In addition to diagnosing the acute myocardial infarction (MI), stratifying high-risk patients and proper treatment strategies are important issues in managing patients complaining of chest pain and suspecting MI. Many studies have been conducted to predict the occlusion site by interpreting the ST segment deviations in Electrocardiogram (ECG). Additional posterior and right precordial leads are suggested in literature to increase the sensitivity of prediction. The goal of this study was to determine the relation of ST segment changes in ECG (conventional 12 leads ECG besides right and posterior leads) with the site of occlusion within the vessel.

**Methods:** Retrospectively, from total 138 patients, 76 of them were analyzed as single vessel acute Inferior ST elevation Myocardial infarction (I-STEMI)-ST which 56 (74%) had Right Coronary Artery (RCA) occlusion [22(29.3%) proximal RCA, 24(32%) middle RCA and 10(13.3%) distal occlusion of RCA], 19(25%) had Left Circumflex artery (LCx) lesion and one had middle Left Anterior Descending (LAD) artery occlusion. On admission ECGs and coronary artery intervention films, were reported within maximum time of 6 days in hospital stay, and re-evaluated by two cardiologists.

**Results:** Fiol's algorithm was 93% sensitive and 50% specific for predicting RCA occlusion. The ST elevation in lead III was associated with RCA stenosis (Odds Ratio (OR): 12, Confidence Interval (CI): 2.2-68.9), the association between ST elevation in lead II with LCx involvement was not significant. The V4R was a good marker for RV involvement on-admission, (OR=8, CI: 1.6-37.5). Sum of ST deviation in posterior leads (V7 to V9)  $\geq 2$ mm had positive and significant relation to LCx stenosis (OR=4, CI: 1.3-14).

**Conclusion:** Benefit of adding posterior and right leads to 12-lead ECG is shown to be noteworthy in present and prior studies, in identifying LCx stenosis and poor prognosis involvement.

**Keywords:** ECG, Coronary Angiography.

**Cite this article as:** Karbalaia Sh, Hosseini K, Bozorgi A. The relation of ST segment deviations in 12-lead conventional Electrocardiogram, right and posterior leads with the site of occlusion in acute inferior myocardial infarction. *Med J Islam Repub Iran* 2014 (23 September). Vol. 28:103.

### Introduction

In ST-elevation myocardial infarction (STEMI) the time of blood flow re-establishment in infarct area is crucial. In addition to fast diagnosis, immediate and accurate stratification of high-risk patients is also important in this situation. The 12-lead electrocardiogram (ECG) in emergency rooms is the most feasible and valuable test in patients with acute chest pain for diagnostic and therapeutic measures. Stenosis

of the proximal portion of RCA and RV involvement may cause RV failure and poor prognosis (1).

Considerable numbers of patients with highly suspected MI have normal on-admission 12-lead ECG, hence serial ECGs and also additional leads (right and posterior leads) may help physicians to deal with such cases (2). Many studies in this field suggested stepwise algorithms and criteria to predict the culprit artery, like Fiol et

1. MD, Assistant Professor of Medicine, Department of Cardiology, Sina Hospital, Tehran University of Medical Sciences, Tehran, Iran. Saleh6948@yahoo.com

2. Medical Intern and Master of public Health at Tehran University of Medical Sciences, Tehran, Iran. Kaveh\_hosseini130@yahoo.com

3. (Corresponding author) MD, Assistant Professor of Cardiology, Tehran Heart Center, Tehran University of Medical Sciences, Tehran, Iran. Alibozorgi.md@gmail.com

aland Tierala et al (3,4). In this study we focused on Fiol's algorithm and some other pre-specified criteria for prediction of occluded vessel in single vessel inferior STEMI. In addition the relation of culprit lesion with ST segment deviation in posterior and right precordial leads were also analyzed in terms of odds ratio and confidence intervals.

### Methods

In this retrospective study, of a total of 138 studied patients, 25 had 3-vessel disease and 37 had two occluded arteries. The remaining 76 patients were diagnosed with single vessel acute I-STEMI, in which 56 (74%) had right coronary artery (RCA) occlusion [22 (29.3%) proximal RCA, 24 (32%) middle RCA, and 10 (13.3%) distal occlusion of RCA], 19(25%) left circumflex artery (LCx) lesion and one middle left anterior descending (LAD) artery occlusion. Normal coronary was detected in one patient, which excluded based on the first decision of authors and the suggestion of similar studies. We enrolled 76 consecutive patients with acute single vessel myocardial infarction who admitted in Tehran Heart Center (THC) from 2007 to 2012 and underwent clinically indicated percutaneous coronary interventions. All of them fulfilled following criteria: single-vessel occlusion, no sign of left bundle branch block and left ventricular hypertrophy in ECG, no history of coronary artery bypass graft and myocardial infarction. In Emergency Department (ED) of THC we routinely record 16-lead ECG (conventional 12-lead ECG plus

right (V4R) and posterior (V7 to V9) leads). All ECG records and angiographic films were read and reported separately by two expert cardiologists without being aware of the patients' condition. Quantitative analysis of ST segment deviation was done. ST changes were measured at 80 ms from J points with the TP segment fallen into the iso-electric line of the ECG. The ST deviations < 0.5mm in frontal leads and < 1 mm in precordial leads were regarded as isoelectric. Significant stenosis was considered when > 70% narrowing of luminal was present. At the time of discrepancy, we re-evaluated the records at the presence of both cardiologists. The on-admission ECG was considered as the first ECG to interpret. The maximum time between symptoms onset and coronary angiography in our patients was less than a week of hospitalization.

### Statistical analysis

All statistical analyses were performed using SPSS 13 (SPSS Inc. Chicago, Illinois). Categorical data were analyzed in terms of frequency and continuous data presented as means  $\pm$  SD. Dichotomous variables were compared by chi-square test and Independent samples T-test used to compare means of continuous variables (age in sex groups). In order to explain the relation of variables, Odds ratios and confidence intervals were also calculated.

### Results

The mean age of the patients was  $56 \pm 10$  (maximum: 79, minimum: 32). Female pa-

Table1. Infarct-related artery based on angiography reports in I-STEMI (n=76)

Culprit artery	Distribution (% of the total sample size)
Right coronary artery	56(74.7%)
Proximal*	22(29.3%)
Middle	24(32%)
Distal**	10(13.3%)
Left circumflex artery	19(25.3%)
Proximal***	7(9.3%)
Non proximal	11(14.6%)
Obtuse marginal branch	1(1.3%)
Left anterior descending artery	1(1.3%)
Mid portion	1(1.3%)

\*Prior to the origin of the acute marginal artery, \*\*Between acute marginal artery and the origin of the PDA, \*\*\* Prior to first obtusmarginatum (OM1)

tients constituted 20% of the sample size with the mean age of  $62 \pm 9$  which was higher than male patients,  $55 \pm 10$ . The age difference was significant in sex groups ( $p=0.023$ ). The youngest patient was a 32 year-old man and the oldest a 79 year-old man. Angiographic data of all patients are displayed in Table 1. Univariate analysis of some traditional criteria, right and posterior criteria are shown in Table 2. We could not reach a significant multivariate regression model to predict the site of stenosis, due to lack of linearity of the effects for some criteria.

We analyzed each step of Fiol's algorithm in terms of specificity and sensitivity. Fiol's algorithm analysis is shown in Fig 1 and Table 3.

In step one, ST depression in lead I, 38 patients were truly predicted as RCA. The remaining eight had LCx occlusion that were not truly diagnosed based on this step. The ST was elevated in four patients in lead I which was associated with LCx occlusion in 3(75%). The other 26 patients, including one with LAD occlusion, with the isoelectric ST in lead I was assessed in the second step. Before analyzing through the second step of Fiol's algorithm, the site of the culprit artery in 41 of 75 patients was defined. In the second step nine patients had ST ele-

vation  $II \geq III$  and in five of them LCx was the infarct-related artery; three had RCA as culprit lesion and one occlusion of mid LAD. According to the last step 16 patients had RCA occlusion and one LCx occlusion. Of these, 14 were truly predicted as RCA but the remained two were in fact LCx. The patient with correctly diagnosed LCx occlusion (based on this step) had proximal LCx occlusion. The overall results of these 3 steps and each step of the algorithm are shown in Table 3 and figure 1 respectively. We had 22 patients with PRCA lesion (17 with aVL depression  $\geq 1$ ) and 34 patients with non-proximal occlusion of RCA (26 with aVL depression  $\geq 1$ ). Sensitivity and specificity of aVL depression  $\geq 1$  mm were 77% and 31% respectively for PRCA prediction ( $p$  value=0.41). This criterion was not able to define proximal vs. distal in RCA and only significant to differentiate RCA from LCx lesion ( $p$  value=0.017) with sensitivity and specificity of 77% and 63% respectively.

Isoelectric or elevated V1 was another criterion, which was suggested by Turhan (5) for PRCA prediction. Although 86% of patients with PRCA occlusion had this criterion, in our analysis it was not statistically associated with the site of occlusion (proximal, middle and distal) within the RCA ( $p$

Table 2. Univariate analysis of factors associated with the site of occlusion (RCA vs. LCx)

Variable	Site of occlusion	Odds ratio	95% Confidence interval
ST elevation in lead III $\geq 1$ mm	RCA	12	2.2-68.9
ST elevation in lead II $\geq 1$ mm	LCx	0.5	0.16-1.58
ST elevation $II \geq III$	LCx	20	3.6-105.3
ST elevation $\geq 1$ in V4R	Proximal RCA	8	1.6-37.5
Sum of ST deviation in posterior leads $\geq 2$ mm	LCx	4	1.3-14

Table 3. Sensitivity, specificity and predictive values of each step for Fiol's algorithms (n=76)

Fiol's algorithm steps	Culprit Artery	Sen.	Spec.	PPV	NPV
Step 1: a) ST depression In lead I	RCA	68%	60%	83%	40%
b) ST elevation in lead I	LCx	16%	98%	75%	78%
Step2: ST elevation $II \geq III$	LCx	63%	78%	56%	82%
Step3: Sum of depressions of V1 to V3 divided by sum of elevations of inferior leads $\leq 1$	RCA	100%	33%	88%	100%
All steps together:	RCA	93%	50%	83%	56%
	LCx	47%	84%	50%	83%

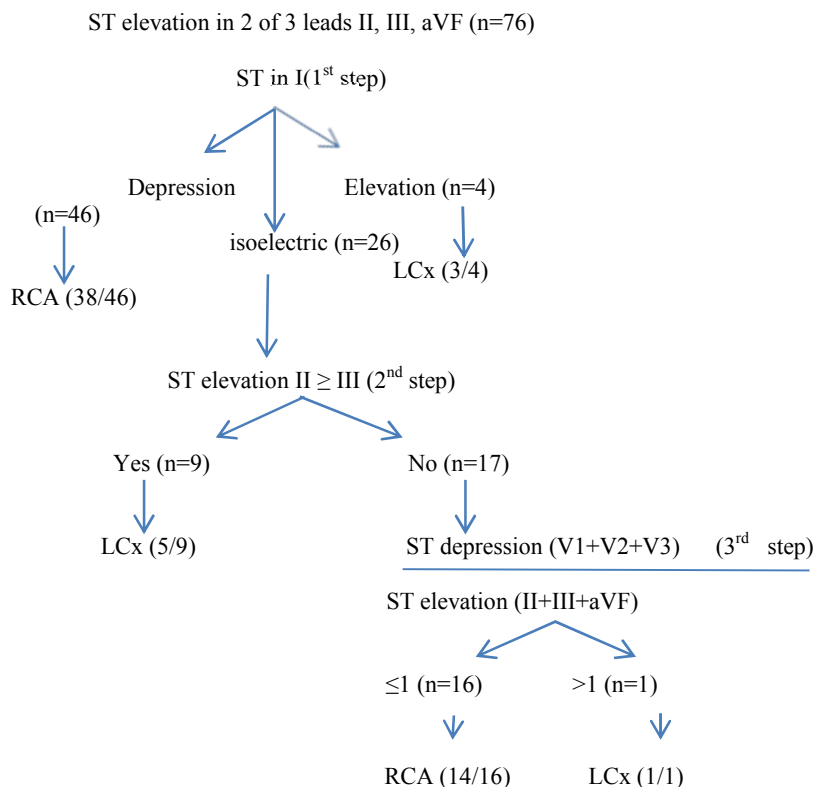


Fig.1. Fio's algorithm

value=0.116).

In this study, prediction of LCx occlusion with lead V5-V6 was shown to be useful. Sum of ST-elevation in lead V5 and V6  $\geq$  2.5mm had 63% and 91% sensitivity and specificity respectively for LCx prediction (p value=0.044). Both sensitivity and specificity of this criterion were higher than those of Tierala and Fiol for LCx lesions.

### Discussion

In clinical and therapeutic decision-making, the initial steps are to determine the culprit vessel and the location of the occlusion within the vessel (6). Many criteria and algorithms were proposed in recent studies but their specificity and sensitivity are limited. Small sample size and confounding multi-vessel involvement preclude clinicians from precise conclusion. Recording right and posterior leads besides conventional 12-lead ECG could be useful.

Multi vessel involvement (two or three vessel disease) is not discussed in this study however the authors believe that it would affect the results very much. In previous study by Tierala et al (4) they included multi vessel involvement in addition to left

main stenosis, which resulted in high degree accuracy of prediction (from 12 lead ECG to angiographic results).

An important concept in the literature is the "mirror effect" or the reciprocal deviations (7). For instance, in RCA occlusion, the injury vector is toward the right side and results in ST depression in leads I and aVL. Hira et al (7) suggested a new criterion based on "mirror effect": ST-T pattern in lead aVL would be the mirror of lead III, if the culprit artery is RCA or distal LCx. Hence lack of this mirror pattern is suggestive for proximal LCx. the magnitude of aVR depression was another criterion based on reciprocal concept that literature (8). As lead aVR was placed in more opposite direction than aVL, in cases of LCx occlusion, its magnitude of deviation had better chance distinguishing LCx as infarct related artery (3-8). Although it was not significant in our study, we recommend the use of this concept in future studies with a larger sample size.

The reported sensitivity and specificity of Fiol et al (3) study, for RCA prediction, were 96% and 38% respectively (reported by Tierala). Moreover Fiol et al did not in-

clude inferior STEMI due to apical MI and LAD occlusion in their algorithm. One of our cases had stenosis in mid portion of LAD that resulted in apical MI.

Tierala's algorithm (4) in previous study by Hosseini et al (9) had 86% sensitivity and 50% specificity which were both lower than Fiol's algorithm study.

Wong et al (8) suggested the ratio of T-wave amplitude in lead III to that of lead II was more than 1, as a criterion of RCA vs. LCx. The 80% sensitive and 43% specific for RCA detection in our analysis was not significant ( $p=0.062$ ). Although it is easier to measure T-wave amplitude than ST elevation in leads III and II, but it was not a good substitute for data analysis. It may become significant in larger sample sizes. In addition, invert or negative-biphasic T-wave in their study was related to the prediction for RCA, but this was not significant in our study ( $p=0.4$ ).

Kanei et al (10) proposed aVR depression  $\geq 1$ mm for prediction of LCx. Nevertheless we had 14 patients with aVR depression  $\geq 1$ mm in which eight had RCA occlusion; and the remaining six, LCx was the culprit artery. Sensitivity and specificity of this criterion for LCx prediction were 32% and 86% respectively ( $p=0.094$ ).

To define the proximal occlusion of RCA, Fiol et al (6) proposed aVL depression  $\geq 1$ mm as a criterion.

The ST segment elevation in V4R (occluded before right ventricular branch) was useful for identifying occlusion of RCA. Occlusion of proximal-RCA in right dominant hearts, led to ST elevation of right precordial leads due to RV involvement. However, in such dominant RCA infarction of posterior wall could reciprocally depress ST segment in right precordial leads. These two vectors can attenuate their force (11). Hence, the association between RV involvement and the site of RCA stenosis could be a challenging phenomenon.

Although LCx obstruction and consequent MI could be missed by on-admission ECG but LCX can supplies the posterolateral wall and posterior part of the infero-

posterior septum. Additionally the LCX can give rise to PDA in a proportion of patients (8) thus, recording posterior leads will help identifying STEMI due to LCx stenosis. The ST segment elevation in posterior leads suggested to be related to LCx occlusion (11). In this study we also found positive relationship between LCx stenosis and ST deviation in posterior leads.

Actually, beat-to-beat variations in ECG can influence the reported magnitude by cardiologists. To deal with this issue we calculated the mean for the ST elevation in three consecutive beats.

In conclusion, adding other right and posterior leads to the conventional 12-lead ECG will improve decisions in ED, and also help taking faster therapeutic measures in high risk patients.

### Conclusion

Benefit of adding posterior and right leads to 12-lead ECG is shown to be noteworthy in present study. Prediction of the site of occlusion in LCx and also RV involvement will be more accurate when posterior and right precordial leads were taken into consideration.

### Acknowledgements

The authors thank Mehran Mahmoudian MD, for providing well-defined data-base, Soheil Saadat MD, for epidemiologic consult. Our gratitude also goes out to The Research division and data base registry section of Tehran Heart Center.

### References

1. Braat SH, De Zwaan C, Brugada P, Coenegracht JM, Wellens HJ. Right ventricular involvement with acute inferior wall myocardial infarction identifies high risk of developing atrioventricular nodal conduction disturbances. *Am Heart J* 1984; 107:1183-1187.
2. Aqel RA, Hage FG, Ellipedi P, Blackmon L, McElderry HT, Kay GN, et al. Usefulness of three posterior chest leads for the detection of posterior wall acute myocardial infarction. *Am J Cardiol* 2009 Jan 15;103(2):159-64.
3. Fiol M, Cygankiewicz I, Carrillo A, Bayes-Genis A, Santoyo O, Gomez A, et al. Value of electrocardiographic algorithm based on 'ups and downs' of ST in assessment of a culprit artery in

evolving inferior wall acute myocardial infarction *Am J Cardiol.* 2004; 94:709–714.

4. Ilkka T, Kjell C.N, Sclarovsky S, Syväne M, Eskola M. Predicting the culprit artery in acute ST-elevation myocardial infarction and introducing a new algorithm to predict infarct-related artery in inferior ST-elevation myocardial infarction: correlation with coronary anatomy in the HAAMU Trial. *J Electrocardiol* 2009; 42:120–127.

5. Turhan H, Yilmaz MB, Yetkin E. Diagnostic value of aVL derivation for right ventricular involvement in patients with acute myocardial infarction. *Ann NoninvasivElectrocardiol* 2003; 8:185–189.

6. Fiol M, Carrillo A, Cygankiewicz I, Ayestarán J, Caldés O, Peral V, et al. New criteria based on ST changes in 12-lead surface ECG to detect proximal versus distal right coronary artery occlusion in a case of acuteinferoposterior myocardial infarction. *Ann Noninvasive Electrocardiol.* 2004 Oct; 9(4):383-8.

7. Hira RS, Wilson JM, Birnbaum Y. Introducing a new algorithm in inferior ST-segment elevation myocardial infarction to predict the culprit artery

and distinguish proximal versus distal lesions. *Coronary Artery Disease* 2011, 22:165–17013.

8. Wong TW, Huang XH, Liu W, Ng K, Ng KS. New electrocardiographic criteria for identifying the culprit artery in inferior wall acute myocardial infarction-usefulness of T-wave amplitude ratio in leads II/III and T-wave polarity in the right V5 lead. *Am J Cardiol.* 2004 Nov 1;94(9): 1168-71.

9. Hosseini K, Bozorgi A, Karbalaie Sh. Predicting the Culprit Lesion in Acute Inferior ST-Elevation Myocardial Infarction Based on Wellens' Criteria and Tiera's Algorithm. *Thrita.* 2014 March; 3(1): e15607.

10. Vales L, Kanei Y, Schweitzer P. Electrocardiographic predictors of culprit artery in acute inferior ST elevation myocardial infarction. *J of Electrocardiol* 2011; 44 (2011) 31–35.

11. Kosuge M, Kimura K, Ishikawa T, Hongo Y, Shigemasa T, Sugiyama M, et al. Implications of the absence of ST-segment elevation in lead V4R in patients who have inferior wall acute myocardial infarction with right ventricular involvement. *Clin-Cardiol.* 2001 Mar;24(3):225-30.