

Comparison of one-stage free gracilis muscle flap with two-stage method in chronic facial palsy*

H. Karimi, MD.¹, M. Ashayeri, MD.², N. Boddouhi, MD.³, J. Ghaffari,⁴ and, F. Hoseini,⁵

Department of Plastic Surgery, Hazrat-e-Fatemeh Hospital, Iran University of Medical Sciences, Tehran, Iran.

Abstract

Background: Rehabilitation of facial paralysis is one of the greatest challenges faced by reconstructive surgeons today. The traditional method for treatment of patients with facial palsy is the two-stage free gracilis flap which has a long latency period of between the two stages of surgery.

Methods: In this paper, we prospectively compared the results of the one-stage gracilis flap method with the two - stage technique.

Results: Out of 41 patients with facial palsy referred to Hazrat-e-Fatemeh Hospital 31 were selected from whom 22 underwent two- stage and 9 one-stage method treatment. The two groups were identical according to age, sex, intensity of illness, duration, and chronicity of illness. Mean duration of follow up was 37 months. There was no significant relation between the two groups regarding the symmetry of face in repose, smiling, whistling and nasolabial folds. Frequency of complications was equal in both groups. The postoperative surgeons and patients' satisfaction were equal in both groups. There was no significant difference between the mean excursion of muscle flap in one-stage (9.8 mm) and two-stage groups (8.9 mm). The ratio of contraction of the affected side compared to the normal side was similar in both groups. The mean time of the initial contraction of the muscle flap in the one-stage group (5.5 months) had a significant difference ($P=0.001$) with the two-stage one (6.5 months). The study revealed a highly significant difference ($P=0.0001$) between the mean waiting period from the first operation to the beginning of muscle contraction in one-stage (5.5 months) and two-stage groups (17.1 months).

Conclusion: It seems that the results and complication of the two methods are the same, but the one-stage method requires less time for facial reanimation, and is cost-effective because it saves time and decreases hospitalization costs.

Keywords: one-stage method, facial palsy, free flap, gracilis.

Introduction

Paralysis of the facial nerve can be due to a number of etiologies. Nonetheless, the affection possibility of facial nerves resulting in facial paralysis is high because of the high length beginning from the brain stem to the face. The

goal of treatment of facial paralysis is to obtain normal appearance at rest, symmetry in smiling, whistling and voluntary movements, and symmetry in emotional facial expressions [1]. In addition, it is necessary to have minimal derangement in donor site function after the treatment.

*This paper has been presented in the First International Congress of Rhinology, Otolaryngology and Skull-base Surgery; Athens, Sep. 2006.

1. **Corresponding author**, Associate Professor of Plastic Surgery, Faculty of Medicine, Iran University of Medical Sciences. Hazrat-e-Fatemeh Hospital, 21st Alley, Asad Abadi Ave. Tehran, Iran. P.O.Box : 19395-4949. Tel : + 98 21 88883924, e-mail: h.karimi@iums.ac.ir

2. Associate Professor of Plastic Surgery, Faculty of Medicine, Iran University of Medical Sciences.

3. Assistant Professor of Plastic Surgery, Iran University of Medical Sciences.

4&5. Statistition, Iran University of Medical Sciences.

There have been a variety of methods used in the treatment of facial palsy such as direct nerve anastomosis, autogenous nerve graft, and free muscle and nerve flap, so far [2-10]. In chronic facial palsy, facial muscles are atrophied and cannot be effective in facial movements; therefore, the free muscle flap is needed for treatment of such cases [11]. The standard and classic method in treatment of patients with chronic facial palsy has been the two-stage free gracilis flap for the last 20 years [1] (Fig. 1).

Along with Hassan and Kumar's [13,14] report in 2002, a new method of one-stage free gracilis flap was introduced by the authors [12] (Figs. 2&3). Using this cost-benefit method, comparing to the two-stage one, the waiting time decreases efficiently. In this study, therefore, the one-stage method is compared with the two-stage in different phases including face symmetry, complications, and patients and surgeons satisfaction before and after surgery.

Methods

41 patients with chronic facial palsy who sought medical attention were examined in Hazrat-e-Fatemeh Hospital from 1999 to 2005. Afterwards, 31 candidates for free gracilis flap were selected and randomly divided into two groups. The first group including 9 patients underwent one-stage method surgery and 22 patients underwent the two-stage technique. A special questionnaire was filled out for every patient and symmetry of the face and nasolabial folds were examined at rest, whistling, smiling and full contraction of both sides of the face pre- and postoperatively. Consequently, close-up photographs were taken from patients. Lengths of muscle excursion on both sides were measured in several sessions. The time of first contraction of the muscle flap and the waiting period from first surgery to reanimation of the face were noted. Finally, the patients and surgeons' satisfaction were asked after the treatment. According to the study, the mean follow up of patients was 37.4 months. Therefore, it is

assumed that the full strength of muscles had been achieved. One of the authors made all the measurements for the accuracy and precision consideration. The collected data was analyzed by SPSS software.

Operative technique

Patients were placed supine under general anesthesia, with two teams of surgeons operating simultaneously.

The first team of surgeons dissected the gracilis muscle including its vascular and nerve pedicle and harvested a maximum of 13cm of nerve pedicle from the obturator nerve branch. At the same time, the second team dissected the face using four incisions. The first incision was made in the preauricular area and the second and third in nasolabial folds of both paralyzed and intact sides. The fourth incision was in the lower edge of the mandible lateral to the chin for dissection of the facial vessels. Then, a branch of the buccal nerve in the normal side was found and released. About 25g of the gracilis muscle (7 to 10 cm in length and 2 to 4 cm in width) was harvested.

A pocket was made in the paralyzed side from the zygoma and preauricular area to the lateral commissure of the lip. The flap was inserted in the pocket in a way that the distal part of the muscle is sutured to the fascia in the zygoma and preauricular area. The proximal end was divided into three equal leaves and sutured to the orbicularis muscle in the upper and lower lip and lateral commissure. The flap was placed upside down and rotated in a way that the inner surface of the flap was placed in the inner aspect of skin and subcutaneous tissue, and the outer surface of muscle over the deeper layers or facial muscles (SMAS).

Sex	One-stage group	Two-stage group	Total
Male	5	12	17
Female	4	10	14
Total	9	22	31

Table 1. Sex distribution in the two groups.

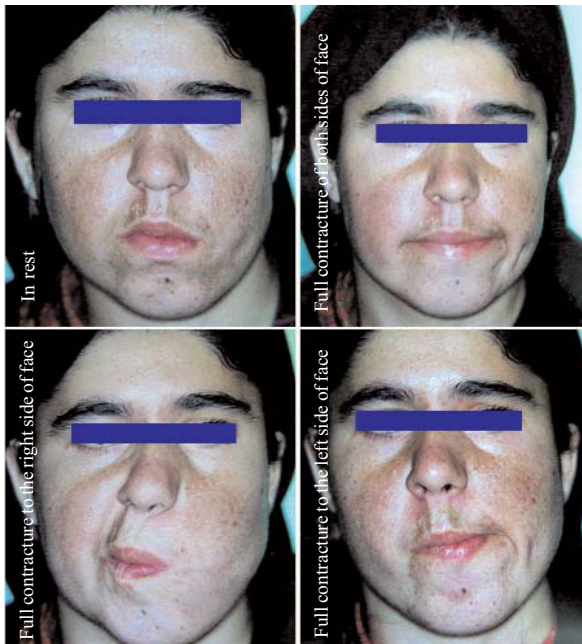
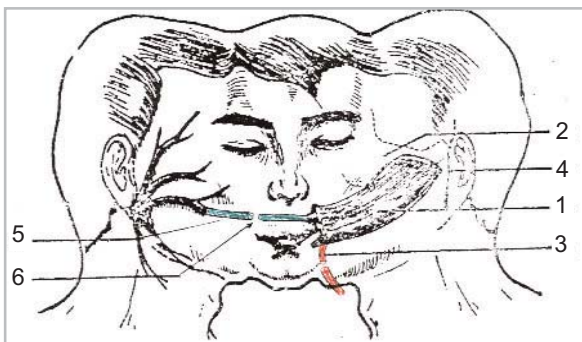


Fig. 1. A 25 year old girl with chronic complete left facial palsy who has been operated with two-stage method, 58 months after operation.

In the current procedure, contrary to the traditional method, the muscle flap is placed in a reversed and rotated position (Fig. 2). The vascular pedicle is anastomosed to the facial vessels and the neural pedicle to the buccal branch of the facial nerve on the intact side through a tunnel in the upper lip. Excursion of muscle flaps were compared in the two methods with the intact side.



1. Gracilis muscle flap.
2. Zygomatic arch.
3. Vascular pedicle anastomosed to the facial vessels.
4. Pretragal incision.
5. Buccal branch of intact side.
6. Neural anastomosis.

Fig. 2. Schematic representation of one-stage free gracilis flap to the face.

Results

Out of 31 patients, 17 were male and 14 female (Table 1). 9 patients underwent one-stage and 22 two-stage method treatment. 20 patients had right-side chronic facial palsy, and 11 left side involvement. 7 patients with right-side and 2 with left-side chronic facial palsy underwent one stage method surgery. The etiology of facial paralysis is shown in Table 2. One patient had central paralysis and 30 others had peripheral paralysis. The mean follow up period was 37.4 months. There was no significant difference ($P=0.89$) in age and sex between the two groups (Table 1) and between the mean of disease duration in the first group (28.5 months) and the second group (30.9 months). In addition, there was no significant difference between mean age in the first group (24.5 years) and the second group (28.5 years). Therefore, the two groups were considered identical or

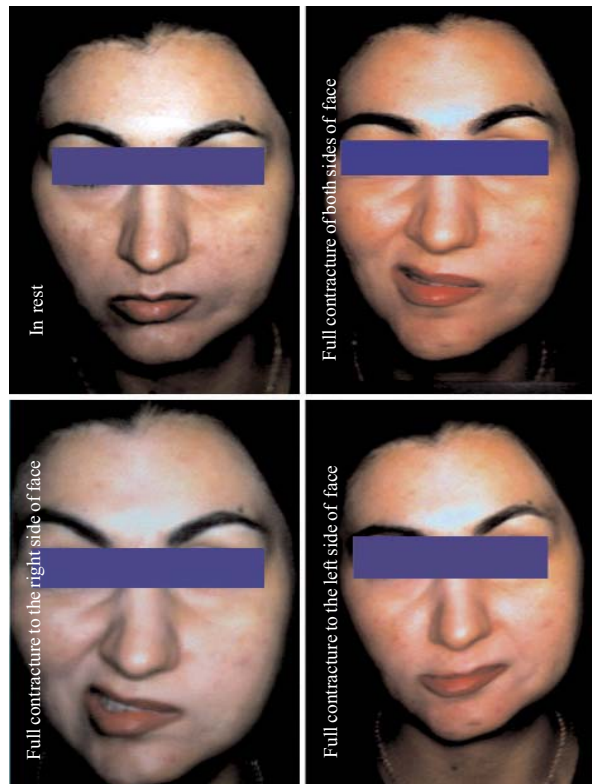


Fig. 3. A 32-year-old woman with chronic complete left facial palsy with one-stage method repair after 39 months.

Trauma	3	9.67%
Congenital	4	12.9%
Surgical	4	12.9%
Fever	6	19.35%
Seizure	10	32.25 %
Other	4	12.9%

Table 2. Etiology of facial paralysis.

similar.

After treatment patients were examined in one or several sessions and related photographs were taken (Figs. 4,5,6).

According to Tables 3, 4 and 5, there was no significant difference between the symmetry of examined faces at rest after treatment (P=0.13) as well as of faces at smiling (P=0.38) and with whistling (P=1).

	Symmetric		Not symmetric	
One-stage	8	100%	0	0%
Two-stage	11	68.8%	5	31.3%

Table 3. Symmetry of face at rest in the two groups.

There was no difference in facial fullness on the treated side and in donor site scars between the two groups either. In the second group, half of the patients felt numbness in the sural nerve donor site after one year. 29% of patients had scars in the recipient area, but no difference was detected between the two groups.

	Symmetric		Not symmetric	
One-stage	8	88.9%	1	11.1%
Two-stage	12	70.6%	5	29.4%

Table 4. Symmetry of the face in smiling in the two groups.

There was no complication in function of thigh adductor muscles. The surgeons' satisfaction depending on the length of muscle excursion is as follows (normally, the excursion of zygomaticus major is 15-20mm):

Low: muscle excursion < 3mm.

Moderate: muscle excursion between 3- 9mm.

Good: muscle excursion between 10-15mm.

	Symmetric		Not symmetric	
One-stage	7	77.8%	2	22.2%
Two-stage	13	76.5%	4	23.5%

Table 5. Symmetry of face in repose in the two groups.

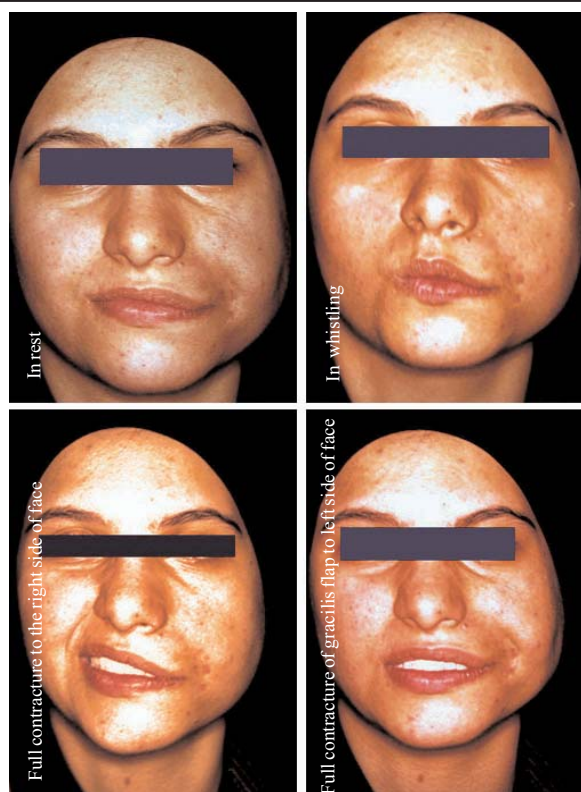

Fig. 4. A 26-year-old woman 32 months after operation.

Excellent: muscle excursion between 16-20mm.

Tables 6 and 7 show that there is no significant difference among the surgeons (P=0.41), as well as patient satisfaction (P=0.41) in the two groups postoperatively. The mean length of muscle excursion on the affected side was 9.8mm in the one-stage group and 8.9mm in the second group with no significant difference (P=0.65) between them. Because of the different length of muscle excursion on normal sides, we used the ratio of muscle excursion length of the affected side to the normal side of the face (in percent):

$$\text{Ratio} = (\text{muscle excursion length of affected side} / \text{muscle excursion length of normal side}) \times 100$$

	Symmetric		Not symmetric	
One-stage	7	77.8%	2	22.2%
Two-stage	13	76.5%	4	23.5%

Table 6. Frequency of surgeon's satisfaction of the results in the two groups.

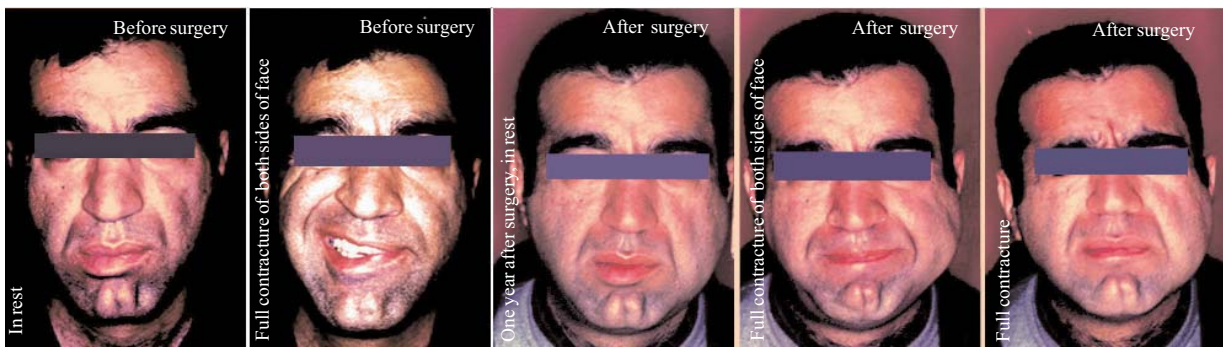


Fig. 5. A 29 year old man with left chronic facial palsy that has been operated with the one-stage method.

One-stage method: $81 \pm 21\%$

Two-stage method: $74 \pm 20\%$

However, no significant difference ($P=0.52$) was detected between the two groups. The mean time for the initial contraction after the muscle flap was 5.5 months in the one-stage group and 6.5 months in the two-stage group ($P=0.001$):

One-stage group: Mean \pm SD = 5.5 ± 0.55

Two stage group: Mean \pm SD = 6.5 ± 0.71

This could be because of the shortness of the nerve graft or the distance for axon buds to reach the muscle (Table 8). Total waiting time in the second group after two stages of surgery

was 17.1 and was 5.5 months for the one-stage group with a significant difference ($P=0.0001$) between the two (Table 9).

Conclusion

Seventy-five causes are often mentioned for facial palsy, but the most important ones are trauma, tumor, viral infections, obstetric trauma, radiotherapy, pregnancy and idiopathic causes (Bell's palsy) [15,16].

Ideally, the goal of treatment is to produce normal appearance in the face at rest, similarity in intentional movements, control of sphincters of the mouth, nose and eyes and similarity of

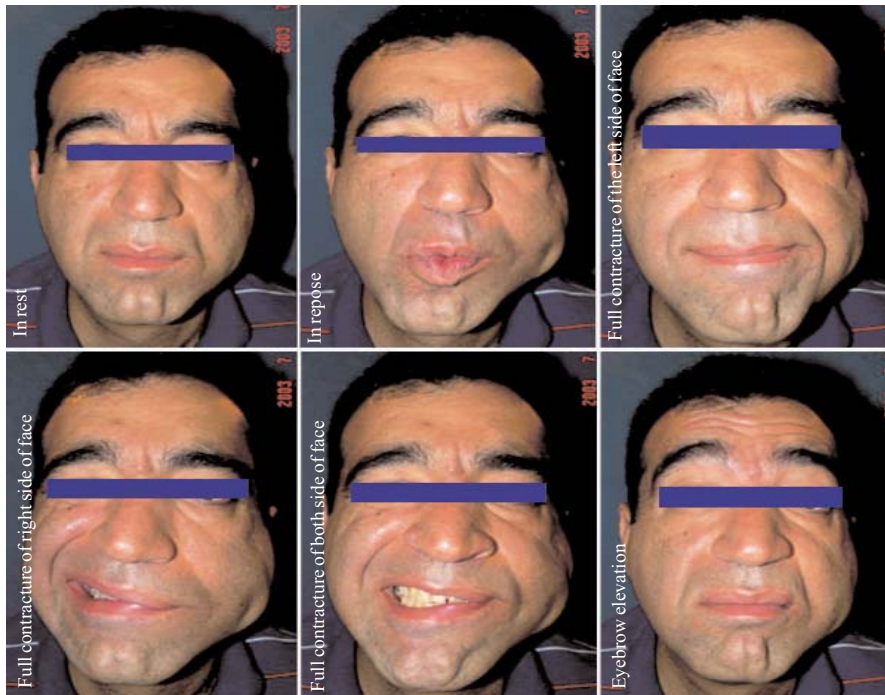


Fig. 6. The same man after three years.

	Low	Moderate	Good	Excellent
One-stage	1 (11.1 %)	1 (11.1 %)	5 (55.6 %)	2 (22.2 %)
Two-stage	2 (9 %)	7 (32 %)	12 (54.5 %)	1 (4.5 %)

Table 7. Frequency of patients' satisfaction of the results in the two groups.

emotional expressions. It is obvious that none of the available methods can meet all of these goals but most surgeons prefer dynamic methods to static ones. In chronic facial palsy, the muscle is atrophied and a nerve graft cannot solve the problem, therefore, a muscle flap is the choice. The best muscle for the flap should have close similarity with the zygomaticus major muscle and should have four characteristics including muscle excursion length equal to the normal side, good and reliable vascular and nerve pedicle, no functional deficit in donor site, and, for a two-team simultaneous operation, a distant donor site.

For production of a relatively normal smile, the function of the zygomaticus muscle should be reproduced. It has a 50 millimeters length and maximum length of its excursion is 15 to 20 mm [17,18]. The muscle flap should have good similarity of function with the zygomaticus major. The classic choice of treatment for facial palsy is the two-stage gracilis free flap. The results of this method were at most times good and sometimes excellent. O'Brien [19] reported 40 patients who underwent the two-stage method. He reported that 35 patients had good symmetry at rest and reasonable active movements in lips commissures and interestingly 19 patients had independent movements in both sides. Traditionally, surgeons have used different muscles flap for facial reanimation. Harri-

son [20], Harii [1], O'Brien [19], Manktelow [17,18] and Terzis [21,22] have used several methods to produce reanimation in the face. Nonetheless, In 2002, the authors along with Kumar and Hassan [14], introduced a novel one-stage method with gracilis muscle flap [12]. Kumar and Hassan [14] reported interesting results of their single stage flap with gracilis muscle and stated that the rehabilitation period with this method decreases more than 10 months, while they had only a few complications [13, 14].

In recent years, hence, there is a growing tendency for one-stage flaps. Wang et al in 1989 used the latissimus dorsi in one stage surgery [23]. In 2002, Wang et al [24] reported the one-stage free internal oblique flap for facial paralysis. In 2006, Sajjadian et al reported one-stage reanimation using rectus abdominis flap [25]. All of these reports favor the use of the one-stage flap but none of them compares the functional results of their methods with the two-stage method quantitatively.

In this study, we compared two groups of patients in results, complications, time of first contraction in flaps and patient and surgeon satisfaction. In the first group we had 9 cases and in the second 22 patients. The two groups were identical regarding age, sex, and duration of palsy. After the treatment, we examined the patients in one or several sessions. Symmetry of

	Number of patients	Mean	SD	SE
One-stage	9	5.5 mo	0.559	0.186
Two-stage	22	6.5 mo	0.715	0.156

Table 8. The mean time duration for first contraction in the two groups.

	Low	Moderate	Good	Excellent
One-stage	1 (11.1 %)	1 (11.1 %)	5 (55.6 %)	2 (22.2 %)
Two-stage	2 (9 %)	7 (32 %)	12 (54.5 %)	1 (4.5 %)

Table 9. The mean time duration of waiting period for first contraction in the two groups.

their faces did not show significant difference at rest, smiling, and whistling. The symmetry of nasolabial folds was not statistically different. Therefore, we concluded that the qualitative results were similar.

The mean excursion of muscle flaps was not quantitatively different in the two groups. The muscle excursions, also, were similar. Regarding the complications, the frequency of facial fullness on the affected side and frequency of remaining scars in donor or recipient sites were identical. There was no functional deficit in thigh adductor muscles. Half of the patients felt numbness in the sural nerve area in the second group, but it was not obviously seen in the first group.

According to the study, the surgeons' satisfaction as well as the patients' was the same in the two studied groups. The obtained ratio of muscle excursion for the affected side relative to the normal side showed similarity between the muscle excursion of both sides. Using this ratio, we can also perceive the similarity of the face in smiling or in repose. The ratios of excursion of the affected side to the normal side were identical in the two groups.

The study revealed that the mean time of first muscle contraction was 5.5 months in the one-stage group and 6.5 months in the two-stage group with a significant difference of $P=0.001$.

It is obvious that the probability of nerve bud regeneration through one neural anastomosis with a shorter distance is greater than two anastomoses and a longer nerve. It is also obvious that the gracilis flap has the same chance for innervations in both techniques, so, there is no risk for the flap in the one-stage technique. Thus, from the study, it could well be assumed that muscle contraction would begin earlier in the one-stage group relative to the two-stage group.

Terzis [26] reported the first muscle contraction time 6 to 48 weeks postoperatively for 100 treated patients. She stated that the full strength of contraction would be achieved after one

year; nevertheless, the time of first contraction in young females is shorter than others. The mean time of follow up in the study was 37 months, so it can be assumed that all of the patients had reached full strength of the muscle.

In the two-stage method, the period between the two procedures was about 9-12 months. Therefore, the waiting period for the patient is much longer. Average waiting period was 5.5 months for the one-stage group and 17.2 for the two-stage group which is highly significant ($P=0.0001$). The two-stage technique had much more expense, as the patients had to be examined frequently in the period between the two surgeries. Therefore, the one-stage method was more cost-effective.

In the study, it was shown that the two groups had similar clinical specifications and muscle function indices and results were comparable in the two groups. It is concluded that the one-stage technique takes much less time than the two-stage method, is cost-effective and thus offers the best option as the procedure of choice for the treatment of chronic facial palsy.

Acknowledgment

This study has been performed with the financial support of the Research Executive of Iran University of Medical Sciences.

References

1. Harri K, Ohmori K, Torii S, et al. Free gracilis muscle Transplantation with neurovascular anastomosis for the treatment of facial paralysis. *Plast Reconstr Surg* 1986; 57:133.
2. Bell C. On the nerves, giving an account of some experiments on their structure and functions, which leads to a new arrangement of the system, *Trans R Soc Lond* 1821; 3:398.
3. Drobnik M. Uber die Behandlung der kinderlamung mit Funktionstheilurg und Funktion Subertragung der Muskeln. *Dtsch Z Chir* 1896;43: 473.

4. Bunnell S. Suture of facial nerve within the temporal bone with a report of the first successful case. *Surg Gynecol Obstet* 1927;45:7.
5. Balance C, Duel AB. The operative treatment of facial palsy by the introduction of nerve grafts in to the fallopian canal and by other intratemporal methods. *Arch Otolaryngol* 1932; 15:1.
6. Bunnell S. Surgical repair of facial nerve. *Arch Otolaryngol* 1937; 25:235.
7. Lathrop FD. Affections of the facial nerve. *Technique Surg Clin North Am* 1956; 36:583.
8. Conley JJ. Facial nerve grafting in treatment of parotid gland tumors. *Arch Surg* 1955; 70:359.
9. Smith JW. A new technique of facial reanimation. In: Hueston YT, editor. *Transactions of the fifth international congress of plastic and reconstructive surgery*. Melbourne: Butherworths; 1971. pp.121-9.
10. Andrei H. Reconstruction of the face through cross face transplantation in facial paralysis. *Chir Plast* 1973; 2: 17.
11. Harri K. Microneurovascular free muscle transplantation for reanimation of facial paralysis. *Clin Plast Surg* 1979; 6: 361.
12. Ashayrni M, Karimi H. One-stage reversed and rotated gracilis muscle free flap technique for chronic facial palsy: a new technique. *Plast Reconstr Surg* 2002; 110(5): 1298-1302
13. Kumar PA, Hassan K M. Cross-face reanimation of the paralyzed face, with single stage microneurovascular gracilis transfer without nerve graft. *Br J Plast Surg* 1995; 48(2): 83.
14. Kumar PA, Hassan KM. Cross-face nerve graft with free-muscle transfer for reanimation of the paralyzed face: a comparative study of the single-stage and two-stage procedures. *Plast Reconstr Surg* 2002; 109(2): 451.
15. May M. Facial paralysis: differential diagnosis and indications for surgical therapy. *Clin Plast Surg* 1979; 6: 275.
16. May M. *The facial nerve*. New York: Thieme Medical Publishers; 1986. pp.56-60.
17. Manktelow R. Free muscle transplantation for facial paralysis. *Clin Plast Surg* 1984; 11:2-5.
18. Manktelow RT. Discussion of pectoralis minor vascularized muscle graft for the treatment of unilateral facial palsy. *Plast Reconstr Surg* 1985; 75:214.
19. O'Brien BM, Morrison W. *Facial palsy in reconstructive microsurgery*. London: Churchill Living Stone; 1987. pp.17-90.
20. Harrison DH. The pectoralis minor vascularized muscle graft for the treatment of unilateral facial palsy. *Plast Reconstr Surg* 1985;75:206.
21. Terzis J. *Microreconstruction of nerve injuries*. Philadelphia: W. B. Saunders Company; 1987. pp.10-22.
22. Terzis J, Manktelow R. [Unpublished Personal Communication] 1982;1-14.
23. Wang W, Chang T, Yang C, et al. Cross-face neurovascular latissimus dorsi for facial reanimation in one stage. *Chin J Microsurg* 1989; 12:155.
24. Wang W, Qi Z, Lin X, Hu Q, Dong J, Zhou L, Dai C. Neurovascular musculus obliquus internus abdominis flap free transfer for facial reanimation in a single stage. *Plast Reconstr Surg* 2002;110(6):1430-40.
25. Sajjadian A. One-stage reanimation of the paralyzed face using rectus abdominis neurovascular free flap. *Plast Reconstr Surg* 2006; 117:5,1553-1559.
26. Terzis JK, Noah ME. Analysis of 100 cases of free-muscle transplantation for facial paralysis. *Plast Reconstr Surg* 1997; 99 (7): 1905.