

## Mirrizi syndrome due to acalculous cholecystitis in a 13-year-old girl: a case report and literature review

M. Mozafar, MD.<sup>1</sup>, M. R. Kalantar Motamedi, MD, FACS.<sup>2</sup>,  
H. Khajouei Kermani, MD.<sup>3</sup>, and, M. Zeynalzadeh, MD.<sup>4</sup>

*Department of Surgery, Shohada-e-Tajrish Hospital, Shahid Beheshti University of Medical Sciences, Tehran, Iran.*

---

### Abstract

Acute inflammation of the gallbladder can occur without gallstones. Acalculous cholecystitis typically develops in critically ill patients in the intensive care unit. Patients on parenteral nutrition, with extensive burns, sepsis, major operations, multiple organ trauma or prolonged illness with multiple organ system failure are at risk for developing acalculous cholecystitis. The association of acalculous cholecystitis with Mirizzi syndrome is very unusual. Mirizzi syndrome, which is an unusual cause of obstructive jaundice, is most commonly caused by a stone impacted in Hartmann's pouch, exerting pressure over the common bile duct (CBD) with subsequent erosion into the CBD. The case we are presenting is a case of Mirizzi syndrome type-1 due to acalculous cholecystitis in a 13-year-old girl that presented with intermittent jaundice and RUQ abdominal pain and fever. Intraoperative finding showed Mirizzi syndrome type-1 without gallstones. The cause of jaundice was only pressure of the gallbladder on the CBD and cholecystectomy with intraoperative cholangiography was performed. At post operative follow-up, the patient became anicteric and all symptoms and signs disappeared.

**Keywords:** Acalculous cholecystitis, cholecystocholedochal fistula, Mirizzi syndrome, cholecystectomy.

---

### Introduction

Acute acalculous cholecystitis accounts for 5% to 11% of all patients with acute cholecystitis and approximately 1% to 2% of all patients undergoing cholecystectomy. Acute acalculous cholecystitis usually oc-

curs in critically ill patients, following trauma, burns, long term parenteral nutrition, and major nonbiliary operations such as aortic abdominal aneurysm repair.

The etiology of acute acalculous cholecystitis remains unclear, although cystic duct stenosis and ischemia have been most often implicated as causative factors. The disease often has a fulminant course and

---

1. Associate professor of general and vascular surgery, Shahid Beheshti Medical College, Tehran, Iran.

2. **Corresponding author:** Professor and Chairman of General and Vascular Surgery. Address: Shohad-e-Tajrish Hospital, Ghods Sq, Tehran, Iran. Tel: (+98 21) 22 71 80 01-14, Fax: (+98 21) 22 72 11 44, email: Houman.KK@gmail.com.

3&4. Residents of general surgery, Shahid Beheshti Medical College, Tehran, Iran.

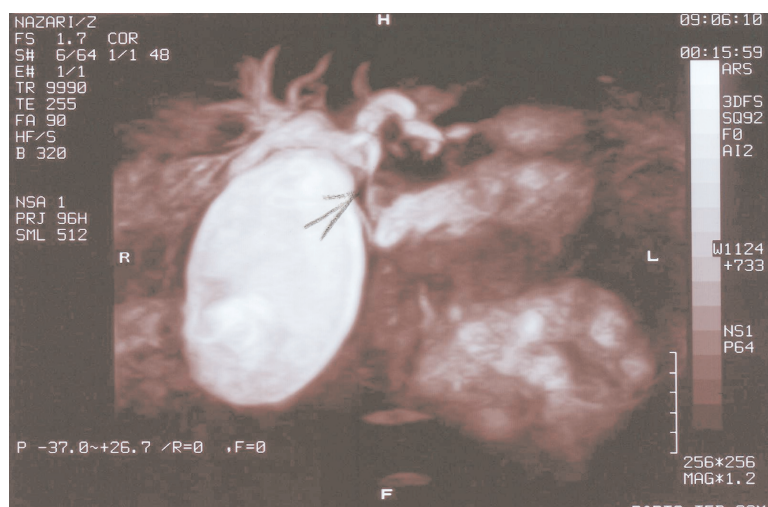


Fig. 1. MRCP before operation showed a narrowing near the common hepatic duct (CHD).

frequently progresses to gangrene, empyema, or perforation.

The symptoms and signs depend on the condition of the patient, but in the alert patient, they are similar to acute calculous cholecystitis, with right upper quadrant pain and tenderness, fever, and leukocytosis. Ultrasonography is usually the diagnostic test of choice. It can demonstrate the distended gallbladder with thickened wall, biliary sludge, pericholecystic fluid and the presence or absence of abscess formation [4,7].

Because these patients are usually ill, about 90% will improve with percutaneous cholecystostomy, however they do not cure completely, and other steps such as open cholecystectomy may be required [9,10].

Mirizzi syndrome is an unusual and specific cause of obstruction of the common hepatic duct or common bile duct due to contiguous inflammation in the gallbladder or the cystic duct or due to compression of the common hepatic duct (CHD) by an impacted large stone in the adjacent Hartmann's pouch or neck of the gallbladder. The stone may simply press on the bile duct, but more commonly, it ulcerates into

the duct, creating a cholecystocholedochal fistula. Patients present with obstructive jaundice and cholangiography shows narrowing of the bile duct at the porta hepatis, which can have the appearance of a cholangiocarcinoma. The true pathology is eventually identified at surgery [8] but the operation is often extremely difficult because of severe inflammation and fibrosis [1,2]. It is best not to excise the gallbladder, until the stone causing the obstruction is removed. If there is a large gap in the wall of the bile duct, a biliary enteric bypass is needed; 5 this can be achieved by anastomosing the neck of the gallbladder to a Roux-en-Y limb of jejunum. A reconstruction of the bile duct over a T-tube brought out through a separate stab incision is possible for very small defects. Therefore the treatment of cholecystocholedochal fistula depends on the Mirizzi syndrome type encountered [3, 6].

Type-1 is external compression of the common bile duct, without fistula formation. Consequently management is similar to that of gallbladder stone disease. Mirizzi types II through IV all represent cholecystocholedochal fistula. The gallbladder should not be removed and after the im-

WBC=6200/mm <sup>3</sup>	PT=13.1 sec	Bilirubin direct = 8.3 mg/dl
Hb=11 g/dl	PTT=40.9 sec	Alk-ph = 933 units/L
MCV=78.2 $\mu$ M	INR=1.02	AST = 97 units/L
Plat = 319 $\times 10^3$ /mm <sup>3</sup>	Gluc = 113 mg/dl	ALT = 93 units/L
Neut = 61%	BUN = 10 mg/dl	Ca = 9.2 mg/dL
Lym = 35%	Cr = 0.5 mg/dl	Na = 4.5 meq/L
Eos = 4%	Bilirubin total = 14 mg/dl	K = 3.6 meq/L

Table 1. Laboratory values of the studied case

pacted stone has been extracted, the CBD defect can be managed as above [2].

### Case report

The patient was a 13-year-old girl who developed right upper quadrant abdominal pain, nausea, vomiting, jaundice, pruritus and dark urine three weeks before hospitalization.

She had experienced similar attacks of jaundice and pruritus, intermittently, since four years ago, and she had used on antibiotics, hydroxyzine and cholestyramine on and off for the past four years. This time she had severe abdominal pain, which did not improve with antibiotics and analgesics. Previous ultrasound studies had revealed a dilated, large gallbladder with no stones and biliary tracts were normal. On examination, she had low grade fever, clinical jaundice, moderate tenderness in the right upper quadrant, but no peritoneal signs. There was no hepatosplenomegaly.

Ultrasound examination revealed a large and dilated gallbladder with thickened wall, and no stones. Intrahepatic ducts were dilated, and the CBD was normal.

MRCP showed an enlarged gallbladder with dramatic size, and intrahepatic bile ducts were markedly dilated as well as the proximal portion of CHD. There was short segment narrowing (11 mm) of the CBD near the common hepatic duct (Fig. 1).

The patient underwent laparotomy with a Kocher incision. The gallbladder was

very large, with thickened wall and severe inflammation and a gangrenous patch on the body.

The gallbladder was intrahepatic causing pressure over the common hepatic duct (CHD). After the dilated gallbladder was drained an intraoperative cholangiography was performed by injecting dye into the gallbladder which showed that intrahepatic ducts are dilated and the CBD has a narrowing just near the CHD, and there was normal passage of contrast into the duode-

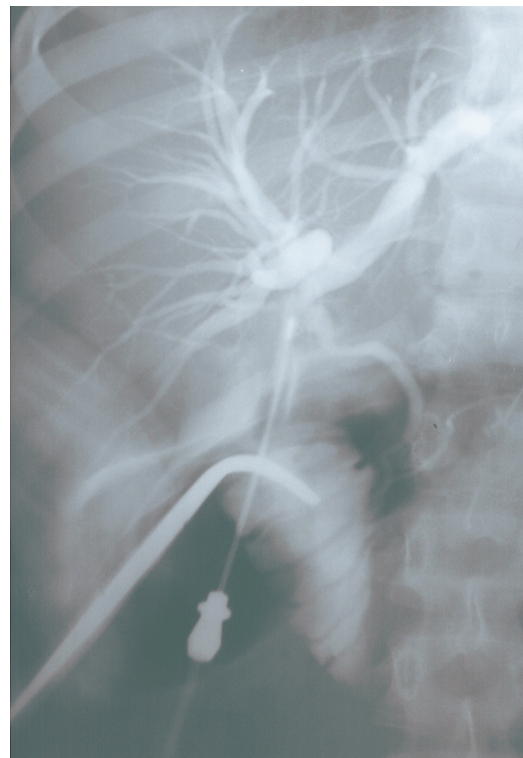


Fig. 2. Intraoperative cholangiography after cholecystectomy showed normal passage of contrast in the duodenum.

num. There were no stones in the CBD. Thus, a cholecystectomy was performed and particular attention was paid to the dissection between the gallbladder and CBD. After cholecystectomy, there was no fistula and control cholangiography through the cystic duct showed normal passage of contrast to intrahepatic and extrahepatic ducts and into the duodenum (Fig. 2).

Three days after surgery, liver function tests rapidly improved. Elevated serum bilirubin and liver function tests continually improved, and one month after surgery, the patient was well with normal liver function tests.

Pathological examination showed acalculous cholecystitis, with patchy necrosis and edema of the serosa and muscular layers.

### Discussion

In the literature, Mirizzi syndrome has been mainly reported in relation to gallbladder stones and it is very rare to have Mirizzi syndrome in acalculous cholecystitis [1,2,7].

In this paper, we have presented a report on a patient who suffers from Mirizzi syndrome type-I due to acalculous cholecystitis and recovery has been achieved just with a cholecystectomy.

The other noteworthy point about this patient is occurrence of acalculous cholecystitis in a young girl who was healthy otherwise. Our diagnosis before operation for the patient was choledochal cyst, which is by far more common. While performing cholecystectomy with enough time and patience, care should be taken not to injure the common bile duct in Mirizzi syndrome type-1 [5].

### References

- PenKov N. Mirizzi syndrome. *Khiurgiiia* 2003; 59(3): 34-7.
- Xiaodong H, Hongsheng L, Chaoji Z, et al. Diagnosis and treatment of the Mirizzi syndrome. *Chin Med Sci J* 1999; 14(4): 246-8.
- Kaushik R, Sharma R. Jejunal serosal onlay flap for repair of large common bile duct defect in Mirizzi syndrome. *Trop Gastroenterol* 2001; 22(3): 169-70.
- Adams TW, Foxley EG. A diagnostic technique for acalculous cholecystitis. *Surg Gynecol Obstet* 1976; 142(2): 168-70.
- Corlette MB. Biliobiliary fistula. *Arch Surg* 1975; 110: 337.
- Csendes A, Carlos Diaz J, et al. Mirizzi syndrome and cholecystobiliary fistula: A unifying classification. *Br J Surg* 1989; 76: 1139.
- Singer AJ. Correlation among clinical, laboratory and hepatobiliary scanning findings in patients with suspected acute cholecystitis. *Ann Emerg Med* 1996; 28: 276.
- Hakala T. Microangiopathy in acute acalculous cholecystitis. *Br J Surg* 1997; 84: 1249.
- Hultman CS, Hergst CA, Mc Call JM, et al. The efficacy of percutaneous cholecystectomy in critically ill patients. *Am Surg* 1996. 62: 263.
- Lo LD, Vogelzang R, Braun MA, et al. Percutaneous cholecystectomy for the diagnosis and treatment of acute calculus cholecystitis. *J Vasc Intervent Radiol* 1995; 6: 629.