

TRANSNASAL ENDOSCOPIC APPROACH FOR SINONASAL INVERTED PAPILLOMA

MOHAMMAD HOSSEIN BARADARANFAR, M.D., AND PAYMAN
DABIRMOGHADDAM, M.D.

*From the Department of Otolaryngology, Head and Neck Surgery, Sadoughi Hospital, Yazd University of
Medical Sciences, Yazd, I.R. Iran.*

ABSTRACT

Inverted papillomas of the nose and paranasal sinuses are uncommon neoplasms, characterized by their tendency to occur and by their association with malignancy. In the past decade there has been a trend toward the use of endoscopic surgical techniques in the management of these tumors. This article presents the results of a prospective study of 24 patients with inverted papilloma resected by the endoscopic approach. 21 patients had unilateral disease and three patients had bilateral involvement. None of the patients had orbital or cranial extension. No association with malignancy was seen.

Following endoscopic surgery, four patients had recurrences that required surgery. No complication occurred in any of the patients. The results of endoscopic surgery for inverted papilloma is much better than nonendoscopic transnasal approaches and compares favorably with radical extranasal approaches.

Endoscopic surgery is an effective surgical option for inverted papilloma removal.
MJIRI, Vol. 18, No. 2, 127-130, 2004.

Keywords: Inverted Papilloma, Endoscopic Surgery, Paranasal Sinus Neoplasm.

INTRODUCTION

Inverted papilloma is a benign neoplasm that represents less than 4% of sinonasal tumors.¹ It arises primarily in the nasal cavity but often enlarges to invade the lacrimal system, the orbit, or the intracranial cavity and can cause extensive destruction of bone and soft tissues.² Lesions tend to be bulky, polypoid and characteristically pale pink to gray in color.³

Histologically the neoplastic epithelium inverts into the underlying stroma rather than proliferating outward and may invaginate to remodel bone but will not invade it without malignant transformation.⁴

The exact etiologies of inverted papilloma remain unknown, although a number of etiologies have been pro-

posed including allergy, occupational exposure and chronic inflammation.⁴

A possible viral origin by Human Papilloma Virus (HPV) has repeatedly been reported by several authors^{5,6} although the frequency of virus particle finding was variable.

Computed tomography (CT) is commonly used for the standard preoperative workup to evaluate the degree of involvement by tumor and to determine the extent of surgery.⁷ However it is difficult to differentiate neoplasm from inspissated mucus, mucoperiosteal thickening, or polyps resulting from obstruction of the sinus drainage pathways.⁸

Inverted papilloma is renowned for its high local recurrence rate and malignant transformation potential.⁹ The reported average recurrence rate ranges from 4%¹⁰ after radical extranasal excision to 66%¹¹ after nonendoscopic endonasal excision.

A review of literature showed that the overall association with malignancy is nine percent.¹² It may be synchronous or metachronic.¹

E-mail: baradaranf@ hotmail.com. Mailing Address: No 70, Laleh Alley, Kashani Street, Yazd, I.R. Iran. Zip code: 8916758385.
98 351 5225291, Fax: +98 351 8224100.

Transnasal Endoscopic Approach for Sinonasal Inverted Papilloma

This study evaluates the presentation, treatment and subsequent clinical course of patients treated for inverted papilloma by the endoscopic approach.

MATERIAL AND METHODS

24 cases of inverted papilloma were operated at the Amiralam hospital, Tehran and Rahneem hospital, Yazd between 1998 and 2003.

21 patients were managed with the transnasal endoscopic approach alone and in 4 other cases a combined approach (endoscopy with Caldwell-Luc) was performed.

Histopathologic evaluation proved all cases to be inverted papilloma without any evidence of malignancy.

Age at diagnosis, gender, presenting symptoms, site of lesion, primary versus recurrent treatment, endoscopy alone with or without the Caldwell - Luc approach and recurrence rates were reviewed.

All patients were assessed preoperatively by endoscopic examination and coronal computed tomography (CT) imaging (Fig.1).

Endoscopic resection was performed under general anesthesia. The nose was prepared using gauze soaked in

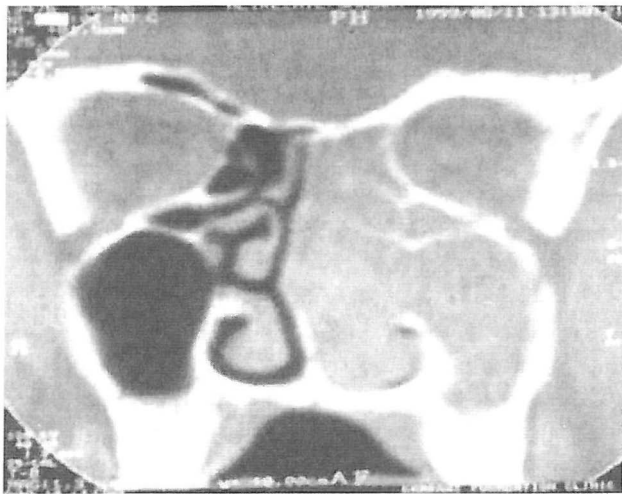

Fig. 1. Preoperative coronal CT scan.

solution of 2% lidocaine and 1:100,000 adrenaline. At operation an incision was made at the superior margin of the tumor and its attachment to the middle turbinate or lateral nasal wall was cut. Then the tumor was dissected toward the rostrum of sphenoid, inferior to fovea ethmoidalis with an elevator. An inferior incision was made at the junction of the lateral nasal wall and nasal floor and then an osteotomy was performed toward the posterior wall of the maxillary sinus. The anterior part of incision extends from the anterior attachment of the middle turbinate to the anterior part of the

inferior turbinate and then connects to the inferior meatus. Depending on the tumor extension, the anterior margin of tumor resection may extend toward the ascending process of the maxilla or may include the nasolacrimal duct but this is unnecessary in all patients. The tumor with its surrounding soft tissues was medialized and then was pulled out from the nose.

Resection of the medial orbital wall or inferior turbinate was performed in cases with involvement of these areas (Fig. 2).

All patients were regularly followed up and examined endoscopically with all suspicious areas being removed under local anesthesia and sent for histological analysis.

Recurrences were resected under general anesthesia ei-

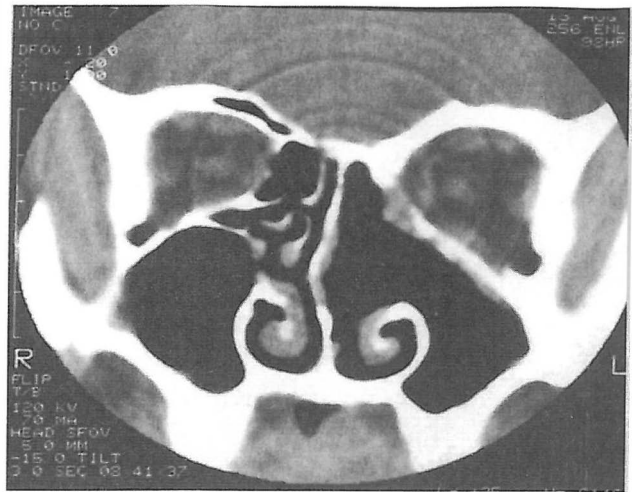


Fig. 2. Postoperative coronal CT scan.

ther endoscopically or via a combined (endoscopic and Caldwell - Luc) approach.

RESULTS

The clinical data of the patients is presented in Table I. There were two female patients and the other patients were male. The mean age was 58.6 years with a range of 46 to 76 years.

There were 13 (54%) left sided lesions and 8 (33.5%) right sided lesions with three (12.5%) bilateral lesions.

The mean follow-up for all patients was 31.3 months with a range of 8 to 62 months.

The most frequent symptom was nasal obstruction that was seen in 86% of patients. Other frequent symptoms were rhinorrhea (64%), headache and facial pain (36%) and epistaxis (15%).

All patients were operated for the first time and no patient had malignancy associated with his disease.

The diseased sites included the lateral nasal wall and adjacent sinuses without any orbital or cranial involvement. In two patients in which the site of attachment was the medial orbital wall, the involved portion was resected. Or-

Table 1. Results of endoscopic resection of sinonasal inverted papillomas.

Sex	Age	Type of Surgery	Site of involvement	Follow up (month)	Recurrence	Time of Recurrence (month)	Type of surgery
Male	56	Endoscopic	Left	71	-	-	-
Male	76	Endoscopic	Left	69	-	-	-
Male	52	Endoscopic	Right	68	+	8	Endoscopic
Male	58	Endoscopic	Left	64	-	-	-
Male	73	Endoscopic	Left	61	+	11	Endoscopic Caldwell - Luc
Male	62	Endoscopic	Bilateral	60	-	-	-
Male	65	Endoscopic Caldwell-Luc	Left	57	-	-	-
Male	63	Endoscopic Caldwell-Luc	Left	37	-	-	-
Male	49	Endoscopic	Left	35	-	-	-
Male	61	Endoscopic	Left	33	-	-	-
Male	58	Endoscopic	Right	33	+	14	Endoscopic Caldwell - Luc
Male	46	Endoscopic	Left	31	-	-	-
Female	48	Endoscopic	Left	30	-	-	-
Male	54	Endoscopic	Bilateral	30	Left+	8	Endoscopic Caldwell - Luc
Male	65	Endoscopic	Left	27	-	-	-
male	68	Endoscopic	Right	24	-	-	-
Male	52	Endoscopic	Left	24	-	-	-
Male	48	Endoscopic Caldwell-Luc	Right	23	-	-	-
Male	63	Endoscopic	Right	20	-	-	-
Female	59	Endoscopic	Bilateral	17	-	-	-

bital, intracranial or lacrimal apparatus involvement were not seen.

Four patients with lateral maxillary wall involvement underwent endoscopic medial maxillectomy with the Caldwell-Luc approach.

Sixteen percent (4/24) of the patients had recurrences after initial endoscopic resection which occurred within the first postoperative year. One of these was successfully resected endoscopically under general anesthesia and three required removal via a combined (endoscopy with Caldwell - Luc) approach.

None of the patients had residual disease at the end of this review.

No complications were encountered in any of the patients.

DISCUSSION

Because of the aggressive nature of tumor growth and malignant transformation potential, inverted papilloma should not be managed as a totally benign tumor.

Inverted papilloma occurs most commonly in the fifth to

Transnasal Endoscopic Approach for Sinonasal Inverted Papilloma

seventh decade^{4,11} as shown in our study with a mean age of 62 years.

A male predominance similar to our series is generally reported, with male to female ratios of 2:1 to 3:1.^{4,11,12}

The most common presenting symptom is that of unilateral nasal obstruction¹² which varies from 64%¹³ to 81%¹⁴ in the literature.

Definitely inverted papilloma treatment is surgical and must aim at being radical.¹² The radical external approach, lateral rhinotomy or midfacial degloving with en bloc resection of the lateral nasal wall, still remains the golden standard for inverted papilloma surgery due to the lowest rate of recurrence.⁹

The fact that most recurrences occur early and at the site of the original tumor strongly suggest that incomplete local resection is the cause of recurrent disease.⁹

Endonasal surgery was formerly performed without any endoscopic control and was known as conservative surgery. It was characterized by a very high recurrence rate ranging from 10% to 77%.¹ The recurrence rate of the endoscopic approach is much lower than that of the nonendoscopic approach.⁹ This is attributable to the improved visualization of the tumor and anatomy, advanced surgical instrumentation and application of new techniques. It is noteworthy that the recurrence rate of the endoscopic approach is still higher than radical extranasal approaches.⁹

Our recurrence rate of 16% in this study is higher than that of radical extranasal excision that reflects certain limitations associated with the endoscopic approach but it compares favorably with other endoscopic series.^{1,3,9}

It is important to note that endoscopic tumor surgery is technically demanding and associated with potential complications.¹⁵ To ensure a low recurrence rate and avoid complications, endoscopic tumor resection should be performed by surgeons who are experienced in the techniques of endoscopic sinus surgery.⁹

The endoscopic approach alone can be applied to tumors affecting the turbinates, ethmoid sinuses, and limited involvement of the maxillary, frontal and sphenoid sinuses. More extensive disease requires extranasal approaches which may be combined with the endoscopic approach at any time.

The assessment of endoscopic resectability depends on preoperative endoscopic examination, CT imaging and more importantly intraoperative assessment including tumor visualization and accessibility.

The role of endoscopy in the follow-up of these patients is important. The excellent visualization of the postoperative cavity enables early detection of residual disease.

Furthermore minor revision surgery can be performed under local anesthesia as an outpatient procedure.

CONCLUSION

In unilateral nasal obstruction or unilateral nasal polyps

should alert the otolaryngologist to the possibility of inverted papilloma.

Our results show that inverted papilloma surgery under endoscopic control is a satisfactory option in the armamentarium of treatments although it requires larger patient populations and longer follow-up periods for more definite evaluation.

REFERENCES

1. Bertrand B, et al: Surgery of inverted papillomas under endoscopic control. *Acta Oto - Rhino - Laryngologica Belg* 54: 139-150, 2000.
2. Krouse JH: Endoscopic treatment of inverted papillomas: safety and efficacy. *American Journal of Otolaryngology* 22: 81-99, 2001.
3. Thorp MA: Inverted papilloma: a review of 53 cases. *Laryngoscope* 111: 1401-1405, 2001.
4. Hyams VJ: Papillomas of the nasal cavity and paranasal sinuses. A clinicopathological study of 315 cases. *Ann Otol Rhinol Laryngol* 80: 192-206, 1971.
5. Respler DS, Jahn A, Pater A: Isolation and characterization of papillomavirus DNA from nasal inverting (Schniderian) papillomas. *Ann Oto Rhinol Laryngol* 96: 170-137, 1987.
6. Brandwein M, Steinberg B, Thung S: Human papillomavirus 6/11 and 16/18 in Schniderian inverted papillomas. *Cancer* 63: 1708-1713, 1989.
7. Sokenik MA, Casiano R: Endoscopic medial maxillectomy for inverted papilloma of the paranasal sinuses: value of the intraoperative endoscopic examination. *Laryngoscope* 110: 39-42, 2000.
8. Blackwell KE, Anzai Y, Lufkin RB, Bielamowicz S, Calcaterra TC: Radiologic assesment of inverted papilloma. *Am J Rhinol* 8: 253-258, 1994.
9. Sham CL, Woo JU, Van Hasselt CA: Endoscopic resection of inverted papilloma of the nose and paranasal sinuses. *Journal of Laryngol Otol* 112: 753-754, 1998.
10. Myers E, Fernau J, Johnson J, Tabet J, Barnes E: Management of inverted papilloma. *Laryngoscope* 104: 415-419, 1994.
11. Beninger M, Lavertu P, Levine H, Tucker H: Conservation surgery for inverted papilloma. *Head and Neck* 13: 442-445, 1991.
12. Lawson W, Bengner J, Som P, Bernard P, Biller H: Inverted papilloma: an analysis of 87 cases. *Laryngoscope* 99: 1117-1124, 1989.
13. Phillops PP, Gustafson RO, Facer GO: The clinical behavior of inverted papilloma of the nose and paranasal sinuses: report of 112 cases and review of the literature. *Laryngoscope* 100: 463-469, 1990.
14. Yoskovitch A, Braveman I, Nachitgal D, Frenkiel S, Kochon L, Black MJ. Sinoasal Schniderian Papilloma. *J Otolaryngol* 27: 122-126, 1998.
15. Stankiewicz JA, Giris SJ: Endoscopic surgical treatment of nasal and paranasal sinus inverted papilloma. *Otolaryngol Head Neck Surg* 109:788-995, 1993.