

Vertebral Malacoplakia

Mojgan Mokhtari, MD.¹, Shervin Pejhan, MD.², Ahmad Shekarchizadeh, MD.³

Department of Pathology, Isfahan University of Medical Sciences, Isfahan, Iran.

Abstract

Malacoplakia is a rare chronic inflammatory disease associated with infection and immunosuppression, and very few occurrences have been reported in the bone. The authors describe the case of a 22-year-old woman with paraplegia and urinary and fecal incontinence whose thoracic spine Magnetic Resonance Imaging suggested a tumoral or extensive inflammatory process in the body of the 8th, 9th and 10th thoracic vertebrae. On histology, however, the area turned out to be malacoplakia of bone. Although microbiologic cultures and polymerase chain reaction were negative for Mycobacterium tuberculosis, the lesion demonstrated regression following treatment with anti-TB regimen which had been started because of clinical suspicion.

Keywords: Malacoplakia of bone, vertebra, rare site.

Introduction

Malacoplakia, a rare disorder that involves a unique abnormal histiocytic response is most commonly found in the viscera. Rarely, it is found in bone. As in other sites, it probably represents an unusual host reaction to bacterial infection, and biopsy of the lesions almost always reveals the characteristic Michaelis-Gutmann bodies. We present the case of a patient in whom Malacoplakia involved vertebral bone.

Case Report

A 22 year-old woman was referred to our hospital with a complaint of paraplegia and urinary and fecal incontinence since 1 month ago. She was found to be suffering from back pain as well as occasional fever and diaphoresis over a period of three months. The medical history was positive for congenital abnormality of the

pancreas associated with fistular pancreatitis. The findings on physical examination were unremarkable except for paraplegia, symmetrically diminished reflexes in the lower extremities, and presence of bilateral Babinski reflex. The muscular force of the lower extremities was equal to 1/5 and there was a sensory level at T7-T8. Examination of the rectum revealed a decreased sphincter tone. No other neurological deficits were identified, specifically in the upper limbs.

In her laboratory exams only the elevation of Erythrocyte Sedimentation Rate to 140mm was remarkable. Magnetic Resonance Imaging of the thoracic spine in T2 series showed hyperintensity in the body of 8th, 9th and 10th thoracic vertebrae. The body of T8 and T9 vertebrae were decreased in height, and the thoracic cord was significantly encased at these levels. These findings suggested tumoral or extensive inflammatory process (Fig.1).

1. **Corresponding author**, Assistant Professor of Pathology, Department of Pathology, Isfahan University of Medical Sciences. Address: No. 62, 178 Gharbi Ave., Tehranpars, Tehran, Iran. P.O.Box: 1653974656, Tel: +9821 22957706, +98932 9046203, Fax: +9821 22571975, email: dew_p81@yahoo.com.

2. Assistant Professor of Pathology, Shahid Beheshti University of Medical Sciences.

3. Assistant Professor of Neurosurgery, Isfahan University of Medical Sciences.

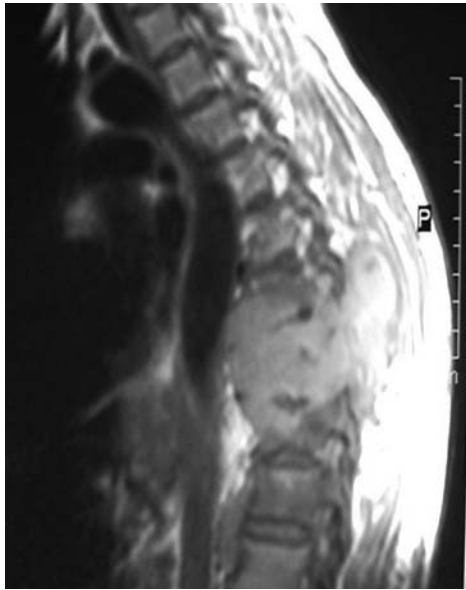


Fig.1. MRI of thoracic spine (T2 series) showing hyperintensity in the body of 8th, 9th and 10th thoracic vertebrae.

The patient underwent laminectomy and vertebral fixation in order to decompress the thoracic spine. Microscopic examination of vertebral tissue revealed large histiocytic cells with granular cytoplasm, containing intracytoplasmic, basophilic, laminated, targetoid Michaelis-Gutmann bodies. They were diffusely positive by histochemical staining with periodic Acid-Schiff and Prussian blue stains (Fig. 2).

Histopathology confirmed the diagnosis of malacoplakia of bone [1, 2]. The tissue that was used for routine histological examination was deparaffinized and examined for *Mycobacterium tuberculosis* by polymerase chain reaction. The negative results of PCR and microbiologic cultures for *Mycobacterium tuberculosis* did not prevent anti-TB regimen therapy because of clinical suspicion and the fact that PCR in paraffin blocks has a high rate of false negativity caused by the inhibitor effect of paraffin [3]. This therapy resulted in a good clinical response. The patient was free of pain and neurological deficits were regressing. Also the ESR decreased gradually.

Discussion

Malacoplakia is a rare chronic inflammatory

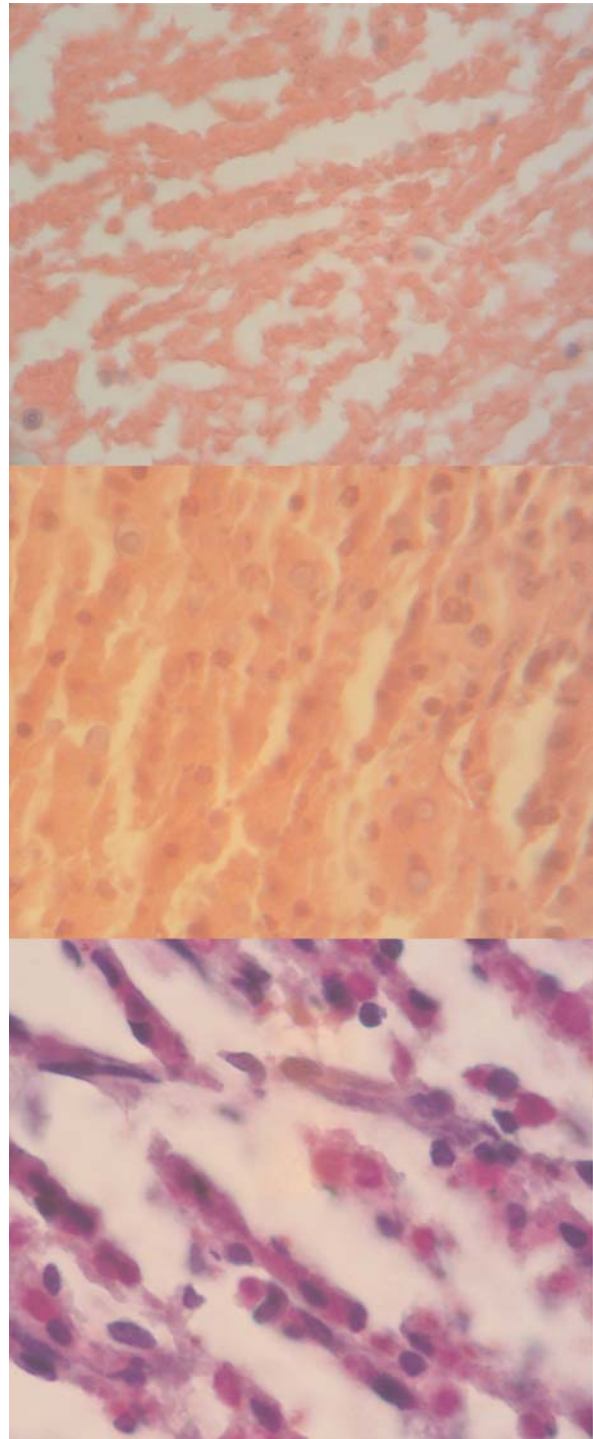


Fig. 2. Numerous histiocytes in malacoplakia of bone. Targetoid Michaelis-Gutmann bodies are PAS positive and stain positive for iron.

disease associated with infection and immunosuppression and very few occurrences have been reported in bony tissues [1,4].

The etiology, pathogenesis and clinicopathological features of the osseous lesion are incompletely understood, but there is suggestive evidence that the lesions result from a defect in macrophage function that blocks the lysosomal degradation of engulfed bacteria and overloads the cytoplasm with undigested cellular debris [1,4,5,6].

The cases of malacoplakia of bone which have been reported to date have been associated with different immune deficiency states like renal transplantation, chemotherapy-related leukopenia, and even diabetes mellitus [5,7,8].

The history of pancreatitis in the patient reported here might have lead to an immunocompromised status, providing the situation for mycobacterial infection and developing malacoplakia. Examination of immunological status in the patients with both mild and severe pancreatitis has illustrated depression of T- and B-links of immunity [9-11]. Reduction of circulating lymphocytes of both CD4 and CD8 subgroups is also observed [12,13].

In summary, Malacoplakia of bone is a rare entity that sometimes clinically mimics a neoplastic process, and it should be considered in the differential diagnosis of lytic bone lesions, especially in immunosuppressed patients [5,7,14].

Acknowledgements

We thank Dr Alireza Modares Fathi and Mr. Ehsan Samiee who helped us to prepare this article.

References

1. Rosai J. Rosai and Ackerman's surgical pathology. Philadelphia: Mosby;2004.pp. 1321-1322.
2. Stanton MJ, Maxted W. Malacoplakia. A Study of the literature and current concepts of pathogenesis, diagnosis and treatment. J Urol 1981 Feb;125(2):139-146.
3. McPherson MJ, Moller SG. PCR. London: Bios Scientific Publishers; 2000.pp. 76-77
4. Choudhury M, Bajaj P, Jain R, Nangia A, Aneja S. Malacoplakia of bone: a case report. Acta Cytol 2001

May-Jun; 45(3):404-6.

5. Pang LC. Pulmonary Malacoplakia coexistent with tuberculosis of the hilar lymph node mimicking malignancy. Respiration 2005 Jan-Feb; 72(1): 95-100.

6. Anastasiades KD, Otis JB, Campbell WG. Vertebral Malacoplakia. A case report. J Bone Joint Surg Am 1987 Mar; 69(3): 458-462.

7. Van den Bout AH, Dreyer L. Malacoplakia of bone: a case report. J Bone Joint Surg Br 1981 Aug; 63-B(2): 254-6

8. Weisenburger DD, Vinh TN, Levinson B. Malacoplakia of bone: an unusual cause of pathologic fracture in an immunosuppressed patient. Clin Orthop Relat Res 1985 Dec;(201): 106-10

9. Gubergits NB. Clinico-immunological changes in patients with chronic pancreatitis and their correction during the treatment. Ter Arkh 1989;61(2):18-21.

10. Averkiev VL, Tarasenko VS, Latysheva TV, Proskuriakov VE, Averkieva LV. Changes of immune indices in pancreonecrosis and their correction. Khirurgiia (Mosk) 2003; (5):31-4.

11. Tarasenko VS, Kubyshekin VA, Smoliagin AI, Popova EV, Shefer AV. Characteristics of immunologic disorders in patients with acute destructive pancreatitis. Khirurgiia (Mosk) 2001;(4):31-4.

12. Widdison AL, Cunningham S. Immune function early in acute pancreatitis. Br J Surg 1996 May; 83(5): 633-6.

13. Borovkova NV, Khvatov VB, Grishin AV, Blagovestnov DA. Complex of immunological characteristics for the diagnostics of pancreatogenic immunodeficiency. Zh Mikrobiol Epidemiol Immunobiol 2006 May-Jun; (3): 71-5.

14. Tyagi N, Sadiq SA, Maheshwari V, Abbas M, Tyagi SP. Malacoplakia of bone presenting as a pathological fracture. Postgrad Med J 1994 Jun; 70(824): 461-2