Medical Journal of the
Islamic Republic of Iran

Volume 17
Number 2
Summer 1382
August 2003

Case Reports

HISTIOCYTE-RICH B-CELL LYMPHOMA: A CASE REPORT OF A RARE VARIANT OF DIFFUSE LARGE B-CELL LYMPHOMA

T. GHIASI MOGHADDAM, M.D.,* K. GHAFARZADEGAN, M.D., AND N. SHARIFI, M.D.****

From the Department of Pathology, Ghaem Hospital, Mashhad University of Medical Sciences, Mashhad, I.R. Iran.

ABSTRACT

The authors describe a case of histiocyte-rich B-cell lymphoma (HR-BCL), a variant of diffuse large B-cell lymphoma, in a 51-year-old man. The patient presented with large axillary lymphadenopathy. Histopathologic and immunohistochemical examination of lymph node biopsy revealed diffuse effacement of the lymph node architecture by reactive histiocytes and neoplastic CD20 positive B cells. Reactive histiocytes were negative for CD15 and CD30 immunostaining. The final diagnosis was histiocyte-rich B-cell lymphoma (HR-BCL) and the patient was referred to the oncology clinic for treatment.

MJIRI, Vol. 17, No. 3, 159-161, 2003.

Keywords: Histocyte - rich B-cell lymphoma, diffuse large B-cell lymphoma.

INTRODUCTION

Large B cell neoplasms represent one of the most frequent groups of non-Hodgkin lymphomas. They are characterized by an aggressive clinical course. The neoplastic cells, even within one given case, show a broad morphologic spectrum. In the WHO classification, there are two groups identified, that of variants and that of subtypes. These variants include: centroblastic, immunoblastic, anaplastic and T cell/histiocyte rich forms. The primary mediastinal, the intravascular, the primary effusion and primary CNS lymphoma constitute sybtypes.[1]

Histiocyte-rich B cell lymphoma is a distinct diffuse large B cell lymphoma subtype showing characteristic morphologic and immunophenotypic features.[2] The clinicopathological features of histiocyte rich B-cell lymphoma were first recognized in 1992.[3]

Address reprint requests to: Dr. Kamran Ghafarzadegan, P.O. Box 91375-5636, Mashhad, Iran. Email: Kghafarzadegan@hotmail.com

* Associate professor of pathology, Ghaem Hospital, Department of Pathology, Mashhad University of Medical Sciences.

** Assistant professor of pathology, Ghaem Hospital, Department of Pathology, Mashhad University of Medical Sciences.

CASE REPORT

The patient is a 51-year-old male musician who presented with a large axillary lymphadenopathy, fever, night sweats and weight loss. The patient had symptoms for a few months. There was also lymphadenopathy in the neck and inguinal area. Sonography revealed para-aortic and iliac adenopathy. The liver and spleen were normal. The patient refused to perform bone marrow aspiration or biopsy.

The patient had an elevated ESR (25mm/1st hour), and other laboratory results were normal. HTLV I/II Ab tests were negative.

[Downloaded from mjiri.iums.ac.ir on 2024-04-16]

Macroscopic, microscopic and immunohistochemical findings

The specimen received in formalin consisted of a lymph node, 4×3×2cm with a thin capsule. The cut surface had a homogenous creamy and fleshy appearance.

Microscopic examination showed architectural effacement by a diffuse infiltrate composed predominantly of benign histiocytes (Fig. 1). There was filling of sinuses by these histiocytes. There were small and large lymphocytes with vesicular nuclei among the histiocytes. PAS staining was negative.

Formalin-fixed, paraffin-embedded tissue was stained by the DAKO-CSA (catalyzed signal amplification) system with 3.3' diamino benzidine tetrahydrochloride as chromogen. The antibodies used included CD3 (prediluted, Dako), CD20 (prediluted, Dako), CD30 (prediluted, Dako), and CD15 (clone C30-1, prediluted, Dako).

Immunohistochemical staining showed CD20 reactivity in neoplastic lymphocytes (Fig. 2). CD3 staining was sparse and focal. Histiocytes were negative for CD30, CD20 and CD3 staining. These findings were consistent with the diagnosis of histiocyte-rich B-cell lymphoma.

1a

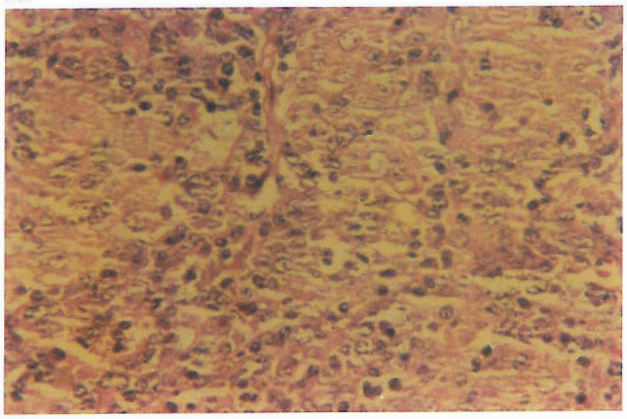

1b

Fig. 1. Axillary lymph node. a, The lymph node architecture is diffusely replaced by the neoplasm. There are many histiocytes with eosinophilic cytoplasm (H & E, ×100); b, At high magnification, the neoplasm is seen to be composed of small and large lymphocytes (H & E, × 400).

DISCUSSION

Clinically, patients with HR-BCL usually have stage III or IV disease and B symptoms.[3,4] Patients present with generalized lymphadenopathy, and with a high incidence of splenomegaly, hepatomegaly and bone marrow involvement.[3]

Histologically, lymph node biopsies involved by HR-BCL show architectural effacement by a vaguely nodular or diffuse infiltrate composed predominantly of benign histiocytes. The histiocytes lack cytologic atypia and are reported to rarely form granulomas or have epitheloid features.[3] Scattered among the reactive population are small and large, cytologically atypical lymphocytes with vesicular nuclei, the neoplastic cell population.[3] HR-BCLs may represent a distinct clinicopathologic entity or may instead be a variant of T-cell rich B-cell lymphoma (TCR BCL) and represent a peculiar morphologic manifestation of non-Hodgkin's lymphoma. Delabie and colleagues believe that HR-BCL is a distinct clinicopathologic entity in which the neoplastic cells are derived from the same subset of B cells that give rise to the L&H cells of lymphocyte predominance Hodgkin's disease.[3]

Futhermore, they propose that the absence of epitheloid features or granulomas in the reactive histiocyte population suggests that these cells are not participating with T cells as part of a cell-mediated response to the tumor. Instead these histiocytes may be recruited by the neoplastic cells, via the secretion of growth factors.[3]

The distinction between HR-BCL, TR-BCL and lymphocyte predominance Hodgkin's disease is difficult. The

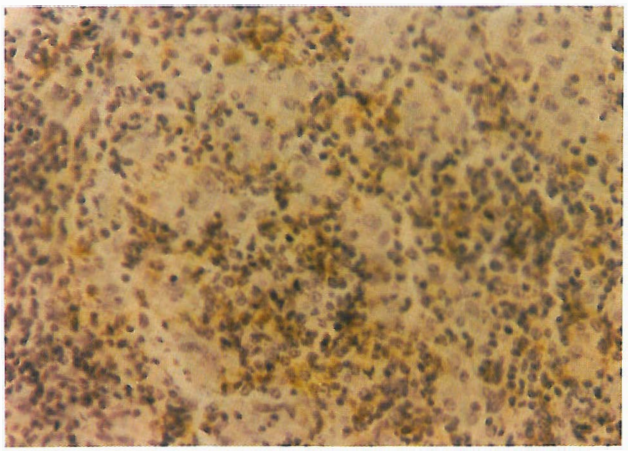

Fig. 2. Immunohistochemical staining. The neoplastic lymphocytes reacted with CD20 (B-cell) antibody.

[Downloaded from mjiri.iums.ac.ir on 2024-04-16]

greater number of reactive histiocytes without epitheloid features or granulomas favor the diagnosis of HR-BCL over TR-BCL. In contrast with lymphocyte predominance Hodgkin's disease, the neoplastic cells in HR-BCL are of variable size, with only the largest cells being multilobed and resembling L&H cells,[3] and the neoplasm commonly extends beyond the lymph node capsule into perinodal adipose tissue. In addition, immunoglobin gene rearrangement is identified in many cases of HRBCL. In lymphocyte predominance Hodgkin's disease, the histiocytes may be epitheloid or form granulomas and the tumor rarely extends beyond the lymph node capsule. Immunoglobulin gene rearrangement is identified infrequently in lymphocyte predominance Hodgkin's disease.

Son et al. analyzed a case of HR-BCL by flowcytometry and cytogenetic study. The immunophenotype determined by flow cytometry was that of a B cell antigen positive, surface immunoglobulin negative B cell lymphoma with 79% CD11C positive histiocytes.[5] The lymphoid cells were composed of 76% neoplastic B cells and 24% reactive T-cells. The tumor cells were large, pleomorphic lymphoid cells and showed no feature resembling those of the L/H cells of Hodgkin's disease.[5]

They believed that this entity merits special recognition because it leads to a predictable poor prognosis and because of its potential of being misdiagnosed as true histiocytic lymphoma.[5]

ACKNOWLEDGEMENTS

The authors would like to thank Dr. Moayed's Laboratory and Ms. Rezai for excellent technical cooperation in the preparation of immunohistochemical slides.

REFERENCES

1. Anagnostopoulos I, Stein H: Large B cell lymphomas: variants and entities. Pathol 21(2): 178-89, March 2000.
2. Achten R, Verhoef G, Vanuytsel L, De wolf-peeters C: Histiocyte-rich, T-cell-rich B-cell lymphoma subtype showing characteristic morphologic and immunophenotypic features. Histopathology 40(1): 31-45, 2002.
3. Delabie J, Vandenberghe E, Kennes C, Verhoef G, Foschini MP, Stul M, Cassiman JJ, De wolf-peeters C: Histiocyte-rich B-cell lymphoma. A distinct clinicopathologic entity possibly related to lymphocyte predominant Hodgkin's disease, Paragranuloma subtype. Am J Surg Pathol 16(1): 37-48, 1992.
4. Chittal SM, Brousset P, Voigt JJ, Delsol G: Large B cell lymphoma rich in T cell and simulating Hodgkin's disease. Histopathology 19:211-220, 1991.
5. Sun T, Susin M, Tomao FA, Brody J, Koduru P, Hajdu SI: Histiocyte-rich B cell lymphoma. Hum Pathol 28(11): 1321-4, 1997.

[Downloaded from mjiri.iums.ac.ir on 2024-04-16]

[Downloaded from mjiri.iums.ac.ir on 2024-04-16]