

THERAPEUTIC EFFECTS OF LASER PHOTOCOAGULATION AND VITRECTOMY IN EALES' DISEASE

M.H. DEGHAN, M.D., H. AHMADIEH, M.D., M. SOHEILIAN, M.D.,
M. AZARMINA, M.D., A. MASHAYEKHI, M.D., AND
J. NAGHIBOZAKERIN, M.D.

*From the Ophthalmic Research Center, Department of Ophthalmology, Labbafinejad Medical Center,
Shahid Beheshti University of Medical Sciences, Tehran, I.R. Iran.*

ABSTRACT

Eales' disease is an idiopathic obliterative retinal vasculopathy that is treated with laser photocoagulation, and/or vitrectomy. In order to determine visual outcomes and regression of retinal neovascularization following scattered peripheral retinal photocoagulation, and/or vitrectomy in cases with Eales' disease, we did a retrospective study of the records of these patients treated in Labbafinejad Medical Center from 1988 to 1998.

We studied the existing data of 67 eyes of 54 patients with complicated Eales' disease who had undergone laser photocoagulation and/or vitrectomy based on their clinical presentations.

Our main outcome measure was the visual acuity changes of the eyes following treatment.

In 43 eyes, scattered peripheral retinal photocoagulation alone led to complete regression of neovascularization and a VA of 20/30 was obtained in 60.4%. Vitrectomy was finally required in 24 eyes and of these, 37.5% gained a VA of 20/30.

Although scattered peripheral retinal photocoagulation should be the first line of treatment in Eales' disease, it may not always produce regression of retinal neovascularization. In such cases vitrectomy may further enhance therapeutic success.

MJIRI, Vol. 17, No. 1, 41-45, 2003.

Keywords: Eales', Photocoagulation, Vitrectomy.

INTRODUCTION

Eales' disease is an idiopathic obliterative vasculopathy that primarily affects the peripheral retina of adults. Retinal changes include extensive peripheral nonperfusion, perivascular sheathing, and neovascularization. Most patients have symptoms of vitreal hemorrhage, such as small specks, float-

ers, cobwebs, blurring, or decreased visual acuity. Others have blurring associated with retinal vasculitis or uveitis, but without hemorrhage. Severe visual loss usually results from complications of neovascularization, such as persistent vitreous hemorrhage, retinal detachment, and anterior segment neovascularization with secondary glaucoma.¹

Laser photocoagulation was used for treating neovascularization with good results in 1954,² and since then has become the treatment of choice for patients with neovascularization.^{3,4} Magargal et al.³ found favorable results in eyes that were treated with fairly light, full scatter

Ophthalmic Research Center, Department of Ophthalmology, Labbafinejad Medical Center, Pasdaran Ave., Boostan 9, Tehran, I.R. Iran.
Zip Code: 16666 Fax: (98)-21-2549039. E-mail: labbafi@hotmail.com

Laser Photocoagulation and Vitrectomy in Eales' Disease

photocoagulation of the nonperfused retina and the junction of perfusion and nonperfusion. Vitrectomy often can be employed for removing persistent vitreal hemorrhages and scar tissue with good results.⁶⁻⁸

This study was aimed to evaluate the therapeutic effects of laser photocoagulation and vitrectomy in complicated cases of Eales' disease treated in Labbafinejad Medical Center from 1988 to 1998.

PATIENTS AND METHODS

This is a study of existing data on 67 eyes from 54 patients with Eales' disease, referred to the Labbafinejad Medical Center (LMC) from 1988 to 1998. Our main outcome measure was visual acuity changes of treated patients. Visual acuity of patients had been checked before and after procedures, and during follow ups. Every patient had a thorough recorded history and physical examination including: slitlamp examination, checked IOP with applanation tonometer, and complete fundus examination by indirect ophthalmoscope with scleral depression and three mirror lens.

In fundus examination special emphasis was placed on looking for vitreous changes like vitreal hemorrhage, vitreous organization, tortuosity of vessels, sheathing, retinal hemorrhage and ischemic areas. Fluorescein angiography had been performed for better visualization of new vessels in required cases. In cases of vitreous hemorrhage with impossible visualization of the fundus, echography had been done to rule out retinal detachment.

Paraclinical evaluations of every patient were CBC with differential, ESR, FBS, Ca, P, PPD, ANA, LE cell, RF, serum protein electrophoresis, Hgb electrophoresis, serum immunoglobulin electrophoresis, angiotensin converting enzyme and chest X-ray.

Depending on the condition of disease photocoagulation techniques were as follows:

1. Local treatment for flat neovascular elsewhere (NVE).
2. Sector scatter photocoagulation for involvement of one retinal sector only.
3. Mixed treatment for combination of the above two in one setting.
4. Peripheral panretinal photocoagulation (PRP) for complete involvement of the peripheral retina.

Argon-green laser had been used as standard type and Krypton-red laser had been considered in cases of vitreous hemorrhage. The laser setting was spot size of 500 mic., duration of 0.2-0.5 sec., and the intensity 2 or 3 standard grading. After 6-8 weeks of laser therapy, if there had been no regression of new vessels, or recurrence of vitreous hemorrhage, additional laser therapy had been done. Cases with good response to laser therapy had been followed every 3-4 months.

Indications for vitrectomy were:

1. Nonclearing dense vitreous hemorrhage lasting more

than 6 months, or organized vitreous hemorrhage precluding reliable fundus visualization.

2. Tractional retinal detachment involving or threatening macula.

3. Combined tractional and rhegmatogenous retinal detachment, with or without vitreous hemorrhage.

The procedure was pars plana vitrectomy, with or without encircling band. Endolaser, scleral buckling, air fluid exchange, silicone oil, and/or lensectomy had been performed at same surgery if had been indicated. After surgery, laser therapy had been performed if had been needed.

After the procedures, patients had been followed up for 6 to 72 months depending on their conditions.

For computerized statistical analysis, all collected data were entered into a data base using EPI-6 software. We used one-tailed paired t-student test for comparing visual acuity results.

RESULTS

In this study, the existing data of 67 eyes of 54 patients were reviewed. Fifty (92.6%) of our patients were male, and 4 (7.4%) were female. Ages of our patients ranged between 19 to 56 years with a mean of 33.9 years, (SD=0.45y). Thirty-eight (70.4%) patients had bilateral involvement, and 16 (29.6%) were unilateral. In unilateral cases, 12 (75%) had left eye involvement and 4 (25%) had right eye involvement. In 55.2% of bilateral cases, involvement of the left eye was more severe.

Symptoms which had caused patient referral were: sudden decrease of visual acuity in 83.3%, blurred vision in 11.1%, and floaters in 5.6% of cases.

Tuberculin test (PPD skin test, 5U) had been performed in 38 cases with positive response (induration more than 10 mm) in 81.7% of them (Fig. 1).

In systemic history of severe headache in two, recurrent nose bleeding in one, severe constipation in one, psychosomatic dis-

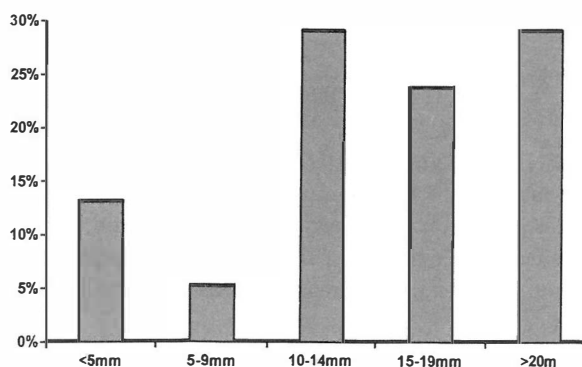


Fig. 1. Results of PPD skin test (size of induration) in 38 patients with complicated Eales' disease treated at LMC from 1988 to 1998.

ease in one, and tuberculous adenitis in one. Six of the cases had eosinophilia more than 5%.

On funduscopic examination, six cases had central proliferative changes, and the rest had only peripheral proliferative changes. Retinal break was found in 3 eyes, and one eye had lattice degeneration.

Forty-three eyes had undergone laser therapy, 23.2% of which later needed additional laser therapy for control of their disease (Table I). Five (11.6%) of these eyes ultimately required deep vitrectomy, one due to vitreous organization, and four due to tractional retinal detachment. Seven of these eyes had previous treatment consisting of laser therapy in five and cryotherapy in two of them.

Twenty-four eyes had undergone vitrectomy, in 9 (37.5%) cases the right eye, and in 15 (62.5%) the left (Table II). Approximately half of these eyes had needed additional treatment. Five (20.8%) eyes had required additional surgery, in two of them for the third time. One of the eyes had become

phthisic secondary to repeated procedures. Vitrectomy had treated one of the eyes with rubeosis iridis, and had regressed retinal vascularization in 4 eyes. However, after three years, vitreous hemorrhage recurred in one of them due to development of neovascularization, which had been controlled with laser therapy.

Complications of vitrectomy were recurrent vitreous hemorrhage in 6, lens opacity in 4, increased intraocular pressure in 2, rubeosis iridis in 2, and giant tear in one. Trabeculectomy had been done in one of the eyes for control of intraocular pressure, and extracapsular cataract extraction had been performed in one eye with severe lens opacity. In the case of giant tear, silicone oil had been used. Visual loss had occurred in 2 eyes, one of which was most probably due to fibrinoid syndrome. Two eyes had inoperable retinal detachment.

Visual acuities of the eyes before and after laser therapy and vitrectomy have been shown in Table III.

Table I. Different laser techniques, previous and additional treatments performed on 43 eyes with complicated Eales' disease in LMC from 1988 to 1998.

Type of laser therapy	No. (%)	Previous treatment		Additional treatment			Vitrectomy
		Laser	Cryo	PRP	Sector	Local	
Local	4 (9.3%)	0	2	2	0	0	1
Sector Scatter	9 (21%)	2	0	2	3	2	1
Mixed	2 (4.7%)	0	0	0	0	0	0
Peripheral	28 (65%)	3	0	6	2	3	3
Total	43 (100%)	5 (11.6%)	2 (4.6%)	10 (23.2%)	5 (11.6%)	5 (11.6%)	5 (11.6%)

Table II. Indications for vitrectomy, eyes involved, previous and additional treatments of 24 eyes with Eales' disease treated at LMC from 1988 to 1998.

Indications for vitrectomy	No. (%)	Eye involved		Previous laser therapy	Additional treatment	
		OD	OS		Vitrectomy	Laser
Non-clearing vitreous hemorrhage	17 (70.8%)	6	11	1	3	6
Tractional RD	7 (29.2%)	3	4	4	2	1
Total	24 (100%)	9 (37.5%)	15 (62.5%)	5 (20.8%)	5 (20.8%)	7 (29.1%)

Table III. Visual acuities of the eyes with complicated Eales' disease before and after laser therapy and vitrectomy performed in LMC from 1988 to 1998.

Visual acuity	Laser therapy		Vitrectomy	
	before	after	before	after
Less than 1/10	7 (16.3%)	4 (9.3%)	12 (50.0%)	5 (20.8%)
1/10- 3/10	3 (7.0%)	4 (9.3%)	2 (8.3%)	7 (29.2%)
4/10- 7/10	10 (23.3%)	9 (21.0%)	7 (29.2%)	3 (12.5%)
8/10 - 11/10	23 (53.4%)	26 (60.4%)	3 (12.5%)	9 (37.5%)
Total	43 (100%)		24 (100%)	

Laser Photocoagulation and Vitrectomy in Eales' Disease

DISCUSSION

Most investigators note a male predominance,^{9,10} while Murphy et al.⁵ in their study of 55 patients in the United States, found that men and women were equally affected. However, the results of our study showed male predominance of Eales' disease with a rate of 92.6%. The peak age of onset of symptoms is 20 to 30 years.¹ Our most prominent age group was 19 to 38 years, which may confirm other studies.

In our study, 70.4% of patients had bilateral involvement, which in 75% of them, the predominant eye was the left. Between 80% and 90% of the patients eventually develop bilateral involvement,¹ and our lower percentage of bilateral involvement may be due to incomplete follow up. Our study also supports the predominance of left eye involvement, which has been reported in the literature.¹¹

Tuberculin (PPD) test was positive in 81.7% of our patients, but we did not have sufficient information regarding their previous BCG vaccination. Others have emphasized a relationship between Eales' disease and tuberculosis.^{9,10} Renie et al.¹² noted in their group of 32 patients that 48% had either tuberculosis or a history of exposure to tuberculosis. However no one has demonstrated any evidence that the ocular changes are related to infection of the eye or retina by tuberculin bacteria.¹³

Renie et al.¹² have reported sensorineural hearing loss in 24%, and vestibuloauditory dysfunction in 50% of their patients with Eales' disease. Also, there are multiple case reports of diseases of the central nervous system in patients with Eales' disease including multiple sclerosis, cerebellar ataxia, myelopathy, and hemiplegia.¹³ Additionally, concomitant immunologic disorders have been reported with Eales' disease.¹⁴ But, there was not any concomitant central nervous system disease or immunologic disorder in our patients with Eales' disease.

In our study, comparing visual acuities of treated patients before and after procedures show that both laser therapy and vitrectomy have improved visual outcomes of patients with complicated Eales' disease. Rate of visual acuities of less than 1/10 had decreased from 16.3% before laser therapy to 9.3% after laser therapy, and from 50% before vitrectomy to 20.8% after vitrectomy till last follow ups. Also, rate of visual acuities of 8/10-11/10 had increased from 53.4% to 60.4% after laser therapy, and from 12.5% to 37.5% after vitrectomy till last follow ups.

We found that additional laser therapy may control recurrent neovascularization in most of the cases (46.4%), but ultimately, some of them (11.6%) may need vitrectomy. Spitznas et al.,⁴ reported that by photocoagulation, in 91% of the patients, the disease could be brought to a morphological standstill over a mean observation time of 5 years after completion of treatment. They also reported that visual acuity remained unchanged or improved in 87% of the

patients after photocoagulation. Their report supports our results of laser therapy.

Near half of our patients (49.9%) who had undergone vitrectomy had required additional treatment by vitrectomy in 20.8%, or laser therapy in 29.1%. So, although vitrectomy is effective in control of the disease, it may be required to be repeated, or completed by laser therapy later.

There are many reports that vitrectomy improves visual acuity in the majority of patients with complicated Eales' disease.^{8,15-17} Shanmugam et al.⁸ reported that 62.4% of eyes at 2 months and 71.8% at 60 months had 6/60 or better visual acuity, and visual acuities for individual cases were quite stable at the 60 month follow up with 78.5% either maintaining or improving upon their 2 month postoperative visual acuity. Gadkari et al.¹⁵ reported that pars plana vitrectomy improved visual acuity in 18 of 25 eyes with unresolving vitreous hemorrhage to 1/60 or better.

Thus, our study showed that both laser therapy and vitrectomy have been effective in control and improvement of visual outcomes of our patients with complicated Eales' disease, and our results were comparable with other authentic series in the literature. Early detection of new neovascularization by closer follow up and treatment may improve visual outcomes of our patients.

REFERENCES

1. Gieser SC, Murphy RP: Eales' disease. In: Ryan SJ, (ed.) Retina. St. Louis: Mosby, pp. 1505-8, 2001.
2. Meyer-Schwickerath G: Eales' disease: treatment with light-coagulation. *Mod Probl Ophthalmol* 4: 10-18, 1966.
3. Magargal LE, Walsh AW, Magargal HO, Robb-Doyle E: Treatment of Eales' disease with scatter photocoagulation. *Ann Ophthalmol* 21: 300, 1989.
4. Spitznas M, Meyer-Schwickerath G, Stephan B: Treatment of Eales' disease with photocoagulation. *Graefes Arch Clin Exp Ophthalmol* 194: 193-8, 1975.
5. Murphy RP, Gieser SC, Fine SL, Patz A: Retinal and vitreous findings in Eales' disease. *Invest Ophthalmol Vis Sci* 27: 121, 1986.
6. Smiddy WE, Isernhagen RD, Michels RG, Glaser BM: Vitrectomy for nondiabetic vitreous hemorrhage. *Retina* 8: 88, 1988.
7. Hui Y, Wang L, Cao X: Vitrectomy for complicated Eales' disease. *Yan Ke Xue Bao* 13(1): 25-8, 1997.
8. Shanmugam MP, Badrinath SS, Gopal L, Sharma T: Long term visual results of vitrectomy for Eales' disease complications. *Int Ophthalmol* 22(1): 61-4, 1998.
9. Elliot AJ: Thirty-year observation of patients with Eales' disease. *Am J Ophthalmol* 80: 404-8, 1985.
10. Spitznas M, Meyer-Schwickerath G, Stephan B: The clinical picture of Eales' disease. *Graefes Arch Clin Exp Ophthalmol* 194: 73-85, 1975.
11. Lesperance FA, Jr: Peripheral retinal vascular abnormalities

- (Eales' disease). In: Lesperance FA, (ed.) Ophthalmic Lasers. C.V. Mosby Co., pp. 315-21, 1989.
12. Renie WA, Murphy RP, Anderson KC, et al: The evaluation of patients with Eales' disease. *Retina* 3: 243, 1983.
 13. Gieser SC, Murphy RP: Eales' disease. In: Albert DM, Jakob FA, (eds.) Principles and Practice of Ophthalmology. Philadelphia: W.B. Saunders Co., pp. 791-5, 1994.
 14. Muthukkaruppan V, Rengarajan K, Chakkalath HR, Namperumalsamy P: Immunological status of patients of Eales' disease. *Indian J Med Res* 90: 351, 1989.
 15. Gadkari SS, Kamdar PA, Jehangir RP, Shah NA, Adrianwala SD: Pars plana vitrectomy in vitreous hemorrhage due to Eales' disease. *Indian J Ophthalmol* 40(2): 35-7, 1992.
 16. Li C, Gao R: Vitrectomy for nondiabetic vitreous hemorrhage. *Yan Ke Xue Bao* 7(2): 95-7, 1991.
 17. Kumar A, Tiwari HK, Singh RP, Verma L, Prasad N: Comparative evaluation of early versus deferred vitrectomy in Eales' disease. *Acta Ophthalmol Scand* 78(1): 77-8, 2000.

