

CLINICAL EVALUATION OF BONE CEMENT AND AUTOGENOUS BONE GRAFT IN DOGS

D. SHARIFI, M.V.Sc., Ph.D., G.R. ABEDI, Ph.D.,
F. SASSANI, Ph.D., D. SAVADKOUHI, M.D.,
J. BAKHTIARI, Ph.D., AND I. NOWROUZIAN, M.P.V.M.

*From the Faculty of Veterinary Medicine,
Tehran University, Tehran, I.R.Iran.*

ABSTRACT

Various biological bone grafts have been used for osteogenesis, osteoconduction and even osteoinduction, but due to systemic influences and local factors, the outcome of successful incorporation of a bone graft has not been satisfactory. This study was therefore conducted on 15 clinically healthy adult dogs between 1 to 3 years of age weighing 20 to 30 kg to evaluate the effect of bone cement and autogenous bone grafts. A piece of 3 cm complete mid-shaft right tibial cortical bone was removed in all animals. Then they were subsequently divided into three groups of 5 animals each. In group I the bone was fixed with a suitable intramedullary pin, whereas the gap was filled with harvested autogenous rib bone graft in group II animals. Bone cement was used to fill the gap in animals of group III for the first 30 days, then it was replaced with iliac bone chips and observation was made accordingly for 60 days in all animals of the three groups. After 60 days, before collection of callus samples, there was granulation and fibrocartilage tissue in groups I and II respectively, whereas a thick fibrous capsule or pseudomembrane layer was seen around bone cement on day 30 before removal of cement and on day 60 after replacement by iliac bone graft in group III animals. There were combinations of heavily impacted fibrous and fibrocartilaginous tissues with thick bundles of collagen fibers among hypertrophic chondroblasts in histomorphological cross section in group I animals, whereas active sequestra were present in group II animals. Fibrotic capsule, periosteal layer, lacunae, osteoblasts, osteocytes and well formed bone marrow with RBC and adipose tissue were noted in group III animals. It appears that the local reaction induced by bone cement leading to fibrotic capsule formation was quite helpful in delaying iliac bone graft resorption and enhancing osteogenic stimulation as to fill the gap with impacted callus with normal cortical structure.

The application of bone cement in gap nonunion, crushed bone and fragmental fractures is therefore highly recommended.

MJIRI, Vol. 16, No. 2, 107-110, 2001.

Keywords: Bone Cement, Autogenous Bone, Graft, Dog.

INTRODUCTION

Bone grafts function as a source for osteogenesis, osteoinduction, osteoconduction and even mechanical sup-

Correspondence: D. Sharifi, M.V.Sc., Ph.D., Associate Professor of Surgery and Radiology, Faculty of Veterinary Medicine, Tehran University, Tehran, I.R. IRAN, 14155-6453, Fax: 0098-21-933222, Tel: 0098-21-6438328.

Bone Cement and Bone Grafting in Dogs

port.^{1,2} Autogenous cancellous bone grafting is indicated when early production of bone and rapid healing is desired.⁹ It is often the determining factor in success (healing) or even failure (nonunion) of the repair. Over the past one or two decades there has been considerable interest in the use of bone grafting in combination with bone cement.^{3,4,5} Methylmethacrylate was used for the first time for artificial denture formation in 1938⁶ and was later on used by Wiltse et al. (1957) for prosthetic joint fixation in animals.²¹ For better functioning of autogenous cancellous bone grafts in large bone gaps the need arises to assess the application of bone cement not only for its mechanical support²¹ but also for inducing additional fibrous tissue at the fracture site as to keep the bone graft completely intact to function well.

MATERIAL AND METHODS

To assess bone cement reaction at the fracture site and

whether it will provoke local fibrocapsule formation or not, the study was conducted on 15 clinically healthy adult dogs between 1 to 3 years of age and 20 to 30 kg body weight to evaluate the effect of bone cement and autogenous bone grafting. A 3 cm piece of bone was removed from the mid-shaft of the right tibial bone in all animals, then they were divided into three groups of 5 animals each. The tibial bone was fixed with a suitable intramedullary pin in group I animals (control), whereas the gap was filled with harvested rib bone in group II animals. Bone cement* was used to fill the gap in group III animals for the first 30 days and then replaced with iliac bone chips and observation was made accordingly for 60 days. For collection of callus samples, animals were anesthetized and 3 cm of bone from the mid-shaft of the right tibia including the grafted area was removed in all animals of the three groups. The samples were placed in 10% citric acid having 1% urea as fixator. Stain-

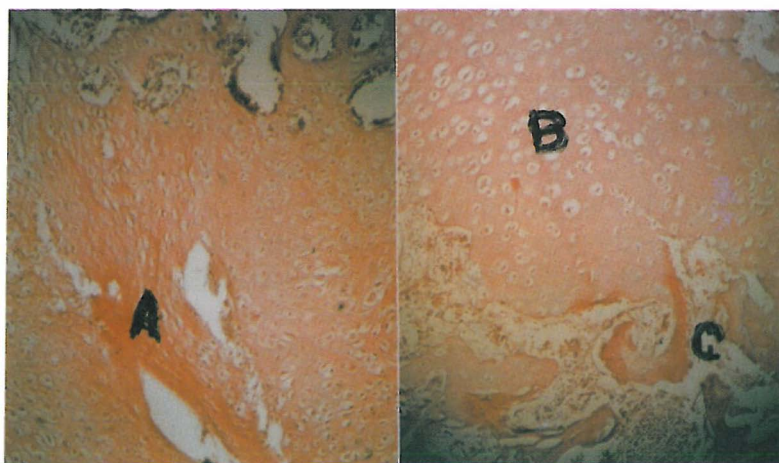


Fig. 1. Histomorphological changes in group I animals. (H&E \times 320).
A) Fibrous tissue. B) Cartilage. C) Newly formed osseous trabeculae.

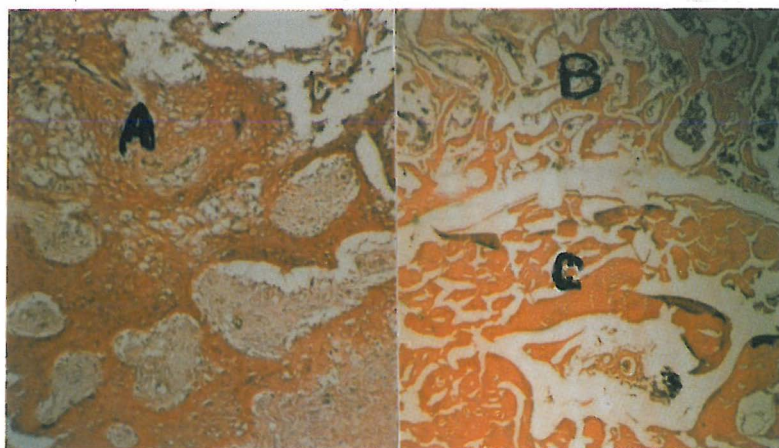


Fig. 2. Histomorphological changes in group II animals. (H&E \times 320).
A) Fibrous tissue. B) Newly formed osseous trabeculae. C) Sequestra of rib bone.

Bone cement (CNW), CNW Laboratories Dentsply. CNW, (Bone cement cat. No. 3012-040. C.N.W. Laboratories Ltd. Falcon Road, Sowton Industrial Estate, Exeter, Devon EX2 7NA. England.

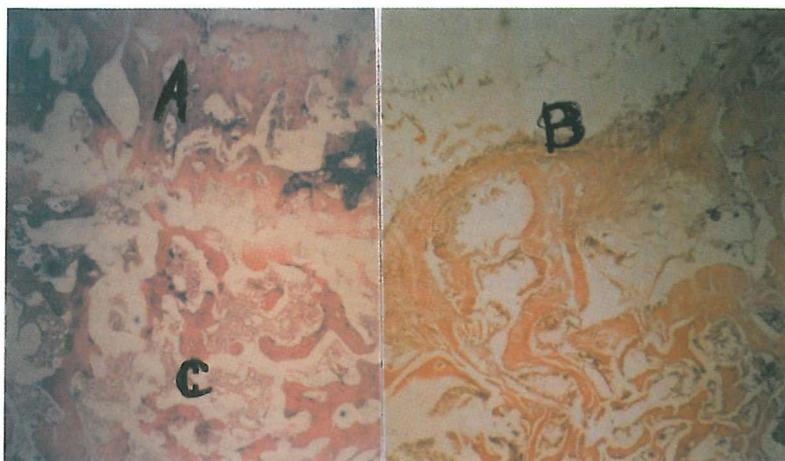

Fig. 3. Histomorphological changes in group III animals. (H&E \times 320). A) Matured osseous trabeculae. B) Fibrous capsule, periosteal layer. C) Newly formed bone marrow.

ing was done using H&E stain.

RESULTS

Grossly, there was granulation and fibrous tissues fully covering the site of callus formation which was pale yellow in color. The elevated callus tissues were observed in all animals of three groups. The callus in group III animals was quite uniform and even, compared to group I and II animals.

Microscopically, there was a combination of heavily impacted fibrous and fibrocartilaginous tissues with thick bundles of collagen fibers beside hypertrophic chondroblasts in group I animals (Fig. 1), whereas active osteoblasts at the margins of bony trabeculae with spongy new bone formation mixed with sequestra were seen in group II animals (Fig. 2). A fibrotic capsule, periosteal layer, lacunae, osteoblasts, osteocytes and well formed bone marrow with RBC, and adipose tissue were noted in group III animals. The local reaction induced by bone cement led to thick fibrotic capsule formation which was subsequently quite helpful in delaying iliac bone graft resorption and enhancing osteogenic stimulation as to fill the gap with impacted callus with normal cortical structure (Fig. 3).

DISCUSSION

Autogenous cancellous bone is the most commonly used bone graft which is readily available and easily harvested, but it lacks mechanical strength.³ Cancellous bone has a greater surface area, because of its spongy structure, which allows for a much greater source of cells for bone formation and a faster rate of penetration of blood vessels to meet the requirements of newly formed bony

tissues.^{1,16} Keeping in view the healing model in group I animals, healing started by accumulation of hematoma, fibrin and red blood cells at the gap, penetration of blood vessels with extension of fibrous tissues into the gap leading to newly formed bony structure containing clusters of blood vessels protruding toward the center of the callus.^{14,19} There was a lot of connective and fibrotic tissues in the gap which was much less in group II and very little in group III animals.¹⁰ In group II and III instead of undifferentiated mesenchymal tissues the grafted gap was replaced by newly formed recipient bone, which was much more condensed and uniformly arranged in group III animals.⁶ The main comparative healing stages in the three groups was the amount of connective tissues replaced at the gap region,¹⁴ so that even if there is very little undifferentiated mesenchymal and fibrotic tissues left over, it will hinder and slow down bone formation. Removal of these tissues is therefore essential for complete and uniform repair.

Histomorphological studies have shown that the use of freshly obtained bone graft² does not need further fixation or immobilization after 60 days of grafting. As the bone plate was removed on day 45 in group III animals a very stable fracture site with fully incorporated graft materials was observed. It is believed that the fibrotic or capsular layer formation around metal and plastic implants will act like a barrier to separate the inner content from surrounding tissues.¹⁴ The replacement of bone cement by iliac bone chips on day 30, due to formation of a thick capsular layer, caused the bone graft to become more functional without being phagocytised.¹⁹ The callus formation in such conditions is shaped as hyaline cartilage due to reduction of the oxygen supply which in long term duration, due to ossification of cartilage, is centrally converted to actual bony callus^{7,17} which is quite

Bone Cement and Bone Grafting in Dogs

obvious in group III compared to group II animals. The results indicate that application of bone graft surrounded by a capsular layer was a quite suitable technique for comminuted diaphyseal fracture in the dog. In fact this technique is quite simple, reliable and easily applicable and requires minimum time with the least local complications.

Application of autogenous cancellous bony graft has been highly recommended in open, closed freshly open fractures, bony defects, non-union and even osteomyelitis.^{13,18,20} In order to keep the bone graft more functional at the site of the grafted area, the capsular layer acting as an external protective sleeve or coverage is highly useful as the freshly harvested cancellous cells can remain alive during the period of transfer from the donor to the recipient bed beside other non-cellular osteoinduction factors participating in the osteogenesis of the grafted area.^{9,15}

ACKNOWLEDGEMENT

The authors wish to thank the Faculty of Veterinary Medicine and Tehran University Research Council for approval and providing financial assistance for completing this research.

REFERENCES

1. Aron DN, Palmer RH, Johnson AL: Biologic strategies and a balanced concept for repair of highly comminuted bone fractures. *Compendium of Continuing Education* 17: 32-49, 1992.
2. Basset CAL: Clinical implications of cell function in bone grafting. *Clin Orthop Rel Res* 87: 49-59, 1972.
3. Beaumont P: Fracture of acrylic bone cement. *Lancet* 860, 1970.
4. Charnley J: *Acrylic Cement in Orthopaedic Surgery*. Baltimore: Williams and Wilkins, p. 65, 1970.
5. CMW Laboratories, Dentsply. Limited. Information Booklet, Bone Cement Division, Clifton Road, Blackpool, FY4, UQF, England, 1995.
6. Crozzoli NR: Bone Cement. *Minerva Orthop* 16: 395, 1965.
7. DeVries WJ, Runyon CL: Effect of volume variations on osteogenic capabilities of autogenous cancellous bone graft in dogs. *Am J Vet Res* 57 (10): 1501-1505, 1996.
8. Gray LC, Elves MW: Osteogenesis in graft after short term storage and topical antibiotic treatment. *J Bone Joint Surg* 63: 441-445, 1981.
9. Grover RK, Sobti VK: Clinical, haematological and radiological evaluation of fragmented autogenous cortical bone grafting of radius in dogs. *J Vet Med A* 45: 303-308, 1998.
10. Johnson KA, Bellenger CR: The effect of autogenous bone grafting on bone healing after carpal arthrodesis in the dog. *Vet Rec* 107 (5): 126-132, 1980.
11. Nunamaker DM, Rhinelander FW: Bone grafting. In: Newton CD, Nunamaker DM (eds.), *Small Animal Orthopedics*, Philadelphia: Lippincott, pp. 443-459, 1985.
12. Olds RB, Sinibaldi KR, Deangelis M: Autogenous cancellous bone grafting in small animals. *J Am Hosp Assoc* 9: 424-427, 1973.
13. Olds RB, Sinibaldi KR, Deangelis M: Autogenous cancellous bone grafting in difficult orthopaedic cases. *J Am Anim Hosp Assoc* 9: 430-432, 1973.
14. Penwick RC, Mosier DA, Clark DM: Healing of canine autogenous cancellous bone graft donor sites. *Vet Surg* 20 (4): 229-234, 1991.
15. Ray RD, Sabet TY: Bone graft cellular survival versus induction. *J Bone Joint Surg* 45: 337-344, 1963.
16. Ray RD: Vascularization of bone grafts and implants. *Clin Orthop Rel Res* 87: 43-47, 1972.
17. Weisbröder SE, Doige CE: Bone and Joints. In: McGavin MD, Carlton WW, Zachary JF, (eds.), *Thomson's Special Veterinary Pathology*. 3rd ed., Missouri, USA: Mosby, pp. 499-536, 2001.
18. Vander Weken CHR, Marti RK: Bone transplantations. *Injury* 13: 271-278, 1983.
19. Weigel JP: Bone grafting. In: Bojrab MJ, (ed.) *Disease Mechanisms in Small Animal Surgery*. Philadelphia: Lea & Febiger, 1993.
20. Wilson J, Hofle W: Diaphyseal allograft. Eight year evaluation in a dog. *Vet Comp Orthop Traum* 3: 72-81, 1990.
21. Wiltse LL, Hall RA, Stenehjem JC: Experimental studies regarding the possible use of self-curing acrylic in orthopaedic surgery. *Journal of Bone and Joint Surgery* 39: 961-972, 1957.