

## Assessment of the clinical outcome of IM rod fixation in the treatment of tibial congenital pseudoarthrosis

Seyed Abas Behgoo<sup>1</sup>, MD. Mehdi Ramezan Shirazi<sup>2</sup>, MD., Hajir Gharati<sup>3</sup>, MD.

*Dept. of Orthopedic Surgery, Shafa Yahyaian Hospital, Iran University of Medical Sciences, Tehran, Iran.*

### Abstract

**Background:** Pseudoarthrosis of the tibia poses one of the most challenging treatment problems in all of orthopedics. The goal of the study was to assess the clinical outcome of intramedullary rod fixation in its treatment.

**Methods:** The results of the management for nine patients with pseudoarthrosis of the tibia with IM rod fixation were reviewed retrospectively between 1986 - 2006. The mean duration of follow up was 8.95 years (range, 3.5 months to 14.2 years). The mean age of the patients at the latest follow up was 13.5 years (range, 9 to 23 years).

**Results:** Initial union of the fracture site occurred in seven of nine patients with the mean duration of 7.6 months (range, 3.5 to 15.5 months). Five patients had limb length discrepancy with the mean of 7.2 cm (range, 1.5 - 12 cm). Three of them were treated with tibia lengthening procedure with the Ilizarov method. One had a peroneal nerve palsy postoperatively. Two patients had refracture treated with casting and rod exchange. Electrical stimulation was applied in two patients but it was impossible to predict how much it played a role in the union.

**Conclusion:** IM rod fixation technique has a satisfactory functional outcome. The technique has a high level of acceptance by parents and patients. It should be recommended as the treatment of choice for the management of congenital pseudoarthrosis of the tibia.

### Keywords

Intramedullary rod, congenital pseudoarthrosis

### Introduction

Dysplasia of the tibia is one of the most challenging treatment problems in all of orthopedics. Interestingly, this rare condition with an incidence of 1 in 140000 to 190000, has received lots of attention in orthopedic literature [1,2].

Although the presence of neurofibromatosis does not appear to affect the union and the final outcome of the lesion [2,3], up to 55% of those with anterolateral bowing and pseudoarthrosis

are associated with neurofibromatosis [2-4].

Treatment options are both operative and nonoperative although the highest rate of success in initial union reported after surgery [6] including intramedullary fixation, vascularized fibular graft, external fixation & distraction osteogenesis [7]. Despite success in surgical methods [9,12,13], the future outcome and function of the involved extremity remain uncertain. This is due to the lack of long - term follow up studies in the different surgical approaches [8,10,11].

Since 1986, intramedullary rod fixation com-

1. Assistant Professor of Orthopedic Surgery, Iran university of Medical Sciences, Tehran, Iran.

2. **Corresponding author**, Resident of Orthopedic Surgery, Shafa Yahyaian Hospital, Baharestan Sq., Tehran, Iran. Tel: +9821 22851923, E-mail: Mehdi.shirazi@yahoo.co.uk

3. Resident of Orthopedic Surgery, Shafa Yahyaian Hospital, Tehran, Iran.

bined with curettage of the pseudoarthrosis and bone graft without any fibular manipulation was done in our center. In contrast to other technique, it was performed without complete excision of the pseudoarthrosis.

Due to lack of defined criteria in the literature for the surgical approach, this study explored the long - term results of IM rod fixation for the pseudoarthrosis of the tibia.

## Methods

Retrospectively, we reviewed the outcome of IM rod fixation of pseudoarthrosis of the tibia in nine consecutive patients at Shafa Yahyaian Hospital between 1986 - 2006. The mean age of patients was 13.5 years (range, 9 - 23 years) at the time of the latest follow up and 5.3 years (range, 3 - 10 years) when the surgery was performed. Five patients were male and four female. Six patients had different operations on the affected extremity prior to the referral to our hospital (Table 2). Five patients had limb length discrepancy (1.5-12 cm). Electrical stimulation was done as adjunctive treatment in two patients. Six patients had right tibia involvement and three cases had left. Neurofibromatosis was detected in six cases whereas three had no associated condition. The mean duration of follow - up was 8.95 years (range, 3.5 months to 14.2 years) (Table 1).

Classification systems describing prognostic radiographic characteristics have been proposed by many authors [1,2,14,15]. But none of them provided any clue for better management or final outcome. Therefore, we have relied on two simple criteria to initially classify congenital tibial pseudoarthrosis: 1. The presence or absence of a fracture; 2. The age at which fracture first occur ("early onset - before the age of four and delayed onset - after four years"). Based on this classification, seven pseudoarthrosis had early onset and the remaining two cases late onset pseudoarthrosis (Table 2).

Postoperatively, all patients were visited regularly and anteroposterior and lateral plain x -

rays were taken to check fracture site union and any possible deformity. At all follow - ups, patients were examined by the senior author. The goal of every follow - up was to assess the formed union radiographically and the complications including infection, presence of refracture and limb length discrepancy.

## Treatment Protocol

The same surgical method was applied for all nine patients with slight difference in two of them.

Patients were placed in a supine position and a tourniquet applied to the proximal part of the involved limb. The entire affected extremity and ipsilateral iliac crest were prepared and draped. Curettage was done by making an anterior incision on the pseudoarthrosis site. An intramedullary rod was inserted from the distal fragment side (In two cases, the rod was placed in the proximal metaphyseal part of involved tibia). The rod typically transfixes the ankle joint and was driven retrogradely into the proximal fragment. To confirm the exact location of the distal end of the indwelling rod, the control x - ray was taken intraoperatively.

Then, the previously harvested bone graft was placed around the pseudoarthrosis site. The subcutaneous tissue and skin were closed in two layers after placing a suction drain over the site. After dressing, a long leg splint was applied. All patients were then treated with a long leg cast after a few days and a custom - fabricated KAFO was strongly recommended to patients after removal of the cast.

## Results

The IM rod fixation was a successful technique in achieving initial consolidation of the congenital tibia pseudoarthrosis in seven of nine patients. The initial union of the fracture site was formed with a mean of 7.6 months (range, 3.5 to 15.5 months) (Table 1).

Electrical stimulation was also used in two patients in order to promote healing and consol-

Cases	Age at latest follow up (Yrs)	Mean duration of postop follow up (Yr + Mo)	Initial Union (+/- ; Mo later)	Refracture	Limb Length Discrepancy (+/-; Cm)	Other Associated Condition	Fibular Pseudoarthrosis +/-
1	13	9 + 9	+; 4 mo	-	+; 1.5	Neurofibromatosis	-
2	22	14 + 2	+; 5 mo	-	+; 9	Neurofibromatosis	-
3	10	3 + 3	+; 3.5 mo	-	-	Neurofibromatosis	+
4	9	0 + 3.5	+; 5.5 mo	-	-	Neurofibromatosis	-
5	10	7 + 4	+; 8 mo	+	+; 5	-	-
6	14	8 + 4	-	-	-	Neurofibromatosis	-
7	23	13 + 10	+; 12 mo	-	+; 8.5	Neurofibromatosis	+
8	9	4 + 3	-	-	-	-	+
9	12	9 + 5	+; 15.5 mo	+	+; 12	-	-

Table 1. Clinical and radiographic data on the nine patients

idation of the fracture site.

Following the initial treatment of pseudoarthrosis, refracture occurred in two patients treated with casting and rod exchange (Table 1). The one treated with casting did not referred for follow - up. There were 4 rod exchanges in the above patient due to refracture, wound infection, and deformity.

Three of nine patients had fibular pseudoarthrosis at the time of diagnosis and none of them had any surgery on their fibula. Five patients had a clinically limb length discrepancy at the mean of 7.2 cm (range, 1.5 to 12 cm) (Table 1) and three of them were treated with tibia lengthening procedure with Ilizarov method. Peroneal nerve palsy was found post-operatively in one patient.

In one patient, a new tibial pseudoarthrosis

developed in the proximal part of the tibia above the rod which was treated with a brace.

### Discussion

As stated previously, treatment of congenital pseudoarthrosis of the tibia could be quite challenging and its true success can not be determined unless the patient was followed until skeletal maturity [17]. Due to the nature of the condition, nonunion of the pseudoarthrosis can occur easily. On the other hand, the high incidence of limb shortening, refractory deformities can lead to amputation in many patients.

The IM rod fixation has been rarely used in Iran and most surgeons prefer using the vascularized fibular graft and external fixation with Ilizarov method. Therefore, the purpose of the study was to highlight IM rod fixation clinical

Cases	1	2	3	4	5	6	7	8	9
Age at 1 <sup>st</sup> fracture (Yrs)	1	2	5	3	1	2 months	6	2	1.5
Prior treatment	Plating/ BG/ electrical stimulation	Wiring (*)	T.F Fracture-CRIF	Ilizarov App./ Vascularized ipsilateral fibula transplantation	-	Dual onlay BG	-	Cast	-
Involvement Side (L/R)	L	R	R	R	R	R	L	L	R

\*Wiring was performed as a treatment in Afghanistan.

Table 2. Illustration of the side of involvement, any previous treatment and the age at which the first fracture was detected

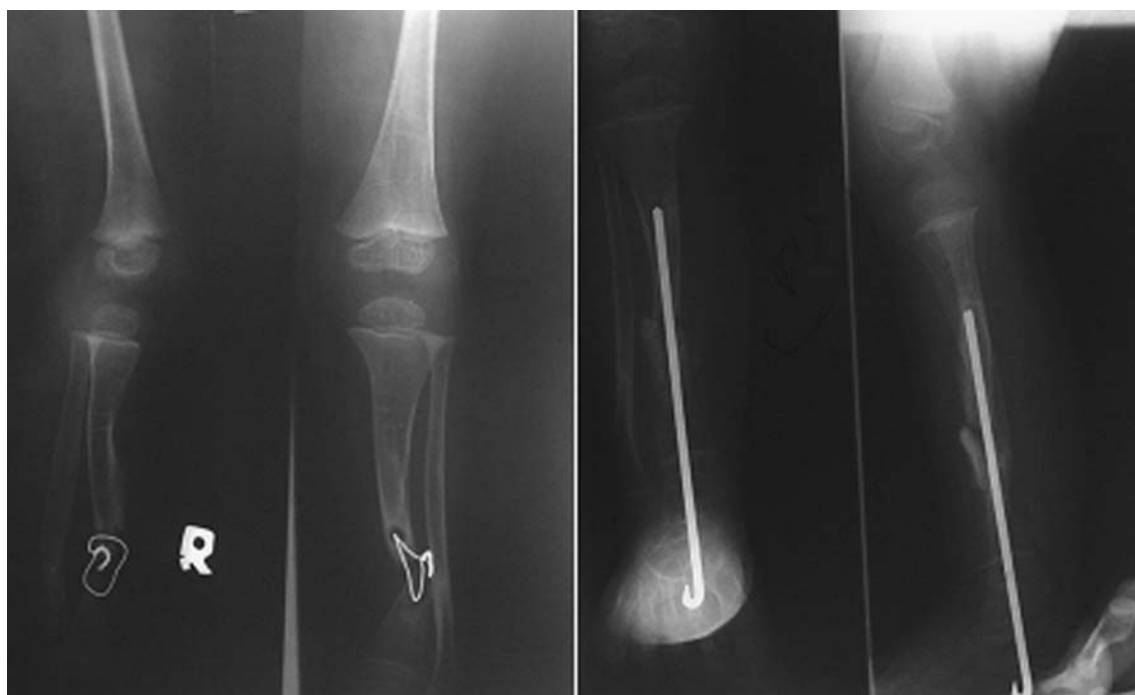

Fig. 1. Case 2: A patient with an early onset congenital pseudoarthrosis of the right tibia who was first treated unsuccessfully with wiring in Afghanistan. Preoperative and postoperative x - ray after IM rod fixation was performed.

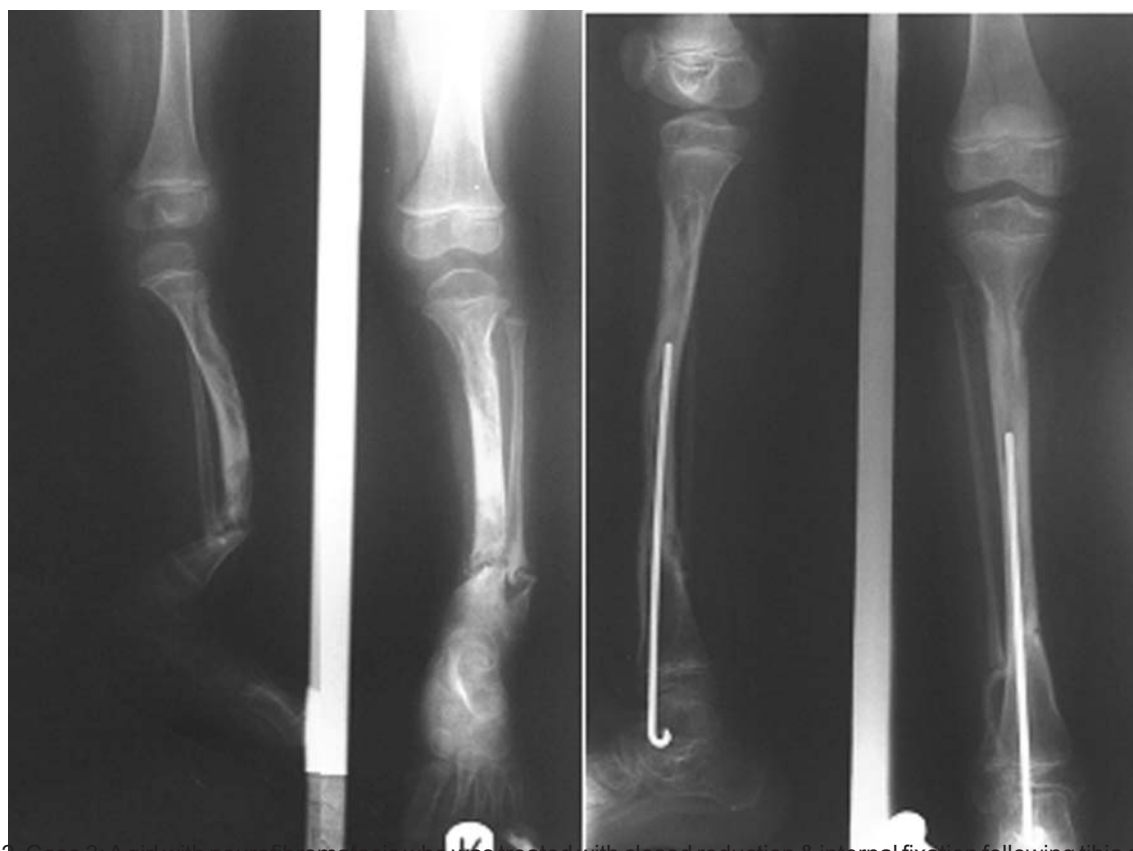


Fig. 2. Case 3: A girl with neurofibromatosis who was treated with closed reduction & internal fixation following tibia and fibula fracture at the age of 5 years. Due to nonunion of the fracture site, IM rod fixation was performed about 1.5 years later.

outcome in congenital pseudoarthrosis of the tibia.

Concerning surgical techniques, aggressive resection of pseudoarthrosis lesion appeared to have significant improved union rates over curettage of the site in the series by Ohnishi et al [21]. Unlike Ohnishi, we performed curettage of the pseudoarthrosis site in all cases and achieved union in seven of nine patients (Table 1).

Refracture is a common finding in patients with congenital pseudoarthrosis of the tibia and it occurred in two patients in our study (Table 1). Both patients had early onset pseudoarthrosis of the tibia. This finding is consistent with the findings of Roach et al [18], Kim and Weinstein [19] in which the late onset pseudoarthrosis was a more benign form of the condition.

Whether any fibular surgery is necessary, it will remain a controversial issue. In accordance with the study of Johnston [20], the fibular pseudoarthrosis resection is strongly recommended. If fibula is intact, performing a fibular osteotomy is crucial in order to achieve the alignment and union. The fibular pseudoarthrosis resection and fibula osteotomy were performed in none of our patients. In contrast to Johnston, no refracture was found in those who had fibular involvement without surgery (Table 1). Since we did not perform surgery on the intact fibula, it is impossible to draw conclusions on the clinical results of doing an osteotomy for an intact fibula.

The limb length discrepancy was another complication induced due to the disease and also treatment of the tibial congenital pseudoarthrosis. Obvious causes of shortening of the tibia included acute shortening at the time of pseudoarthrosis resection, and damage to the distal tibial physis from multiple operations and crossing of the intramedullary device. The complication was clinically detected in five of nine patients. Different types of treatment such as appropriately timed contralateral femoral and/or proximal tibial epiphysiodesis, and tib-

ial lengthening procedure have been recommended. We, successfully, performed the latter procedure in three of five patients despite one of them was complicated by peroneal nerve palsy.

One of the associated conditions with congenital pseudoarthrosis of the tibia is neurofibromatosis. In our study, six of nine cases had the condition (Table 1). Nonunion occurred in one of them. Since the numbers of patients were too small, any conclusion on the incidence of union or the ultimate outcome of the tibial pseudoarthrosis can not be drawn.

### Conclusion

The IM rod fixation technique had satisfactory functional results, and high level of acceptance by parents and patients. When it is unsuccessful, other surgical methods including vascularized bone graft, and external fixation & distraction osteogenesis are applicable. This technique should be recommended as the treatment of choice for the management of tibial congenital pseudoarthrosis.

### References

1. Andersen KS. Congenital pseudoarthrosis of the leg, Late results. *J Bone Joint Surgery Am*; 1976; 58: 657.
2. Crawford AH, Schorry EK: Neurofibromatosis in children: The role of the orthopaedist. *J Am Orthop Surg* 1999; 7: 217.
3. Sponseller PD. Localized disorders of bone and soft tissue. In Morrissy RT, Weinstein SL (eds): *Pediatric Orthopaedics*, Vol 4. Philadelphia, Lippincott - Raven 1996; p 305.
4. Strong ML, Wong-Chung J. Prophylactic bypass grafting of the prepseudarthritic tibia in neurofibromatosis. *J Pediatr Orthop* 1991; 11: 757.
5. Whitehouse D. Diagnostic value of the café - au - lait spot in children. *Arch Dis Child* 1966; 41: 316.
6. Dobbs MB et al; Intramedullary fixation for congenital pseudoarthrosis of the tibia. *JBJS Am* 2004; 86 - A(G): 1186 - 97.
7. Herring JA. Tachdjian's pediatric orthopaedics, 4th edition. Saunders WB, 2008; pp. 1010 - 1021.

8. Kanaya F, Tsai TM, Harkess J. Vascularized bone graft for congenital pseudoarthrosis of the tibia. *Microsurgery* 1996; 17: 459 - 71.
9. Umber JS, Moss SW, Colemann SS. Surgical treatment of congenital pseudoarthrosis of the tibia with pulsing electromagnetic field. A survey of 52 cases. *Clin Orthop* 1982; 166: 45 - 57.
10. Dormans JP, Krajbich JI, Zuker R, Demuynek M. Congenital pseudoarthrosis of the tibia: Treatment with free vascularized fibular grafts. *J Pediatr Orthop* 1990; 10: 623 - 8.
11. Boero S, Catagni M, Donzelli O, Facchini R, Frediani PU. Congenital pseudoarthrosis of the tibia associated with neurofibromatosis- 1: Treatment with Ilizarov's device. *J Pediatr Orthop* 1997; 17: 675 - 84.
12. Anderson DJ, Schoenecker PL, Sheridan JJ, Rich MM. Use of an intramedullary rod for the treatment of congenital pseudoarthrosis of the tibia: *J Bone Joint Surg Am* 1992; 74: 161 - 8.
13. Hagan KF, Buncke HJ. Treatment of congenital pseudoarthrosis of the tibia with free vascularized bone graft. *Clin Orthop* 1982; 166: 34 - 44.
14. Boyd HB. Pathology and natural history of congenital pseudoarthrosis of the tibia. *Clin Orthop Relat Res*, 1982; 166: 5.
15. Tachdjian MO. Congenital pseudoarthrosis of the tibia. In Tachdjian MO (ed): *Pediatric Orthopaedics*, 2nd ed. Philadelphia, Saunders WB 199; p.656.
16. Karol LA, Haideri NF, Halliday SE et al. Gait analysis and muscle strength in children with congenital pseudoarthrosis of the tibia: The effect of treatment. *J Pediatr Orthop* 1998; 18: 381.
17. Boyd HB. Pathology and natural history of congenital pseudoarthrosis of the tibia. *Clin Orthop* 1982; 166: 5 - 13.
18. Roach JW, Shindell R, Green NE. Late - onset pseudoarthrosis of the dysplastic tibia. *J Bone Joint Surg Am* 1993; 75: 1593 - 601.
19. Kim HW, Weinstein SL. Intramedullary fixation and bone grafting for congenital pseudoarthrosis of the tibia. *Clin Orthop* 2002; 405: 250 - 7.
20. Johnston CE. Congenital pseudoarthrosis of the tibia: Results of technical variations in the Charnley - Williams procedure. *J Bone Joint Surg Am* 2002; 84: 1799 - 810.
21. Ohnishi I, Sato W, Matsuyama J, et al. Treatment of congenital pseudoarthrosis of the tibia: A multicenter study in Japan. *J Pediatr Orthop* 2005; 25: 219.