

# GIANT HAMARTOMA OF THE BREAST: REPORT OF A CASE AND REVIEW OF THE CURRENT LITERATURE

D. FARROKH, M.D.

*From the Department of Radiology, Imam Reza Medical Center, Mashhad University of Medical Sciences,  
Mashhad, Islamic Republic of Iran.*

## ABSTRACT

Hamartoma of the breast is a rare benign breast lesion which is unfamiliar to most clinicians, although the mammographic features are usually characteristic. Hamartomas are composed of ducts, lobules, fat and fibrous tissue. These benign lesions are likely to be increasingly diagnosed because of routine screening and hence clinical awareness is paramount to prevent these lesions from being over-treated.

A patient who presented with a soft mobile breast lump which was later diagnosed to be a giant breast hamartoma is presented along with a brief review of the current literature.

*MJIRI, Vol. 14, No. 2, 187-189, 2000.*

## INTRODUCTION

Breast hamartomas are relatively rare benign tumor-like lesions which result more from breast dysgenesis than from tumoral process. Histologically, they are composed of fibrous tissue, fat, lobules and ducts.

Previous mammographic reports have characterized these lesions as well-delineated masses composed of fibroglandular and fatty tissue.<sup>10</sup> Surgical excision can usually be avoided when a classic appearance of a well-circumscribed mass clearly characterized by fatty and glandular tissue density is noted on the mammogram.<sup>9</sup>

These benign lesions may go unrecognized by the pathologist because they show all the constituents of normal breast tissue and may be reported as "no pathological diagnosis" or "normal breast tissue", which are inappropriate diagnoses for a lesion that presents as a palpable well-circumscribed mass.<sup>9</sup>

## CASE REPORT

A 28 year old woman was admitted in October 1998 because of a soft palpable left breast lump. In physical examination, there was a large clinically palpable mass thought to be approximately 10 cm in size in the inner lower quadrant of her left breast, causing considerable asymmetry of her breasts. The mass wasn't painful, had a firm consist-

ency and there was no nipple or skin abnormality.

Ultrasonography didn't show any discrete mass lesion, although the mass was completely palpable. So a mammogram was performed which demonstrated a large well-defined mass occupying almost one-quadrant of the breast. The mass was confined by a thin capsule, and appeared to contain fat and multiple small soft tissue densities-the typical radiographic appearance of a breast hamartoma.

In September 1998, surgical excision was performed because of the large size of the mass in her left breast. The cut surface of this well-circumscribed mass measured 10 cm × 7 cm. The microscopic appearance was characteristic of breast hamartoma, with a sharp circumscribed "pseudocapsule" surrounding breast fibroconnective tissue with variable amounts of glandular elements and adipose tissues.

## DISCUSSION

The breast hamartoma, also known as the lipofibroadenoma or fibroadenolipoma,<sup>1,10</sup> is a rare benign lesion of the breast. There have been few reviews of this entity in the literature. This pathologic entity consists of a well circumscribed benign mass composed of variable amounts of glandular tissue, fat, and dense fibro-connective tissue with associated ducts.<sup>5,11</sup> Many pathologists will not recognize the entire lesion, but only the adenomatous

portion, which will be called simply fibroadenoma.

Pathologically, the variable proportion of fat and fibrous connective tissue results in variation of the gross appearance of the tumor. Tumors that are largely fibrous have a white to gray cut surface with a firm rubbery texture. In contrast, tumors with larger proportions of fat are yellow or mottled yellow-gray and have a texture more comparable to that of the normal breast.<sup>1</sup>

The microscopic appearance of breast hamartomas correspond to their gross appearance.<sup>4,7</sup> Lesions that are grossly firm, rubbery, and white consist largely of dense fibroconnective tissue with variable amounts of glandular elements with little adipose tissue. Softer, pale, and yellow lesions contain more adipose tissue. A consistent and important diagnostic feature is the presence of lobules and ducts, in contrast to fibroadenoma in which lobules are often absent or rare.<sup>4,7</sup> In most hamartomas microscopic findings usually parallel the radiographic pattern specifically; if the tumor appears uniformly dense, the microscopic pattern is uniformly fibrous, and if the tumor has a heterogeneous appearance, the microscopic pattern is fibrofatty.

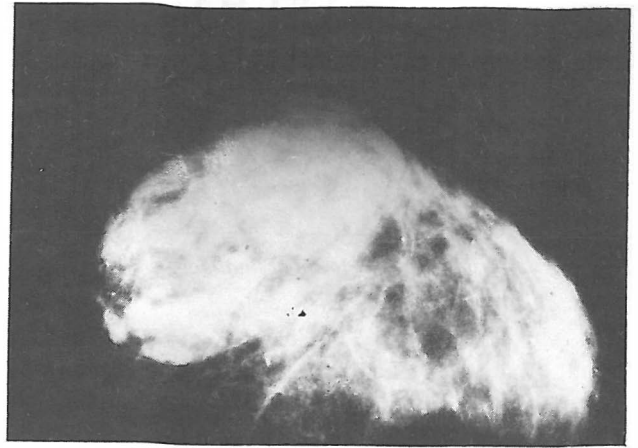
The pathologic diagnosis of breast hamartoma is usually difficult, and many studies emphasize that fine needle aspiration and cytology of the smears is not diagnostic for hamartomas.<sup>8</sup>

Breast hamartomas usually occur in young women, but may occur after menopause. Patients often present with a palpable breast nodule or mass, which may be first detected during self examination or by a physician. The lesion may present as a large soft well-defined lump, causing considerable asymmetry of the breast.<sup>14</sup>

Some authors have debated the role of pregnancy and lactation in the pathogenesis of hamartomas. It may be that the changes in breast size after pregnancy facilitates the discovery of hamartomas.<sup>10,11</sup>

Mammographically, hamartomas have been described by Hessler et al.<sup>10</sup> as having a characteristic appearance of a well-circumscribed mass composed of dysplastic mammary tissue mixed with fat. In 1978 Crothers<sup>5</sup> in a review of breast hamartomas, noted generally large, well circumscribed masses of mixed density, but stressed the absence of a true capsule. Indeed the lesion is surrounded by a fibrotic pseudocapsule.

Breast hamartomas may have a specific radiographic appearance that, when present, should not be missed.<sup>9,10</sup> In mammography, the hamartoma usually presents as a round or oval mass with a thin walled pseudocapsule, containing primarily fat. Interspersed in the fat are multiple masses with soft tissue density. These small masses usually represent fibroadenomas. At times the fibroadenomas appear to make up the major portion of the mass.<sup>6,10</sup> The composition of these lesions may vary from very lucent (may be confused with a lipoma) to nearly totally dense (may be confused with a fibroadenoma).<sup>9</sup> Hamartomas may also be



**Fig. 1.** Axillary view of the breast demonstrates a large well-circumscribed mass in the lower portion. The mass has mixed density and the suggestion of a capsule, which are classic mammographic findings of a hamartoma.

detectable as nonspecific mammographic masses.<sup>9,15</sup>

A study by Helvis showed that on mammography, about 47% of these lesions had a characteristic appearance, 35% were nonspecific nodules (smooth bordered, round or oval shaped, mixed or uniform density, but not typical for hamartoma) and 18% were suspicious (mixed density, but ill-defined borders) and sometimes mimicked malignant breast lesions.<sup>9</sup>

Another finding is that as the lesion enlarges, surrounding breast tissue is compressed. These lesions may or may not have a halo, which is attributed to compressed surrounding fat.<sup>15</sup>

It appears that many hamartomas can be clearly identified via breast ultrasound. The breast sonographer should be aware of the spectrum of appearances that may occur.<sup>3</sup> The sonographic appearance is not specific. Review of the literature shows that the most frequent sonographic appearance of breast hamartoma is a somewhat heterogeneous hypoechoic mass, enhanced through transmission with distal shadowing.<sup>1,13</sup>

Mendelson reports that hamartomas may show increased or mixed echogenicity and posterior shadowing.<sup>12</sup> Sometimes the mass is slightly hypoechoic and almost blends into the background breast parenchyma. In this type, sonography usually is negative although the mass is palpable.<sup>7</sup>

When a breast abnormality has the mammographic appearance of a hamartoma, it may be counterproductive to perform additional breast ultrasound.<sup>3</sup>

Breast hamartoma is a benign lesion, but will continue to grow; some have been found to be as large as 70 cm in diameter.<sup>10</sup> There are no reported cases of malignancy. In summary, if in a mammography, a breast mass contains areas of fatty and fibroglandular densities surrounded by a fibrotic pseudocapsule, it is a hamartoma.<sup>9</sup>

The pathologist should be alerted to the radiographic diagnosis when these lesions are removed, as they are sometimes difficult to remove intact, and a correct histologic report may not be made.<sup>10</sup> Indeed a correct diagnosis of hamartoma relies on clinical, radiological and pathological criteria.

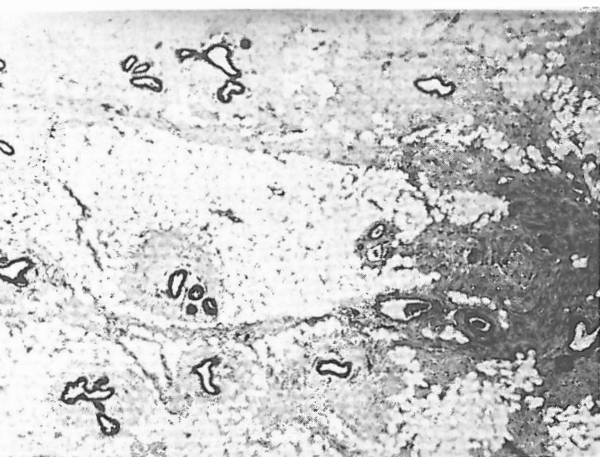

Fig. 2. Histologic specimen shows an adenolipomatous hamartoma with predominant fatty component, which created the appearance of mixed density in mammography (Hematoxylin-Eosin, ×58).

#### REFERENCES

Addler DD, Jeffries DO: Sonographic features of breast hamartomas. *J Ultrasound Med* 9: 85, 1990.  
 Anani PA, Hessler C: Breast hamartoma with invasive ductal

carcinoma. Report of two cases and review of the literature. *Pathol Res Pract* 192(12): 1187-94, 1996.  
 3. Black J, Metcalf C, Wylie EJ: Ultrasonography of breast hamartomas. *Austral Radiol* 40(4): 412-5, 1996.  
 4. Charpin C, Mathoulin MP, et al: Reappraisal of breast hamartomas. *Pathol Res Pract* 190(4): 362-71, 1994.  
 5. Crothers JG, Butler NF, Fortt W: Fibroadenolipoma of the breast. *Br J Radiol* 58: 197-202, 1985.  
 6. Daroca PJ, Reed RJ: Myoid hamartomas of the breast. *Hum Pathol* 16: 212-219, 1985.  
 7. Daya D, Trus J, et al: Hamartoma of the breast. An underrecognized breast lesion. *Am J Clin Pathol* 163(6): 685-9, 1995.  
 8. Gogas J, Malkopoulos C, et al: Hamartomas of the breast. *Am Surg* 60(6): 447-50, 1994.  
 9. Helvis M, Adler D, et al: Breast hamartomas, variable mammographic appearances. *Radiology* 170: 417-421, 1989.  
 10. Hessler C: Hamartoma of the breast. Diagnostic observation in two cases. *Radiology* 126: 95-98, 1988.  
 11. Ljungqvist U, Anderson L, et al: Mammary hamartoma, a benign breast lesion. *Acta Chir Scand* 145: 227-230, 1979.  
 12. Mendelson EB: Breast sonography. In: *Syllabus for the Categorical Course in Breast Imaging*. American College of Radiology, Reston VA., p. 31, 1990.  
 13. Scherstone BY, Wells CA: Mammographic appearance and histopathological description of a muscular hamartoma of the breast. *Br J Radiol* 58: 459-461, 1985.  
 14. Thirumavalavan VS, Ruffaie AL: An uncommon benign breast tumor-hamartoma. *Br J Clin Prac* 47(1): 44-5, 1993.  
 15. Vas W: Mammographic diagnosis of mammary hamartoma. *J Can Assoc Radiol* 37: 208-209, 1980.  
 16. Williams NP, Williams E: Mammary hamartoma: an under-recognized breast lesion. *West-Indian Med J* 45(2): 67-69, 1996.

Downloaded from mji.iums.ac.ir at 19:48 IRST on Saturday, November 18th 2017

