

Brief Communications

CONGENITAL TRICHOFOLLICULOMA: A CASE REPORT

Keyword: *Trichofolliculoma*

MJIRI, Vol. 13, No. 1, 81, 1999

A rare case of congenital trichofolliculoma of the scalp is reported in a 6 year old girl. The patient was a 6 year old Iranian girl with a 1×1 cm sized pink colored papule with some white hairs on the vertex of the scalp, which seemed to be a kind of follicular hamartoma (Fig. 1). The papule had been present since birth, and her two brothers had no past history of similar lesions.

Histopathological study revealed the papule to be a well-formed dilated hair follicle at the central pore of the tumor, where keratin debris and vellus hairs were present. In addition, epithelial cells had formed long thin strands of immature follicle-like structures that had proliferated multifocally from the epidermis of the wall of the central follicle to the peripheral epidermis (Fig. 2).

Congenital trichofolliculoma is rare. A case of congenital trichofolliculoma on the right cheek of a 3 month old boy has been reported before.¹ Trichofolliculoma of the external auditory meatus² and the eyelid have also been described previously.³

FARIBA IRAJI, M.D.,
FARAHNAZ FATEMI, M.D.

*From the Department of Dermatology, Shahid Beheshti Hospital,
Isfahan University of Medical Sciences, Isfahan, I.R. Iran.*

REFERENCES

1. Ishii N, Kawaguchi H, et al: A case of congenital trichofolliculoma. *J Dermatol* 19(3): 195-6, 1992.
2. O'mahony JJ: Trichofolliculoma of the external auditory meatus. *J Laryngol Otol* 95(6): 623-5, 1981.
3. Carreras B, et al: Trichofolliculoma of the eyelid. *Br J Ophthalmol* 65(3): 214-5, 1981.

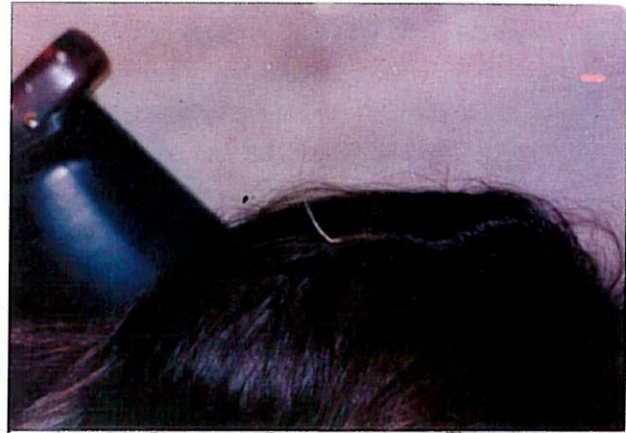

Fig. 1. Trichofolliculoma. The white tuft of hairs is shown.

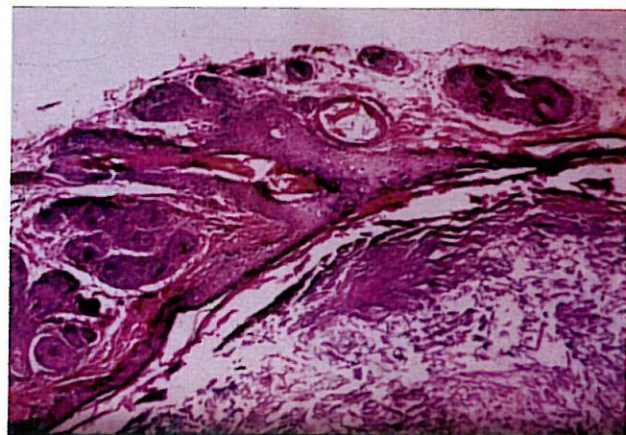


Fig. 2. Trichofolliculoma, (H&E).