

INFERIOR VENA CAVA THROMBOSIS IN A PATIENT WITH ESSENTIAL THROMBOCYTHEMIA

J. EIVAZI ZIAEI, M.D.

From the Dept. of Hematology, Gazi Hospital, Tabriz University of Medical Sciences, Tabriz, Islamic Republic of Iran.

ABSTRACT

Essential thrombocythemia is a chronic myeloproliferative disorder characterized by a sustained proliferation of megakaryocytes, which leads to increased numbers of circulating platelets. Hemorrhagic and/or thrombotic episodes are frequent, and thrombosis of both veins and arteries may develop. Vessels in unusual sites may be involved, e.g., the hepatic veins, mesenteric veins, and the digital vessels. Thrombosis of the inferior vena cava has not been reported previously. In this paper we report inferior vena cava thrombosis in a patient with essential thrombocythemia.

MJIRI, Vol. 12, No. 2, 167-169, 1998.

INTRODUCTION

The concept of myeloproliferative disorders was first introduced by Dameshek in 1951 to describe the entities of chronic myelogenous leukemia (CML), polycythemia vera (PV), essential thrombocythemia (ET), and myelofibrosis with myeloid metaplasia. Each of these disorders is a clonal hematopoietic neoplasm.

Exposure to radiation has a clear association with the development of each of these disorders. For example, an increased incidence of these disorders was found in survivors of the atomic bomb explosions at Hiroshima and Nagasaki. Available evidence indicates that these disorders are acquired diseases.¹

Splenomegaly, thrombosis and anemia are common findings in the course of these disorders. In approximately 60% of patients with myelofibrosis hemoglobin levels drop to <10 gr/dL. The degree of anemia is difficult to estimate by hemoglobin or hematocrit determinations, since individuals with large spleens often have expanded plasma volumes. Such alterations in hemodynamics may lead to apparent anemia, which is largely dilutional in nature. The anemia is due to both ineffective red cell production and shortened red cell survival.²

Primary thrombocythemia is a chronic disorder

characterized by a sustained proliferation of megakaryocytes, which leads to platelet counts in excess of 600,000/mm³. This disorder is characterized by profound marrow megakaryocyte hyperplasia, splenomegaly, and a clinical course punctuated by hemorrhagic and/or thrombotic episodes.¹

Therapy should only be initiated when a diagnosis of essential thrombocythemia is firmly established. First choice therapy has been hydroxyurea, starting at 1 gr/d and then adjusted to achieve normal platelet counts ($1.5-4.5 \times 10^5/\text{mm}^3$) without leukopenia. In those patients who either do not tolerate hydroxyurea or fail to respond, we then proceed to anagrelide. This is started at 0.5 mg qid and increased by 0.5 mg/d every 5-7 days, if platelet counts do not begin to decrease. Anagrelide is a member of the imidazo (2,1-6) quinazolin-2-one series of compounds, which acts primarily by inhibiting megakaryocyte maturation and platelet release; it does not appear to affect DNA synthesis. A major new study of 577 patients treated with anagrelide has confirmed its usefulness.

Anagrelide in low doses has been shown to be effective in lowering platelet counts in 93% of patients. Most importantly, it is effective despite resistance to previous therapy.³

More recent data confirm and extend the initial

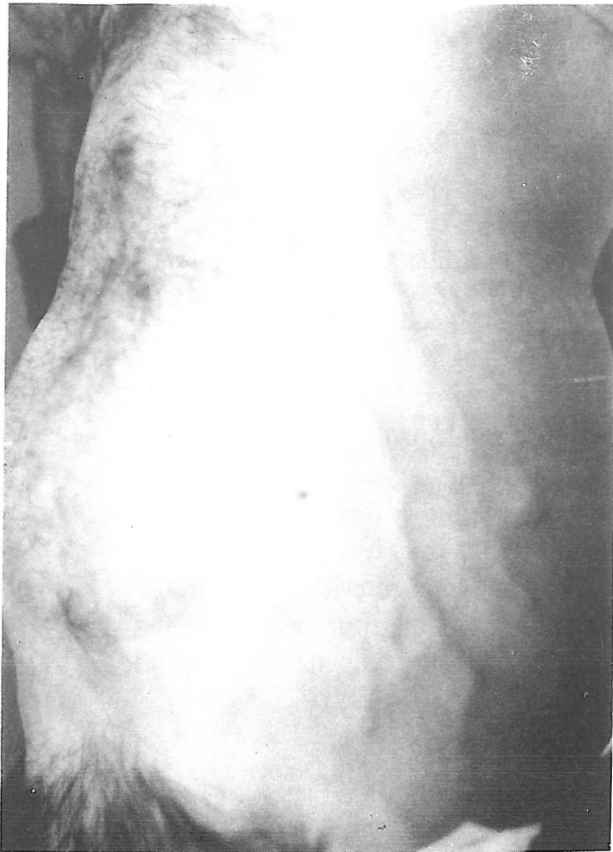


Fig. 1. Photograph of the patient showing massively dilated abdominal vessels.

observation that anagrelide can reduce the platelet count in over 90% of those evaluable for response whether or not they have been previously treated and regardless of prior therapy used or response to that therapy.⁴

Case report

A 30 year old man was admitted to the hospital because of abdominal pain and swelling. In physical examination he had dilated abdominal vessels, splenomegaly and anemia. Laboratory data were as follows: FBS: 82 mg%, urea: 20 mg%, creatinine: 0.8%, AST: 25 I.U., ALT: 19 I.U., LDH: 101, ALP: 26, Alb: 3.6 gr%, protein: 6.9 g%, bilirubin: 0.9, Hb: 6.1, MCV: 89, MCH: 22, MCHC: 26, PLT: 941,000, Retic: 3%, RBC: 2,200,000, WBC: 11,000, Poly: 48%, L: 38%, Myelocyte: 2%, Meta: 3%, Mono: 4%, Promyelocyte: 2%, Band cell: 3%.

Gastroscopy was normal and without esophageal varices.

Doppler sonography detected normal flow in the splenic and portal vein with echogenic material in the inferior vena cava (IVC).

In right femoral venography, the external iliac veins and IVC were not visualized and flow from the hypogastric veins and superior rectal anastomoses to the portal vein was

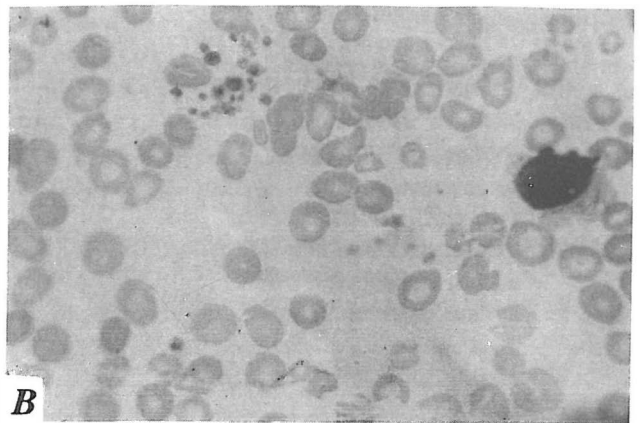
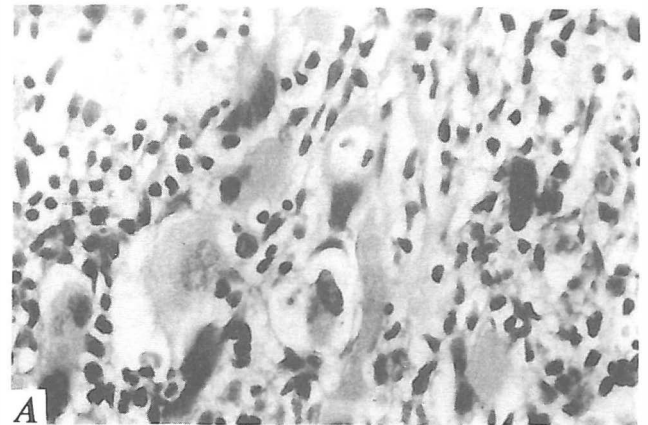


Fig. 2-A,B. Peripheral smear and bone marrow aspiration and biopsy of the patient.

detected. IVC thrombosis was thus diagnosed. The patient was consulted for splenectomy. Huge splenomegaly and massively dilated abdominal veins were detected (Fig. 1). Peripheral blood smear showed marked thrombocytosis with moderate anisocytosis, and a few myelocytes and band cells. Bone marrow aspiration with biopsy showed megakaryocyte hyperplasia with moderately increased reticulin fibers. In Prussian Blue staining iron stores were normal.

Myeloproliferative disorder, R/O essential thrombocythemia was diagnosed (Fig. 2). His anemia was believed to be due to ongoing marrow fibrosis.

The patient received hydroxyurea 500 mg tds, danazol, and packed red cells. He was advised to consult a vascular surgeon for I.V.C. thrombosis but he refused.

In follow up he had no response to hydroxyurea and the drug was discontinued. Anagrelide was not available for use. He developed pretibial edema, palpitation, dyspnea, and repeated bouts of chest pain. EKG was normal, but the chest X-ray showed cardiomegaly. He was treated for congestive heart failure. Anemia, splenomegaly and pulmonary symptoms persisted and he died about 1.5 years after diagnosis.

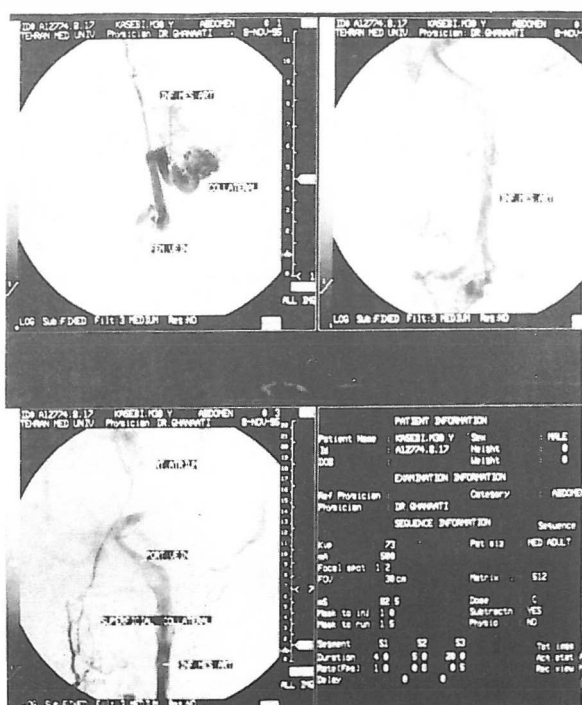


Fig. 3. Inferior venography of the patient.

DISCUSSION

Patients with M.P.D. may develop thrombosis at unusual anatomic sites, particularly involving the splenic, portal, hepatic, and mesenteric vessels.⁵

Colombi studied one-hundred three patients with E.T. and followed them for 12 to 175 months. Twenty six of them (25%) presented with thrombotic complications mainly affecting the cerebral or peripheral arteries.⁶ Mitus studied 44 patients with E.T. and in one case with platelet counts of 700,000 and normal aggregation, cerebral sinus thrombosis occurred.⁷

Millard reported a retrospective review of 13 patients with E.T. Two of them suffered from acute M.I. as their presenting symptom.⁸ McIntyre studied 56 patients.

Disturbances of the microcirculation were the most frequent thrombotic complication occurring in 21 (38%) of the patients. Complications related to thrombosis were noted in one patient with deep venous thrombosis of a lower extremity.⁹ Barillari described a case of E.T. and thrombosis of the adrenal vessels.¹⁰ Our case is unique in this regard as it concerns I.V.C. thrombosis in E.T.

REFERENCES

1. Munker R, Phillip Koeffler H: Pathobiology of the Myeloproliferative Disorders. In: Hoffman R, Benz EJ Jr, (eds.), Hematology, Basic Principles and Practice. New York: Churchill Livingstone, pp. 817-819, 1991.
2. Hoffman R: Agnogenic myeloid metaplasia, In: Hoffman R, Benz EJ Jr, (eds.), Hematology, Basic Principles and Practice. New York: Churchill Livingstone, pp. 1160-1171, 1995.
3. Hoffman R: Primary thrombocythemia, In: Hoffman R, Benz EJ Jr (eds.), Hematology, Basic Principles and Practice. New York: Churchill Livingstone, pp. 1174-1182, 1995.
4. Silverstein MN, The Anagrelide Study Group: Anagrelide, a therapy for thrombocythemic states: experience in 577 patients. Am J Med 92 (1): 69-76, 1992.
5. Bithell TC: Thrombocytosis, In: Lee GR, Bithell TC, (eds.), Wintrobe's Clinical Hematology. Philadelphia: Lea & Febiger, pp. 1390-1393, 1993.
6. Colombi M: Thrombotic complications in essential thrombocythemia. Cancer 67 (11): 2926, 1991.
7. Mitus A: Hemostatic complications in young patients with essential thrombocythemia. Am J Med 88 (4): 371, 1990.
8. Millard F: Clinical manifestations of essential thrombocythemia in young adults. Am J Hematol 33 (1): 27-31, 1990.
9. McIntyre K: Essential thrombocythemia in young adults. Mayo Clin Proc 66 (2): 149, 1991.
10. Barillari B: Thrombocythemia and thrombosis of the adrenal vessels. J Endocrinol Invest 16 (5): 345-9, 1993.

