

ANTEGRADE URETEROSCOPY FOR REMOVAL OF URETERAL STONES

ZHANG JILUN, NA. YANQUN AND PENG BO

From the Institute of Urology, Beijing Medical University, Beijing, China

ABSTRACT

30 cases of obstructing proximal ureteral stones at the level of L3-L5 which could not be pushed back into the pelvis and passed by a guide wire under epidural anesthesia, were removed percutaneously with the rigid ureteroscope. Multiple stones in one ureter, bilateral ureteral stones and a ureteral stone of a solitary kidney were removed successfully in one session showing the reliability and efficacy of this procedure.

MJIRI, Vol.2, No.1, 15-17, 1988

INTRODUCTION

Endourological procedures such as percutaneous nephroscopy and retrograde ureteroscopy, and ESWL have brought about a revolutionary advance in the treatment of upper urinary tract stones. However, the obstructing proximal ureteral stones, which impact in the ureteral wall, are a challenging problem either for disintegration by ESWL or for manipulation by retrograde ureteroscopy. In 1985, Gumpinger, et al¹ reported antegrade ureteroscopy for the removal of stones in the proximal ureter, providing an alternative approach for the removal of stones in this part of the ureter. From October, 1986 to November, 1987, 30 cases with obstructing proximal ureteral stones including bilateral ureteral stones, multiple stones in one ureter and stones in the ureter of a solitary kidney were successfully treated by percutaneous antegrade ureteroscopy in the Institute of Urology, Beijing Medical University. The clinical materials and procedures are reported as follows.

MATERIAL AND METHOD

30 patients with proximal ureteral stones, which could not be pushed back into the pelvis under epidural anesthesia in lithotomy position, were treated by this procedure. The sex and age of the patients, as well as the location and size of stones are shown in Table I. The patients were then turned over into a prone position on the X-ray table and a pillow was placed under the

stomach. The retrograde pyelography was performed under fluoroscopy in preparation for percutaneous nephrostomy. If the contrast medium could not by-pass the stone, intravenous contrast medium or puncture of the pelvocalyceal system with a fine needle for injection of contrast medium was required for pelvocalyceal

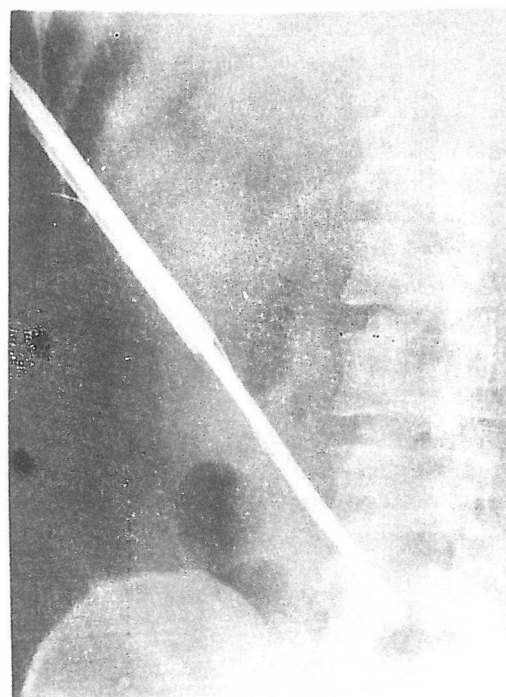

Figure 1. An 11.5F ureteroscope is introduced through a nephroscope sheath into the ureter to treat a stone at the level of L5.

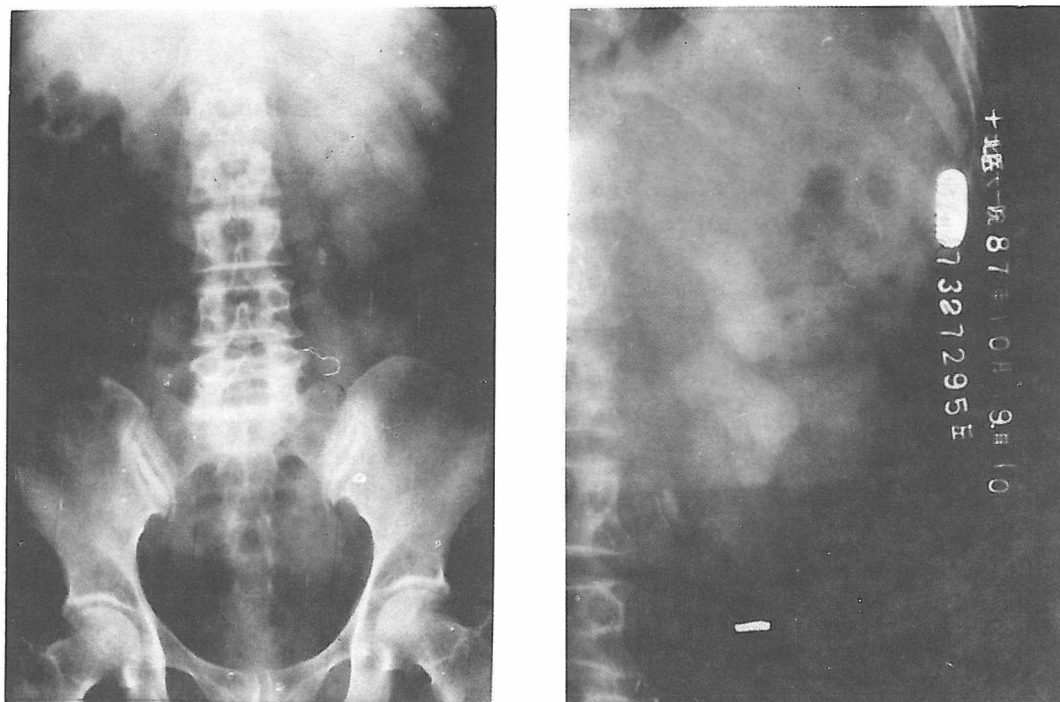


Figure 2. A and B. IVP before antegrade ureteroscopy revealing a ureteral stone at the level of L3-L4 of a left solitary kidney.

opacification. The preferred site for placement of the nephrostomy was the middle calyces. A guide wire was advanced down to the ureter to provide safety and to facilitate later ureteral endoscopic manipulation. The percutaneous tract was established and dilated up to 22F with telescope dilators. An operation nephroscope sheath was then inserted into the pelvis over the telescope dilator. A thorough nephroscopic inspection of the pelvis and identification of the ureteropelvic junction were carried out. Antegrade ureteral catheterization under direct vision with a 5-F catheter was necessary when advancement of the guide wire into the ureter had failed during percutaneous nephrostomy. When the ureter was severely dilated a 24-F nephroscope was introduced into the ureter to remove the stone with forceps, basket or ultrasound lithotrite. When the ureter was not dilated or the stone was too low to be reached, the ureteroscope was required. An 11.5F ureteroscope was introduced into the ureter through the nephroscope sheath, which was left in the upper part of a dilated ureter or at the ureteropelvic junction. It is important to place a catheter in the ureter as a guide wire in order to facilitate and ensure the safety of introducing the ureteroscope. Once the stone could be seen ureteroscopically, it would be removed by either an ultrasound lithotrite or forceps, extrapt basket respectively, or by the combined use of them, depending on the size and the embedment of stones. When ureteral damage induced by manipulation or the existence of residual fragments were suspected, an

indwelling ureter stent was necessary. At the end of the procedure, a nephrostomy tube was inserted and secured on the skin.

Postoperative care

Antibiotic therapy for one week and continuous nephrostomy drainage was performed. The nephrostomy tube was removed 5-7 days after the operation when the ureter was documented as stone-free and obstruction-free by KUB and nephrotomogram.

RESULTS

Of the 30 cases treated, the stones were successfully removed with the nephroscope in nine cases and with the ureteroscope in 21 cases. Among these, three cases had multiple stones in one ureter while two cases had bilateral ureteral stones, which were all removed in one session. In one case, a solitary kidney with a ureteral stone was also treated successfully.

In all cases, a complete stone removal was performed. The nephrostomy tube was withdrawn five to seven days postoperatively without any difficulty. No extravasation or ureteral stenosis has been found so far. No blood transfusion was needed.

DISCUSSION

Since the development of the digital ureteroscope in 1980, transurethral retrograde ureteroscopy has be-

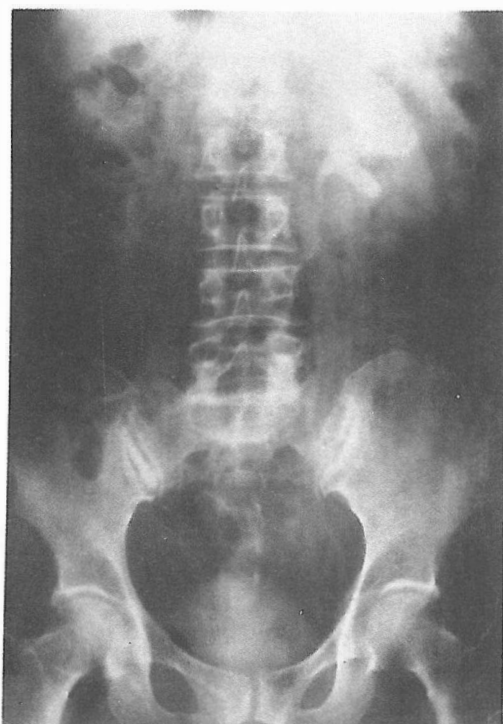


Figure 3. IVP of the patient shown in Fig. 2 after antegrade ureteroscopy.

come a standard procedure in many medical centers. However, our experience with 132 cases of retrograde ureteroscopic stone extraction showed that the success rate was 95% for stones in the lower part of ureter (beneath the iliac crest) and 68% for stones in the proximal ureter (above the iliac crest).² The major reason for failure in treatment of proximal ureteral stones was that in some cases because of tortuosities or strictures of the ureter below the stone the passage of the instruments was not possible; as a result the stones were inaccessible. Worldwide, ESWL has proven to be the preferred treatment in 90% of cases of upper tract stones. However, the impacted ureteral stones seem difficult to break by ESWL due to a lack of expansion space around them needed to facilitate pulverization. Coptcoat et al reported that ESWL was used as the sole modality of treatment for 80% of renal stones and 3% of ureteral stones, while percutaneous or retrograde endoscopic procedures were used in combination with ESWL in the remaining cases. In fact, retrograde ureteroscopy and ESWL both have problems of their own in the treatment of proximal ureteral stones, particularly the obstructing ones in which the antegrade ureteroscopy has superior capabilities.

In our group of patients the indications for anteg-

Table I. Age and sex of patients, size and location of stones

Male	19 pts	
Female	11 pts	
Age	24-70yr. (mean 45.9)	
Size of stones	1 cm	3 pts
	1-1.5 cm	20 pts
	1.5-2 cm	7 pts
Location of stones	L3	11 pts
	L4-5	19 pts

rade ureteroscopy are 1) obstructing stones which can not be pushed back into the pelvis or passed by a guide wire, 2) the stones located higher than the level of the iliac crest, 3) stones that have remained in the ureter for more than six months. Antegrade ureteroscopy can be used not only as a primary treatment but also as a procedure supplementary to ESWL. A patient in this group had a high fever and the stone appeared to have not disintegrated on X-ray after ESWL. The patient became fever-free after the stone was removed by antegrade ureteroscopy in which the stone was found to be buried in edematous ureteral mucosa.

In order to facilitate ureteral manipulation, the preferable site of entry into the pelvocalyceal system is the middle calyces. The flank incision inferior to the twelfth rib usually provides a more favorable angle for directing instruments into the ureter. For making the ideal tract, the patients in our group were placed in a prone position on an X-ray table with fluoroscopic facilities so they could cooperate by moving the kidney down with inspiration. For introducing the ureteroscope antegrade and manipulating stones, it is essential that a guide wire or catheter be inserted down to the ureteral stone during the percutaneous nephrostomy or under direct vision. It is a key point to success and avoidance of the postoperative complications. With some experience, bilateral ureteral stones and multiple stones in one ureter can be removed in one session, while stones in the ureter of a solitary kidney can also be treated successfully.

REFERENCES

1. Gumpinger R, Miller K, Fuchs G, Eisenberger F: Antegrade ureteroscopy for stone removal. *Eur Urol* 11 (3): 199-202, 1985.
2. Zhao-ying X, Ying-lu G, Jilun Z: 132 cases of transurethral ureteroscopic lithotripsy. *Chin J Urol* 8: 338-9, 1987.
3. Coptcoat MJ, Webb DR, Kellett MJ, et al: The complications of extracorporeal shockwave lithotripsy: management and prevention. *Br J Urol* 58: 578-80, 1986.

