

Case Reports

EOSINOPHILIC GASTROENTERITIS: REPORT OF TWO CASES AND REVIEW OF THE ENGLISH LITERATURE

HASSAN SAADATNIA, M.D., AND SHAHRIAR ZEHTABCHI, M.D.

From the Department of Medicine, Qhaem Hospital, Mashhad University of Medical Sciences, Mashhad, Islamic Republic of Iran.

ABSTRACT

Eosinophilic gastroenteritis is a rarely reported condition. The disease is characterized by peripheral blood eosinophilia, eosinophilic infiltration of the bowel wall to a variable depth, and gastrointestinal complaints. Allergic diathesis can be found in most of the cases. In this article we report two cases with interesting epidemiological characteristics and we will have a brief review of reported cases in the English literature.

MJIRI, Vol. 7, No.1, 51-54, 1993.

Keywords: eosinophilic gastroenteritis, eosinophilic infiltration of G.I. tract, eosinophilia

INTRODUCTION

Eosinophilic leukocytes normally are scattered in the lamina propria of the gastrointestinal tract. The number of these cells is increased in some well-defined conditions such as peptic ulcer, helminthic infestation, Crohn's disease, ulcerative colitis, intestinal carcinoma, lymphoma, etc. Sometimes, however, there is no associated disease to explain the increase of eosinophils. The term eosinophilic gastroenteritis (EGE) is usually applied to describe such conditions.

EGE is a rare disease which is characterized by eosinophilic infiltration of the GI wall and is associated with peripheral blood eosinophilia in most cases. There is usually a good correlation between the distribution, layer of bowel involved, and clinical presentation.

Case 1

A 24-year-old male medical student presented with periumbilical crampy abdominal pain and diarrhea for one month. He had no other gastrointestinal complaints except for mild dyspepsia. The pain was not related to any specific

food ingestion. There was no history of drug use by the patient. He had a past history of hay fever and urticaria. He had a trip to the north of Iran to help the people damaged by earthquake disaster (June 21, 1990) just before the presentation of the disease. No remarkable finding was noted on physical examination.

Routine laboratory tests were all normal except for C.B.C. which showed 32% and 55% eosinophilia in the peripheral blood with total count of 25,500 and 28,000 leukocytes, respectively on two occasions. The erythrocyte sedimentation rate was in normal range.

Stool examination was positive for *Giardia lamblia* and occult blood but negative for pathogenic bacteria. Total serum IgE was 185 IU/ml (normal range: <200 IU/ml). Skin test (Prick test) was positive for five allergens. Chest X-ray and K.U.B. were both normal. Upper GI series and barium follow-through showed a normal stomach, but thickening and nodularity of the jejunal folds (Fig. 1). At gastroduodenoscopy, the duodenal mucosa appeared nodular and thickened. Multiple biopsies were taken from the stomach and duodenum.

In histological examination, congestion and edema of

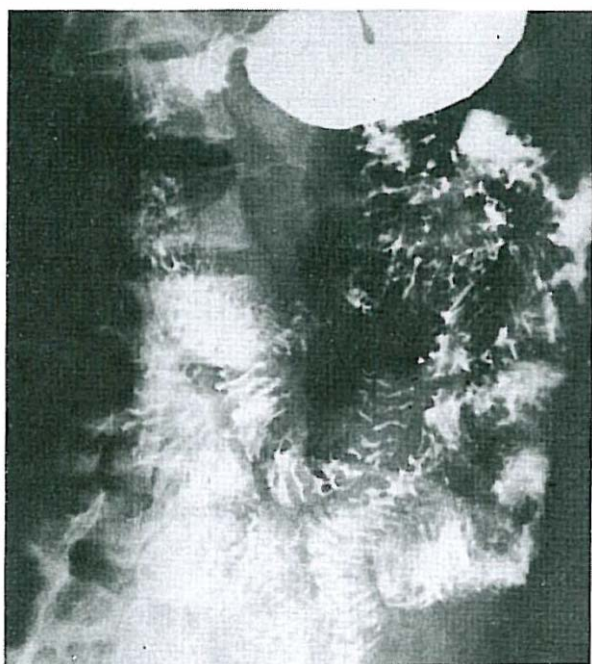


Fig. 1. Upper GI series and barium follow-through (case 1) showing thick nodular folds throughout the small intestine.

lamina propria and diffuse infiltration of eosinophils was reported. No parasite was observed. Duodenal aspirate was positive for *Giardia lamblia*.

The patient was treated with prednisolone, 40 mg/day. The symptoms disappeared immediately. The complete blood count revealed 11,000 WBC, 83% neutrophils, 15% lymphocytes, 2% monocytes, and 0% eosinophils, three days after beginning treatment. The drug was tapered gradually during two months. After that, there was some episodes of recurrence of symptoms without need for steroid therapy. Different investigations ruled out any other disease that could cause peripheral blood eosinophilia. The patient was also treated for *Giardia lamblia* with metronidazole, 250 mg.

One year later, C.B.C. was as follows: 9,300 WBC with 40% neutrophils, 29% lymphocytes, 2% eosinophils.

In this patient, history of urticaria, hay fever, positive allergic skin test, history of travelling to hyperendemic area for parasitic diseases, positive stool examination for *Giardia lamblia* and occupation of the patient (medical student) are notable finding.

Case 2

The patient was a 28-year-old male dentistry student with the chief complaint of crampy abdominal pain for one week. There was no concomitant symptom. He had a history of urticaria and hay fever. The pain was not related to any specific food ingestion. No history of drug use was noted. Physical examination was normal except for slight tenderness in the periumbilical area.

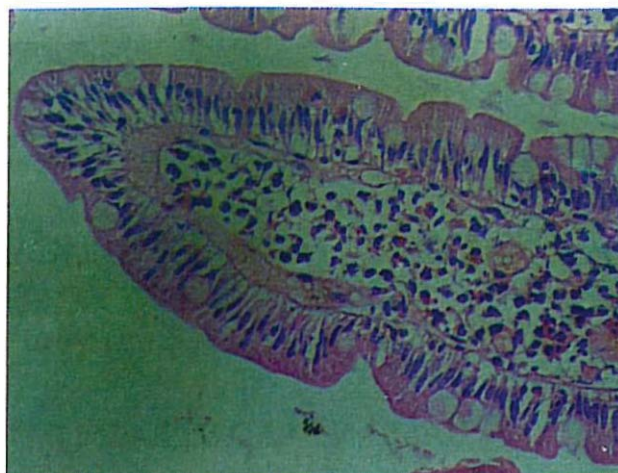


Fig. 2. Peroral endoscopic small bowel biopsy specimen of case 2. The lamina propria is heavily infiltrated with eosinophils.

Routine laboratory tests were all normal except for CBC which showed 45% and 60% eosinophilia in the peripheral blood with the total white count of 15,400 and 21,600, respectively, on two occasions. The erythrocyte sedimentation rate was normal.

Chest X-ray and K.U.B. were normal. Upper GI series and barium follow through revealed thickness and nodularity of mucosal folds in the stomach and jejunum, and dilatation of intestinal loops and fragmentation of barium in the ileum.

In endoscopic examination by small intestine fiberope, stomach appeared normal, but edema and nodularity was apparent in the duodenum and proximal jejunum. Multiple biopsies were taken.

In histologic examination, diffuse eosinophilic infiltration was seen in the lamina propria and submucosa of the jejunum (Fig. 2). Histological examination of the gastric mucosa was reported normal except for slight infiltration of eosinophils. No parasite was seen. Examination of duodenal aspirate was positive for *Giardia lamblia*.

Serum total IgE was in normal range. Other diseases that could cause peripheral eosinophilia were ruled out by different investigations. The patient was treated with prednisolone, 40 mg/day. The symptoms disappeared just after beginning treatment. The drug was tapered gradually over five months. Three days after beginning steroid therapy the C.B.C. revealed 10,000 WBC with only 4% eosinophils. The patient was also treated for *Giardia lamblia* with metronidazole, 250 mg tid for 10 days. 1.5 years later, total WBC count was 3,700 with 56% neutrophils, 32% lymphocytes, 10% monocytes and 2% eosinophils.

In this patient, history of allergic manifestations, infestation with *Giardia lamblia*, and occupation of the patient (dentistry student) were the positive pertinent findings. As in case 1, the response to steroid therapy was excellent.

DISCUSSION

Eosinophilic gastroenteritis is a clinicopathologic state with undefined pathogenesis which is characterized by eosinophilic infiltration of the gastric antrum and/or proximal part of the small bowel. This infiltration typically involves mucosa or muscularis (or both). Serosal layer is rarely involved.

Small bowel may show edema, thickness, and stiffness in the involved area. Sometimes necrosis and rarely ulceration may be seen. The disease can involve all parts of the GI tract, but the stomach is involved in nearly all cases. The esophagus and large intestine are almost always spared.^{2,4,5,9}

The pathogenesis of EGE is unknown. There is, however, some evidence to suggest an allergic basis for the disease. These include both peripheral and tissue eosinophilia, a high frequency of past or present allergic diseases (hay fever, asthma, eczema, and urticaria), and the impression by the patient that various foods may precipitate gastrointestinal symptoms. According to the studies conducted by Greenberger, mucosal eosinophilia was accentuated when foods that precipitated symptoms were instilled into the jejunum of the patient with the disease.^{2,9,19}

History of allergy is present in 52% of cases.¹⁴ Wienand, et al. reported a case of EGE as an allergic reaction to a trimethoprim-sulphonamide preparation.¹⁸

The clinical manifestations depend on the area of maximal GI involvement and more particularly the depth of the maximal disease process. Three main patterns can be delineated.^{2,3,5,9}

1. Predominance of mucosal layer involvement: In this group, the more severe cases of malabsorption and iron deficiency anemia with fecal blood loss have been described. In these patients, enteric loss of protein with hypoproteinemia and peripheral edema may be seen, too.

2. Predominance of muscularis layer involvement: In this group, marked thickening and rigidity of the gut develops with obstruction symptoms and radiologic features of pyloric narrowing and obstruction in the stomach and features simulating regional enteritis in the small bowel.^{3,12} The disease can also cause pancreatic and biliary obstruction in very rare cases.^{7,13}

3. Predominance of serosal layer involvement: Cardinal manifestation in this group is ascites with marked eosinophilia in ascitic fluid.^{1,10}

The tissue damage that is seen probably results from the eosinophilic infiltration. Arthus type hypersensitivity may be responsible for attracting eosinophils to the site of antigen-antibody complexes. The activation of standard complement pathway can be expected to draw eosinophils to the site of the complex deposition by means of the C3 receptor on the surface of the eosinophils.

A second mechanism, invoking cellular hypersensitivity by T-cells specifically sensitized to antigens have been shown to release a lymphokine factor capable of attracting peripheral blood eosinophils. In patients with demonstrable

serum IgE antibodies to specific food substances and elevated IgE serum levels, the local tissue injury in the gut may be due to toxic substances released by mast cells rather than damage by the eosinophils themselves.^{2,7,9,11} Peripheral blood eosinophilia and abnormal erythrocyte sedimentation rate are found in most of the patients with EGE.

Serum total IgE may be elevated and specific food challenge can cause rapid elevation of IgE level in the serum. Stool is positive for occult blood in most of the cases, but apparent bleeding in the form of hematochezia or melena is rare. Charcot-Leyden crystals can be found in the microscopic examination of the stool.^{2,4,5,8,9}

EGE of mucosal type is diagnosed according to the biopsy findings. Because of discontinuity of the disease process, biopsies must be obtained from multiple sites. The stomach must be examined by multiple biopsies in all cases because of high frequency of involvement. In the muscularis or serosal layer type involvement, biopsy must be deep enough to reveal the involved layer. Radiologic examination, laboratory findings and history of allergic diathesis in the patient may also help to diagnose the disease.

The basis for treatment of all types of EGE is the use of corticosteroids of short duration (5-10 days). In the cases of relapse, the treatment must be repeated. Long-term use of the drug may be needed for complete relief of symptoms in some cases. Different studies have offered other drugs such as sodium cromoglycate and ketotifen (an antihistaminic) as effective alternatives to traditional systemic corticosteroid therapy for treatment of EGE.^{6,11} No case refractory to such therapy has been documented. Elimination diets have been advised but may not necessarily cause complete relief of symptoms or disease remission.

Mortality related to the disease itself is rare. Patients with eosinophilic gastroenteritis have no increased risk of gastrointestinal malignancy.^{2,9,14}

Although rare, EGE should be considered in the differential diagnosis of patients with GI symptoms and peripheral blood eosinophilia. A number of diseases can mimic the findings of eosinophilic gastroenteritis. Lymphoma of the stomach or small intestine, gastric cancer, and Crohn's disease, involving stomach and proximal small bowel, may all demonstrate radiographic features compatible with eosinophilic gastroenteritis. Peripheral eosinophilia is not usual in these conditions. Moreover, increased erythrocyte sedimentation rate is commonly noted in these diseases. Endoscopy or small bowel biopsies will usually suffice to confirm the diagnosis. Polyarteritis nodosa and hypereosinophilic syndrome also must be considered in the differential diagnosis.

Gastrointestinal parasites should always be excluded in patients with abdominal complaints, weight loss, and peripheral eosinophilia. In particular, infestations by hookworms, *Ascaris*, *Strongyloides*, *Toxocara*, *Trichiuris* and intestinal *Capillaria* should be considered in those patients from en-

Eosinophilic Gastroenteritis

demic areas.^{2,3,8,9,12,15,17} As *Giardia lamblia* is not an invasive parasite of the human G.I. tract and does not cause peripheral blood eosinophilia, we do not think that G.I. problems in our patients related to infestation by this parasite.

REFERENCES

1. Adams HW, Maniz DL: Eosinophilic ascites. A casereport and review of literature. *Digestive Dis* 22(1): 40-2, 1977.
2. Blackshaw AJ, Levison DA: Eosinophilic infiltrates of the GI tract. *J Clin Pathol* 39: 1-7, 1986.
3. Caldwell JH, Mekhjian HS, Hurtubise PE, Beman FM: Eosinophilic gastroenteritis with obstruction. Immunological studies of seven patients. *Gastroenterol* 74: 825-29, 1978.
4. Carmichael JL, Mauldin JL, Sullivan MB: Eosinophilic gastroenteritis. *Southern Med J* 75 (6): 742-4, 1982.
5. Cello UP: Eosinophilic gastroenteritis - A complex disease entity. *Am J Med* 67: 1097-104, 1979.
6. Di - Gioacchino M, et al: Sodium cromoglycate in the treatment of eosinophilic gastroenteritis. *Allergy* 45 (3): 161-6, 1990.
7. Farahvash MJ, Bastani-B, Farahvash MR, Irvanlou G: Eosinophilic gastroenteritis presenting with biliary and partial duodenal obstruction. *Am J Gastroenterol* 85 (8): 1022-4; 1990.
8. Fauci AS, et al: The idiopathic hypereosinophilic syndrome. Clinical, pathophysiologic, and therapeutic consideration. *Ann Intern Med* 97: 78-92; 1982.
9. Klein NC, et al: Eosinophilic gastroenteritis. *Medicine* 49 (4): 299-318; 1970.
10. McNabb PC, et al: Transmuraleosinophilic gastroenteritis with ascites. *Mayo Clin Proc* 54: 119-22, 1979.
11. Melamed I, et al: Benefit of ketotifen in patients with eosinophilic gastroenteritis. *Am J Med* 90 (3): 310-4; 1991.
12. Milman PJ, Sidhu GS: Eosinophilic gastritis simulating a neoplasm. *Am J Med Sci* 2276 (1): 227-30; 1978.
13. Mohandas KM, et al: Pancreatic and biliary obstruction due to eosinophilic gastroenteritis. *Am J Gastroenterol* 85 (11): 1540-1, 1990.
14. Naylor AR: Eosinophilic gastroenteritis. *Scott Med J* 35 (6): 163-5, 1990.
15. Suen KC, Burton JD: The spectrum of eosinophilic infiltration of the GI tract and its relationship to other disorders of angitis and granulomatosis. *Human Pathol* 10 (1): 31-43; 1979.
16. Torpier G, et al: Eosinophilic gastroenteritis: Ultrastructural evidence for a selective release of eosinophil major basic protein. *Clin Exp Immunol* 74: 404-8, 1988.
17. Whittington PF, Whittington GL: Eosinophilic gastroenteropathy in childhood. *J Pediatr Gastroenterol Nutr* 1: 379-85, 1988.
18. Wienand B, Sanner B, Liersch M: Eosinophilic gastroenteritis as an allergic reaction to a trimethoprim-sulphonamide preparation. *Dtsch Med Wochenschr* 8; 116 (10): 371-4; 1991.