

A STUDY OF 17 PATIENTS WITH PULMONARY SARCOIDOSIS IN MASHAD

PARVIZ VAHEDI, M.D.

From the Mashad University of Medical Sciences, Imam Reza Hospital, Mashad, Islamic Republic of Iran.

ABSTRACT

Thirty patients with bilateral lymph node enlargement with or without parenchymal infiltrates on the chest x-ray suspected to have sarcoidosis were studied between June 1980 and December 1989 in our institution. Eleven of these patients who were free of parenchymal infiltrates did not have a biopsy performed and the diagnosis of sarcoidosis was made based on self-limited regression and clearing of the chest X-ray findings. However, these cases were excluded from our study along with two other cases which upon transbronchial lung biopsy (TBLB) failed to show the disease. Seventeen of our cases had sarcoidosis, fourteen proven by TBLB, two by skin biopsy and one by parotid gland biopsy. Our study shows that sarcoidosis is not a rare disease in IRAN. TBLB is a good way to diagnose sarcoidosis especially when parenchymal involvement is present on the chest X-ray.

Although stage I of the disease was more common in our series, it is probable that this is a false finding and if TBLB were repeated more cases of stage III of the disease would be found.

MJIRI, Vol.4, No.1, 31-36, 1990

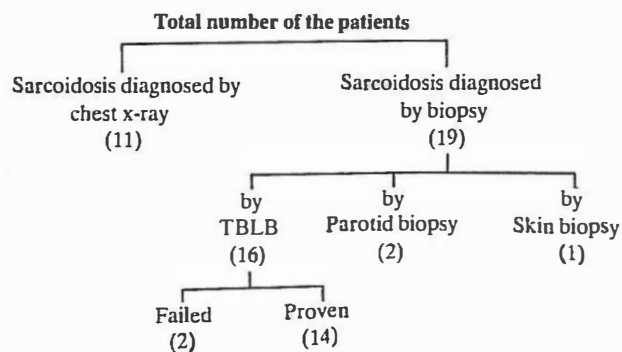
INTRODUCTION

Sarcoidosis is a systemic granulomatous disease of unknown etiology with protean manifestations.¹ American literature reveals that it most commonly affects young blacks² and although its long-term prognosis and potential for remission is good, it can result in significant morbidity.³ It notoriously mimics Hodgkin's disease, other lymphomas and tuberculosis, re-

sulting in the frequent need for a definitive diagnosis. Biopsy of involved organs discloses characteristic non-caseating granulomas,⁴ and is useful in excluding other disease possibilities.

In this article 17 proven cases of pulmonary sarcoidosis studied at the Imam Reza Hospital Medical Center in the University of Mashad from June 1980 to December 1989 are reported, the clinical manifestations of these patients are also compared with reported cases in the medical literature.

Table I. Schematic representation of 30 cases of sarcoidosis



PATIENTS AND METHODS

Thirty patients of varying age and sex were studied for their chest X-ray abnormalities consisting of hilar lymph node enlargement with or without pulmonary parenchymal involvement (Table I). Nineteen of these thirty cases were female and the remainder were male patients varying from 30 to 65 years of age. Of these patients eleven had only hilar lymph node enlargement without parenchymal involvement radiographically and had no biopsy performed. These cases were ex-

Pulmonary Sarcoidosis In Mashad

Table II. Patient Demographic Data

patient	Age (Yr)	Sex	Symptoms and Signs							Radiologic Findings			Site of biopsy			Progression	
			Dyspnea	Chest pain	Cough	Fever	Ery.nod.	Par. In.	L.N.	Hepat	Spleno	H+M	Parench	Skin	Par		TBLB
1	32	M	-	-	+	-	-	-	-	-	-	+	-	-	-	+	S.L
2	50	F	+	-	-	-	-	-	-	-	-	+	+	-	-	+	S.L
3	60	F	+	-	-	-	-	-	-	-	-	-	+	-	-	+	L.F
4	60	F	+	-	-	-	-	-	-	-	-	+	+	-	-	+	L.F
5	65	F	+	-	-	-	-	-	-	-	-	-	+	-	-	+	L.F
6	40	M	+	+	+	+	+	-	+	+	+	+	+	-	-	+	S.L
7	30	F	+	-	-	+	+	-	-	-	-	+	+	-	-	+	U.T.
8	45	F	+	-	-	-	-	-	-	-	-	-	+	-	-	+	L.F
9	52	M	+	+	-	-	-	-	-	-	-	+	+	-	-	+	U.T
10	45	M	+	+	-	+	+	+	-	-	-	+	+	-	-	+	S.L
11	63	F	+	+	-	-	-	-	-	-	-	-	+	-	-	+	L.F
12	45	F	+	-	-	-	-	-	-	-	-	+	+	-	-	+	S.L
13	58	M	+	+	-	-	-	-	-	-	-	+	-	-	-	+	S.L
14	46	M	+	-	-	-	-	-	-	-	-	+	+	-	-	+	L.F
15	49	M	-	-	-	-	+	-	-	-	-	+	-	+	-	-	L.F
16	52	F	+	-	-	-	+	-	-	-	-	+	+	+	-	-	S.L
17	48	F	+	+	-	+	+	+	-	-	-	+	+	-	+	-	U.T

Ery.nod. = erythema nodosum; Par. In. = parotid involvement; L.N. = lymph node enlargement; Hepat = hepatomegaly; Spleno = Splenomegaly; H,M = Hilar and mediastinal node involvement; Parench = parenchymal involvement; Par = parotid; TBLB = transbronchial lung biopsy; SL = self limited; L.F. = loss of follow-up; U.T. = under treatment with prednisolone.

cluded from our study. The diagnosis of sarcoidosis in these patients was made based on a self limited regression of the x-ray findings with or without erythema nodosum. The other 19 patients had biopsy performed either through an Olympus fiberbronchoscope, or from the skin or parotid gland. Of these, two patients failed to show noncaseating granuloma on lung biopsy and still failed to be enrolled in our study. Excluding three of these 17 cases who proved to have sarcoidosis by skin or parotid gland biopsy, the remainder (14 cases), were diagnosed by transbronchial lung biopsy (TBLB). So only seventeen of the thirty patients were enrolled in our study and proved to have pulmonary sarcoidosis: 14 had TBLB, two had skin biopsy and one had parotid gland biopsy.

TBLB was performed mostly for patients who had parenchymal involvement on the chest x-ray; however patients #1 and #15 had no parenchymal involvement on the x-ray, though the procedure revealed non-caseating granuloma specimens.

RESULTS

The demographic data of these 17 proven cases of sarcoidosis are presented in Table II.

As shown in the demographic data, the youngest patient was 30 and the oldest 65 years old.

Dyspnea was the most common manifestation pre-

senting either during rest or produced upon exercise. Almost all patients with parenchymal infiltrates had resting dyspnea. However patient # 13 had exertional dyspnea without any evidence of parenchymal involvement on x-ray. This patient had a decrease in VC compared with the predicted value. However vital capacity was not decreased in any of the remaining patients who had only hilar and mediastinal involvement without parenchymal disease.

Chest pain in our patients had the quality of a vague retrosternal discomfort. Six of our cases had this finding with a normal electrocardiogram. Coughing was not frequent and was seen only in two patients.

Fever was mostly accompanied by erythema nodosum and was a frequent finding in acute cases with almost a self-limited regression.

Erythema nodosum was seen in six patients and usually regressed spontaneously during follow-up.

Other findings including peripheral lymph node enlargement was found only in one patient (# 6, Table I), parotid enlargement in case # 10 and # 17, and liver and spleen enlargement in case # 6.

Patients # 15 and # 16 had maculopapular lesions, # 15 behind the neck and # 16 on the forearm. Biopsy of these lesions demonstrated noncaseating granulomas.

On the chest x-ray, three patients had hilar lymph node enlargement without evidence of parenchymal involvement and three patients had parenchymal dis-

ease without hilar adenopathy. However, 10 patients found to be in stage III of the disease had both hilar node enlargement and parenchymal involvement.

Patient # 6 had a mild right pleural effusion which failed to be confirmed by puncture.

Seven of our patients had a self-limited regression. Unfortunately we failed to follow up seven patients due to the fact that we were unable to contact them. Only two of our cases had progressive illness clinically and radiographically. Pulmonary function tests in these two cases showed a very rapid decline in vital capacity and this along with other clinical and radiographic findings obliged us to administer corticosteroids.

Pulmonary function tests were only abnormal in cases who showed parenchymal involvement either with or without hilar adenopathy. The decline in vital capacity varied from mild to severe degrees. Upon follow up the vital capacity was used as the determining factor in deciding whether or not to place the patient on corticosteroids.

DISCUSSION

Definition. Sarcoidosis, a disease of apparently altered immunity, is manifested in multiple organ systems of the body, but especially in the lungs, eyes, skin, and reticuloendothelial system.^{1,5,6} The presence of non-caseating granulomas in all the affected organs characterizes the disease morphologically. Sarcoidosis was first described by Hutchinson well over 100 years ago, however William Osler perfectly described a case of multisystem sarcoidosis in an 11 year old black girl named Hannah who was admitted to the John's Hopkins Hospital in Baltimore, complaining of swollen glands in the neck.¹ Pulmonary sarcoid was first emphasized in 1915 by Bittorf and Kuznitsky, who stressed the systemic nature of the disease and the involvement of internal organs.⁸ Sarcoidosis now recognized quite commonly is studied and investigated extensively; however, it still remains poorly understood, puzzling, and surrounded by controversies. Debates surround the definition of sarcoidosis, its etiology, pathogenesis, biopsy sites and techniques, staging and therapy.^{6,7,8} Despite all of these contested areas, the physician can usually reach a relative diagnosis of sarcoidosis because the well-described combination of clinical, radiographic, physiologic, and histologic findings are so characteristic.

Epidemiology

Sarcoidosis is a worldwide disease, though its incidence appears to be more common in temperate climates. This variable incidence may be spurious, since a higher incidence is found in developed countries with highly advanced medical facilities where chest

In one large combined series totalling 254 patients the percentage of organ system involvement was as follows:

Lungs	91
Upper Airways	11.2
Lymph nodes	73
Skin	32
E. Nodosum	8.2
Eyes	21
Liver	21
Spleen	18
Bones	14
Salivary Glands	0.1
Heart	5.1
Nervous System	5.1
Joints	5.1
Endocrine	5
Kidneys	4.3
Lacrimal glands	5.2
Breast	1.4
Uterus	0.7
Stomach and Intestines	0.7

roentgenograms are used frequently. The prevalence of sarcoid is variable but is probably around 20 per 100,000 worldwide. The incidence in males is greater than in females. However, in our series it was more common in females.

Sarcoidosis has been found in patients from 3 months to 80 years of age, but basically it is a disease of young adults.^{9,10} In our series the youngest patient was a 30 year old housewife who presented with dyspnea and erythema nodosum and was found to have hilar lymph node enlargement with parenchymal involvement upon x-ray examination. The oldest was a 65-year-old female who complained of dyspnea and had evidence of parenchymal involvement on the chest x-ray. The average age group in our patients was 46 years of age.

Signs and Symptoms

The signs and symptoms of sarcoidosis depend upon the activity of the disease and the organ systems involved. Virtually any organ system can be affected.

James cites three common modes of presentations: Intrathoracic, dermatologic, and ophthalmologic. In one series from the University of Alabama Medical Center in Birmingham 54 patients out of 227 were totally asymptomatic, presenting primarily with an abnormality of the chest x-ray. Of the 30 patients who we presented at the beginning of this article, eleven (36%) had no symptoms, though the chest x-ray revealed bilateral hilar lymph node enlargement without parenchymal involvement and underwent a self limited regression. In addition, patients with sarcoido-

sis commonly present with only nonspecific systemic symptoms of weight loss, fatigue, fever, malaise, weakness, night sweating or chills. In our series fatigue, malaise and weight loss were seen in about one third of the cases; however, night sweats and chills were not seen in any of them.

Signs and symptom of respiratory disease in patients with sarcoidosis are common because the lungs are involved in 90 to 100 percent of the patients with active disease. However, only 60 percent of the patients will have a respiratory sign or symptom (See Table IV) even though more than 90 percent will show a radiographic abnormality and have a lung biopsy that reveals non-caseating granulomas in the interstitium of the lung. Some of the 40 percent who do not have respiratory symptoms may have severe radiographic or functional changes. Initial symptoms may include dyspnea, chest pain, cough and less commonly sputum production. Hemoptysis is uncommon and tends to occur with long-standing sarcoid which has significant architectural derangements. Although abnormal physical findings may be absent, tachypnea, decreased respiratory excursion, a few crackles or occasional wheezes, or bronchovesicular breath sounds can be present. Signs and symptom of respiratory failure, pulmonary hypertension, and cor pulmonale many be found in patients with advanced disease.^{12,13,14,15}

Unfortunately, systemic and respiratory signs and symptoms of patients with sarcoidosis do not correlate well with chest x-rays, pulmonary physiologic abnormalities, and most importantly, with assessment of alveolitis with lung biopsy, bronchoalveolar lavage, and gallium 67 lung scan. Therefore, prognostic assessments and therapeutic decisions are difficult, if not impossible, to make based on signs and symptoms alone.¹

Almost 15 of the 17 proven cases had referred because of dyspnea, six with chest pain, and two with cough. Most of the patients with chest pain and dyspnea had parenchymal involvement on the chest x-ray. However, hemoptysis, respiratory failure, pulmonary hypertension, and cor pulmonale was not found in any because we did not encounter any advanced cases of the disease. Also the radiographs did not correlate well with symptomatology in our patients, although abnormal pulmonary function tests were found mostly in patients presenting parenchymal disease on the chest x-ray. Though patient # 13 had no parenchymal disease on the chest x-ray he complained of exertional dyspnea and pulmonary function tests revealed a mild restrictive pattern.

Chest pain appeared to be one of the most important symptoms in six of our patients. Apparently these patients had a more widened mediastinum on the chest x-ray; however, other patients also had the same enlarged mediastinum and had no complaint of chest

pain.

Erythema nodosum consisting of bilateral tender red nodules on the anterior surface of the legs, is not specific for sarcoidosis but is common particularly in acute sarcoidosis in combination with systemic symptoms and polyarthralgias.¹⁶ Six patients in our series had this sign which subsided within a few weeks. However in patient # 17 this skin lesion lasted for about 6 months. Almost all of our patients with erythema nodosum had fever except # 2, and most of them were complaining of polyarthralgias. Bilateral hilar node enlargement on the chest x-ray was seen in all our patients with erythema nodosum.

Bilateral, nontender, firm, enlarged parotid glands may be observed in less than 10 percent of the patients and usually early in the course of the disease. Spontaneous regression is frequent. A syndrome known as uveoparotid fever includes bilateral lacrimal and parotid gland enlargement, fever, and anterior uveitis.¹⁷ Two of 17 patients in our study had bilateral enlarged parotid glands which subsided spontaneously or during treatment with corticosteroids.

Discrete, firm, painless enlargement of peripheral and superficial lymph nodes are observed in about one out of seven patients.¹⁸ Lymph node involvement is usually bilateral and relatively symmetrical. These nodes often regress spontaneously, and although responsive to corticosteroids, they are usually considered a justification for treatment. Hilar lymphadenopathy almost invariably accompanies peripheral lymphadenopathy. As was mentioned above only, p # 5 with a full blown picture of sarcoidosis developed adenopathy at the axillary areas. Now after 4 months she still has this sign without progression.

Although liver biopsy reveals liver involvement in 60 to 90 percent of the cases, usually it is not important clinically.¹⁹ A clinically enlarged liver is found in about 20 percent of the cases during the course of the illness. Cirrhosis, jaundice, ascites, and esophageal varices may be the end result in a few cases in which granulomatous involvement pursues a progressive unremitting course. Corticosteroid treatment suppresses the active inflammatory process but is not effective when irreversible cirrhosis has resulted. Patient # 6 of our series had liver enlargement. However, he is still under close observation and steroids were not administered.

Splenomegaly may occur in 20 to 30 percent of the patients and prompt regression usually follows corticosteroid treatment.²⁰ Again case # 6 had this physical finding without evidence of a rare complication such as thrombocytopenia as of yet.

Involvement of other organs was not seen in our study except for nasal involvement in patient # 17 and endobronchial disease in patient # 13.

The finding of granulomas in the mucous layer of the tracheobronchial tree of patient # 13 implied involve-

ment of the bronchial tree in this patient. Pt # 17 had erythema of the nose which still persists after 3 years.

Radiographic findings

Based on radiographic findings of the chest, sarcoidosis is identified in about 90 percent of patients.^{1,21,23} By international convention, the appearance is classified according to the presence of enlarged hilar lymph nodes, pulmonary infiltrates and fibrosis (Table V). The radiographic types may roughly parallel the evolution of the disease but there is no certainty that these occur as stages in all patients. The relative frequency of these types depends on the particular series reviewed and how it has been assembled.

Data from Siltzbach indicate that about 10 percent will have a normal chest radiograph. Approximately 40 percent will have hilar lymphadenopathy. The presence of hilar lymphadenopathy and pulmonary infiltrate is the most frequent manifestation in symptomatic patients and occurs in 30 to 50 percent of the patients. Infiltrates without lymphadenopathy, with or without fibrosis will be observed in approximately 15 percent.

In the UAB series comprised of 227 patients, 1.8 percent were classified as stage 0, 51 percent as stage 1, 29 percent as stage II and 12 percent as stage III of the disease. In the worldwide series including 3676 patients 8 percent were classified as stage 0, 46 percent as stage 1, 32 percent as stage II and 14 percent as stage III of the disease.

Stage 0, (i.e. normal chest radiograph but with some other clinical findings of sarcoidosis) is difficult to find in our country because of lack of routine computed tomography of the mediastinum which sometimes demonstrates lymph node enlargement not visible on routine chest x-ray. Stage I (i.e. bilateral hilar adenopathy without parenchymal involvement) was found in 14 of 17 patients (82%) of our cases.

In the English literature about 50 percent of the patients will exhibit this as their first radiographic manifestation of sarcoidosis. However, lymphadenopathy is very common in sarcoidosis and intrathoracic nodes are enlarged in 75 to 90 percent of all patients. Usually this involves the hilar nodes, but the paratracheal nodes are commonly involved.²⁴ Less frequently, there is enlargement of subcarinal, anterior mediastinal, or posterior mediastinal nodes. The high incidence of hilar node enlargement in our series was probably due to the fact that we used this as one of the criteria for diagnosing sarcoidosis. We usually did TBLB on the patients who had evidence of hilar node enlargement on chest x-ray. Though 4 of the patients in Table I underwent TBLB only with parenchymal disease without having any evidence of hilar node enlargement, we primarily viewed these patients as having some other entity like lymphatic spread of malignancy

Table V. Radiographic stages of sarcoidosis

Stage	Description
0	Normal
I	Hilar adenopathy
II	Hilar adenopathy and parenchymal infiltrate
III	Parenchymal infiltrate

or alveolar cell carcinoma and incidentally sarcoidosis was found upon biopsy. Interestingly enough we had quite a number of patients with diffuse pulmonary infiltrates mostly found in older women in our country with the diagnosis of idiopathic pulmonary fibrosis; however, they were not followed due to their stable conditions. These cases may have been sarcoidosis in the past who later referred to our clinic. We will probably find some satisfactory answer for this in the future.

Bilateral hilar adenopathy with pulmonary infiltrates. (i.e. stage II of the disease), was seen in 32 percent of the cases worldwide. The infiltrates may be fine linear markings, coarse reticulonodules, or fluffy cotton wool confluent shadows. Pulmonary infiltrates appear most often within the first or second year of illness and occasionally occur within weeks of onset. Ten of our 17 patients (60%) referred in this stage of the disease. Pulmonary function studies in these patients showed moderate to severe restrictive patterns. Two of these cases (# 9 and # 17) had severe dyspnea which was deteriorating as the disease progressed, so we were obliged to put them on steroids. We continued treatment with prednisolone for almost 3 years for case # 9 and 1 year for case # 17 and whenever we decided to discontinue the medication, the disease progressed rapidly and the dyspnea worsened. At the present time they have almost no complaints and the chest x-ray is clear despite discontinuation of steroids for months.

Stage III of the disease (i.e. pulmonary infiltrates without lymphadenopathy), is sometimes divided into subgroups A and B depending on the evidence of pulmonary fibrosis. It most frequently represents a later stage of the disease. Evidence of fibrosis and fibrocystic or bullous changes are often observed.

The radiographic patterns of this stage are easily confused with the similar configuration of pulmonary tuberculosis involving the upper zones, fibrosing alveolitis, progressive systemic sclerosis, extrinsic allergic alveolitis, rheumatoid lung, congestive heart failure, and advanced bullous emphysema. At the time of initial diagnosis, about one of every seven patients exhibits features of this fibrotic irreversible stage of pulmonary sarcoidosis. The degree of fibrosis ranges from clinically inconsequential linear streaks of nodular densities of limited extent,²⁵ to widespread scarring and bullae that are totally disabling. As was mentioned

above we see quite a number of these x-ray changes in our departments in otherwise healthy old women and we do not have a definite diagnosis. Could these patients have stage III sarcoidosis? Unfortunately lack of cooperation on behalf of the patients did not allow us to perform a complete work-up including TBLB and search for evidence of sarcoidosis. Four of our 17 cases (23 percent) were found to be in this stage of the disease, all proven by TBLB. In none of them was there any evidence of acute stages of the disease like erythema nodosum.

Laboratory findings

Most of the laboratory findings including CBC, differential count, sedimentation rate, enzyme profiles, electrolytes, serum uric acid, serum and urine calcium, serum phosphorus and alkaline phosphatase, protein and immunoelectrophoresis were within normal limits in our patients. Even case # 6 with the full blown picture of sarcoidosis had normal values upon laboratory evaluation.

Unfortunately we do not have the necessary facilities to perform sophisticated laboratory exams such as a gallium scan and serum angiotensin converting enzymes, but we know that these tests are valuable for evaluating progression of the disease and have no specificity for diagnosis of sarcoidosis.

CONCLUSION

In conclusion, sarcoidosis is not a rare disease in Iran. TBLB is a good way of diagnosing the disease especially when we have parenchymal involvement on chest x-ray. Though stage I of the disease was more common in our study, we think that this is not universal and if we perform more TBLB on the patients with evidence of pulmonary fibrosis on x-ray, we will probably find more patients with stage III sarcoidosis and less with stage I of the disease.

REFERENCES

1. Crystal RG, Roberts WC, Hunninghake GW, et al: Pulmonary sarcoidosis: a disease characterized and perpetuated by activated lung T-lymphocytes. NIH conferences. *Ann Intern Med* 94: 73-94, 1981.
2. Thrasher DR, Briggs DD: Pulmonary sarcoidosis. *Clinics in chest medicine. Interstitial lung disease*, 537-63, 1982.
3. Hillerdall G, Nou E, Osterman K, et al: Sarcoidosis: epidemiology and prognosis, a 15-year European study. *Am. Rev Respir Dis* 130: 29-32, 1984.
4. James DG, Williams WJ: Sarcoidosis and other granulomatous disorders. In: Smith LH (ed), *Major Problems in Internal Medicine*. Vol. 24, Philadelphia, Saunders, 1985.
5. Hunninghake, GW, Crystal RG: Pulmonary sarcoidosis: a disorder mediated by excess helper T-lymphocyte activity at sites of disease activity. *N Engl J Med* 305: 429-34, 1981.
6. James DG, Williams WJ: Immunology of sarcoidosis. *Am J Med* 72: 5-8, 1982.
7. Fulmer, JD, Crystal, RG: Interstitial lung disease. In: Simmons DH (ed): *Current Pulmonology*. Vol 1, Boston, Houghton Mifflin, 1979.
8. Mitchell, DN, Scadding JG: State of the art: sarcoidosis. *Am Rev Respir Dis* 110: 774-802, 1974.
9. Mitchell DN, Scadding JG: Sarcoidosis. *AM Rev Respir Dis* 110: 774-802, 1974.
10. Johns CJ: Sarcoidosis: Pulmonary Disease and Disorders. Alfred Fishman, Vol 1. 619-44, 1988.
11. James, DG: Sarcoidosis. In: Besson EJ, McDermott W, Wyn-gaarden JB (eds): *Cecil textbook of medicine*. Philadelphia, WB Saunders, 1975.
12. Bacharach T: Sarcoidosis: a clinical review of 111 cases. *Am Rev Respir Dis* 84: 12-6, 1961.
13. Maycock, RL, Bertrand P, Morrison CE, et al: Manifestations of sarcoidosis. *Am J Med* 35: 67-89, 1963.
14. Sones, Israel HL: Course and prognosis of sarcoidosis. *Am J Med* 28: 84-93, 1960.
15. Thrasher DR, Briggs DD, Prophet D, et al: Review of 227 patients with sarcoidosis at UAB Medical Center. Unpublished data, 1982.
16. Sarcoidosis and other granulomatous disorders. Ninth International conference. Chretien J, Marsac J, Saltiel JC (eds), Paris: Pergamon, 1981.
17. James DG: The diagnosis and treatment of ocular sarcoidosis. *Act Med Scand* 176 (Suppl. 425): 203, 1964.
18. Williams WJ, Davies BH (eds). Cardiff, Wales, Alpha Omega, Eighth International Conference on Sarcoidosis and other Granulomatous Diseases, 1980.
19. Israel, HL, Goldstein RA: Hepatic granulomatosis. *Ann Intern, Med* 79: 669, 1973.
20. Bruschi M, Howe JS: Classification of the hematologic variations and abnormalities associated with Boeck's sarcoid. Review of the literature. *Blood* 5: 478, 1950.
21. Bernstein SS, and Sussmass, ML: Thoracic manifestations of sarcoidosis. *Radiology* 44: 37-43, 1945.
22. Kirks DR: McCormick VB, Greenspan RH: Pulmonary sarcoidosis: roentgenographic analysis of 150 patients. *A J R* 117: 777-86, 1973.
23. Sitzbach LE, James DG, Neville E, et al: Course and prognosis of sarcoidosis around the world. *Am J Med* 57: 847-524, 1974.
24. Fraser RG, Pare JAP: *Diagnosis of Diseases of the Chest*. Philadelphia: W.B. Saunders, 1979.
25. Sharma O P, Hewlett R, Gordonson J: Nodular sarcoidosis: an usual radiographic appearance. *Chest* 64: 189-92, 1973.