

# MODIFIED RADICAL MASTOIDECTOMY: TECHNIQUES TO DECREASE FAILURE

MOHAMMAD AJALLOUEYAN, M.D.

*From the Dept. of ENT Surgery, Baghiyatollah Hospital, Baghiyatollah University of Medical Sciences,  
Tehran, I.R. Iran.*

## ABSTRACT

The aims of surgical treatment for cholesteatoma include complete removal of disease and formation of a dry, self cleaning ear in addition to hearing reconstruction. This presentation concentrates on techniques of open mastoid surgery or modified radical mastoidectomy to achieve a well-constructed cavity. This study analyzes both primary and revision mastoid surgery referred to the author. All patients presented with otorrhea, and four patients presented with facial paralysis, two with labyrinthine and one with oval window fistula.

Sclerotic mastoid with extensive cholesteatoma were indications for modified radical mastoidectomy as the treatment of choice. The main method of hearing reconstruction in an open cavity with a mobile stapes was type III tympanoplasty, leading to an improvement in the average air bone gap following surgery in both primary and revision groups. The major causes of failure that were found when revising mastoid cavities were incomplete removal of air cell tracts and inadequate mastoid cavity formation without a sufficient meatoplasty. The techniques of open mastoid or modified radical mastoidectomy that are required to avoid failure are discussed.

**Keywords:** Mastoidectomy, Cholesteatoma.

*MJIRI, Vol. 13, No. 3, 179-183, 1999*

## INTRODUCTION

The aims of cholesteatoma surgery are to achieve a dry, self cleaning ear and complete removal of disease. A review of literature shows fluctuating trends in the numerous techniques that have been developed and used by otologists throughout the years.<sup>1-4</sup> Early otologists believed that the conversion of all cholesteatomas into radical cavities was

the treatment of choice. The intact canal wall techniques were first published by Jansen,<sup>5</sup> but much controversy undoubtedly continues in establishing the optimal technique for managing cholesteatomas.

The objective of the present study has been to follow a trend toward the creation of an open cavity rather than intact canal wall surgery to reduce the risk of recurrent and residual disease. The techniques of modified radical mastoidectomy (MRM) that are described in this paper have led to eradication of disease, with the opportunity to restore ossicular chain continuity.

There has been a longstanding problem with terminology

\*Address for correspondence: M. Ajalloueyan, M.D., 31-Delpazir Place-Shahid Rahmani St., Pirooz Square, Sadr Freeway, Tehran, I.R. Iran. Tel: 2558585 Fax: 2830261

## Modified Radical Mastoidectomy: Techniques To Decrease Failure

but the author defines MRM as an operative technique that includes extensive removal of tympanomastoid air cell tracts and exteriorization of air cells to create an open cavity. The middle ear and drum is then reconstructed.

### METHODS

The medical notes of patients who underwent primary or revision MRM for cholesteatoma between June 1992 and August 1995 were retrospectively reviewed. The hospital records and correspondence with clinicians were used for follow up.

The following information was obtained: age and sex of patients, symptoms on admission and postoperatively, the duration of follow-up, and the cavity status. Intraoperative findings with particular attention to the stapes superstructure and footplate status were recorded. For the revision cases, the time from the original surgery was noted, along with the specific sites and cause of failure.

All patients underwent surgery by the author, the referral sources were otolaryngologists and general practitioners. The average postoperative air bone gap (ABG) at 0.5, 1, 2 and 4 kHz (i.e., the difference between the average bone and air conductions) was used as an indicator of objective functional hearing.

### Surgical technique

The important surgical concepts involved in open modified radical mastoidectomy are related to extensive and complete removal of air cell tracts and the creation of a well constructed cavity.<sup>6</sup> The skin incision must provide access to the mastoid tip, sinodural angle and sufficient anterior exposure to provide access to the anterior epitympanum and canal wall.

The mastoidectomy involves wide removal of bone from the middle fossa dura, sinodural angle, sigmoid sinus and digastric ridge. The facial nerve is identified in the

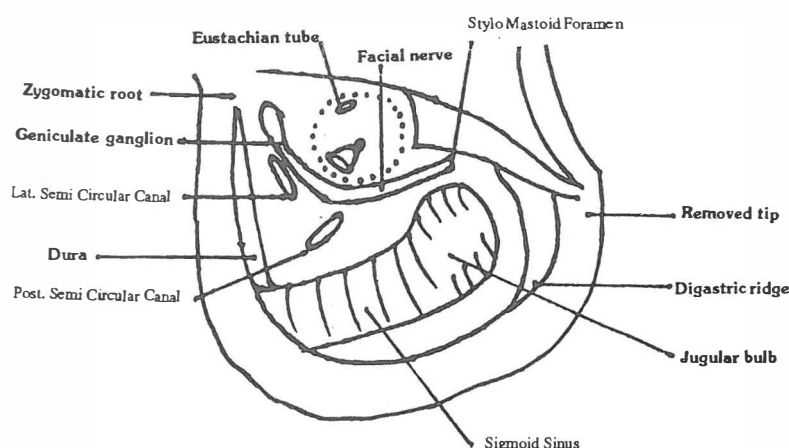
**Table I. The clinical presentation of patients with cholesteatoma.**

Pre-operation	Primary n=49		Revision n=29		Total n=78	
Otorrhea	49	100%	29	100%	78	100%
Vertigo	14	28%	9	31%	23	30%
Facial paralysis	0	0%	4	14%	4	3.7%
Hearing loss	49	100%	29	100%	78	100%
Intact stapes	29	60%	18	62%	47	61%

**Table II. Postoperative hearing results.**

Air Bone Gap	Primary n=49		Revision n=29		Total n=78	
0-10	9	18%	3	10%	12	14%
0-20	23	47%	12	41%	35	44%
0-30	35	71%	20	68%	55	69%
0-40	49	100%	25	85%	74	94%
>40	0	0%	4	14%	4	6%

mastoid or vertical portion in the region of the stylomastoid periosteum. The digastric muscle is clearly exposed and the stylomastoid periosteum provides an important landmark for the vertical facial nerve and allows removal of the mastoid tip at a later stage. The facial "ridge" is then lowered to the level of the facial nerve as far as the second genu.



**Fig. 1. Wide exteriorization of the mastoid.**

Table III. Hearing results with respect to the status of the ossicular chain.

Air Bone Gap	Stapes Superstructure Present (n=47) (60%)		Stapes Superstructure Absent (n=31) (40%)	
0 - 10	11	24%	3	9%
0-20	24	51%	5	17%
0-30	36	76%	8	25%
0-40	41	92%	31	100%
>40	6	8%	0	0%

The retrolabyrinthine, retrofacial and epitympanic air cells are completely removed. The wide removal of the epitympanic cells provides exposure to the supralabyrinthine and supratubal air cell tracts. The removal of supratubal and supralabyrinthine air cell tracts requires careful dissection in the region of the tympanic and labyrinthine portions of the facial nerve.

The anterior epitympanum dissection extends as far as the root of the zygoma and is made continuous with a wide anterior canal wall enlargement. The tympanic annulus must be completely visible. The wide canalplasty is then extended inferiorly as far as the digastric ridge to create a circular cavity.

The mastoid tip is then removed after complete mobilization along the digastric ridge, lateral to the stylomastoid periosteum and anterior to the facial nerve. The tip is dissected from the underlying digastric muscle with care to avoid the stylomastoid foramen and facial nerve (Fig. 1).

The tympanoplasty does not involve the use of ossiculoplasty material. A type III tympanoplasty is usually carried out in the presence of an intact and mobile stapes. Temporalis fascia is placed under the remnant of anterior tympanic membrane and over the enlarged, inferior canal wall. The graft is either placed directly over the stapes head or a small piece of cartilage is placed in between. The tensor tympani tendon is carefully preserved, if possible, to provide important structural support to the handle of the malleus and drum.

## RESULTS

Of 278 cases of mastoid surgery during the time, seventy-eight patients with cholesteatoma were evaluated including 41 men and 37 women. Among the patients, 29 cases were referred to the author after having undergone mastoid surgery at other centers. The clinical presentation of the two groups varied.

### Primary MRM group

All 49 patients in this group had not previously undergone mastoid surgery. These patients presented with persistent otorrhea and hearing loss of either a conductive or mixed nature. Vertigo was present in 28% of patients (Table I). The stapes superstructure was present and intact in 29 patients (60%). A type III tympanoplasty using a cartilage graft placed onto the stapes superstructure was performed in 15 cases, others underwent tympanoplasty with the tympanic membrane placed directly over the stapes suprastructure.

Following surgery, a dry ear was achieved in all patients at no later than 9 weeks. Vertigo was cured in 8 patients but only two labyrinthine fistulae were found at surgery. Subjective hearing improved in 35 patients (71%), remained the same in 14 (29%) and no patient reported further hearing loss. An average ABG of less than 10 dB was found in 18% of patients, and an ABG of less than 20 dB was found in 47% of patients (Table II).

### Revision MRM group

Twenty-nine patients underwent revision MRM, of which twenty-five were performed by other otolaryngologists and four by the author. The average time from original surgery was 5.6 years (range 10 days to 15 years).

Recurrent persistent discharge and deafness was the main complaint in this group. Vertigo was present in 31%, and facial paralysis in 14% of patients (Table I).

A dry ear was achieved 2-3 months post-operation in all patients. Vertigo was cured in all patients of whom one was found to have a labyrinthine fistula and two an oval window fistula. Subjective hearing improved in 20 patients (68%), remained the same in 9 patients and nobody complained of further hearing loss. Facial paralysis improved partially in one and completely in three patients. The stapes superstructure was present and intact in 18 patients (62%). In the remaining 11 patients, 9 had only a footplate (of which one had a labyrinthine fistula), and two patients had no footplate (and consequently an oval window fistula). A type III tympanoplasty using a cartilage graft placed onto the

stapes suprastructure was performed in 18 patients (61%).

Following surgery, an average ABG of less than 10 dB was found in 10% of patients, and an ABG of less than 20 dB was found in 41% of patients (Table II). Further, in patients in whom the stapes superstructure was present, 24% had an ABG of less than 20 dB (Table III). The mean follow up period for the primary cases was 35 (range 28 to 49) and for the revision cases 33 months (range 28 to 46 months). A dry ear was achieved in all patients without serious complications (meningitis, CSF leak, facial paralysis) and only four patients required subsequent surgery. It is important to note that these hearing results were obtained without a second stage ossicular chain reconstruction.

## DISCUSSION

Cholesteatoma is a histologically benign disease. However, the natural behaviour may be characterized by locally aggressive and invasive properties associated with significant morbidity and occasional mortality. Interleukin-1 alpha, a cytokine found in cholesteatomatous keratinocytes, has been shown to activate neutrophils and lymphocytes during inflammatory processes, stimulate osteoclasts, and to release collagenase and prostaglandin E-2 from fibroblasts. Granulation tissue associated with cholesteatoma has been shown to contain a parathyroid-hormone-related protein. These features may all lead to consequent bony destruction and complications of cholesteatoma.<sup>7</sup>

The major aims of surgery for cholesteatoma are removal of the disease and the creation of a dry, safe ear. The technique must prevent recurrent or residual cholesteatoma and reconstruct the ossicular chain mechanism. The procedure of intact canal wall mastoidectomy is designed to accomplish these aims without removing the external auditory canal. The limitations of this approach are reflected by an unacceptably high rate of recurrent and residual cholesteatoma.

The understanding of recurrent and residual cholesteatoma following mastoid surgery is important. Residual cholesteatoma refers to keratinizing epithelium that remains after a surgical procedure. Recurrent cholesteatoma is defined as the presence of a secondary acquired cholesteatoma that appears following the complete removal of a previous cholesteatoma. The rate of residual cholesteatoma varies greatly, but has been reported in up to 57% of cases following intact canal wall surgery.<sup>8-12</sup> Intact canal wall technique is characterized by limited access to the sinus tympani and anterior epitympanum in poorly pneumatized temporal bone. This may lead to inadequate removal of the cholesteatoma with residual disease or inadequate ventilation of the epitympanum leading to recurrent cholesteatoma. The major site of residual cholesteatoma following intact canal wall surgery was in the

region of the attic, stapes and sinus tympani.

Further surgery involving a "second look" procedure is mandatory following closed cavity surgery. Modified radical mastoidectomy, when performed as described, is associated with a low rate of recurrent and residual disease. A frequently described disadvantage of modified radical mastoidectomy with tympanoplasty is the production of a wet, discharging cavity. The results of this series show that a discharging cavity which is caused by inadequate bone removal can be avoided in nearly all cases with meticulous surgical technique.

The principle of creating a dry and self-cleaning mastoid cavity involves extensive surgery. The major site of residual air cell tracts that were found to be contributing to discharging cavities at the time of revision mastoid surgery were those in the retrolabyrinthine and supralabyrinthine areas. The surgical technique must remove these air cell tracts when involved with significant disease. The wide access approach provides perfect exposure of the epitympanic, retrolabyrinthine and supralabyrinthine regions which are exteriorized with the remainder of the open cavity.

The long term hearing results obtained following intact wall surgery are not significantly better than open cavity hearing levels despite the preservation of a more anatomically normal middle ear.<sup>4</sup>

The author recommends that the decision with regard to the technique of mastoid cholesteatoma surgery should be based upon the patient's needs and the experience of the surgeon. In general, the judgement between open and closed surgery is based upon the degree of pneumatization of the temporal bone and the extent of the cholesteatoma. Therefore, the major indication for intact canal wall surgery is in a patient with extensive pneumatization but with a localized cholesteatoma. The remainder are dealt with using the described open technique.

## REFERENCES

1. Sheehy JL: Cholesteatoma surgery: canal wall down procedures. *Ann Otol Rhinol Laryngol* 97: 30-35, 1988.
2. Sade J: Treatment of cholesteatoma. *Am J Otol* 8: 524-533, 1987.
3. Smyth GDL: Canal wall up or canal wall down for cholesteatoma? *Am J Otol* 6: 1-2, 1987.
4. Toner JG, Smyth GDL: Surgical treatment of cholesteatoma: a comparison of three techniques. *Am J Otol* 4: 247-249, 1990.
5. Jansen CW: Intact wall for cholesteatoma. *Am J Otol* 6: 3-4, 1985.
6. Fisch U, May J: Tympanoplasty, Mastoidectomy and Stapes Surgery. New York: Thieme, pp. 108-141, 1994.
7. Atlas MD, Paramesvaran S: Cholesteatoma-a dangerous condition. *Aust J Otolaryngol* 7: 394-397, 1996.
8. Sheehy JL, Brackmann DE, Graham MD: Cholesteatoma surgery: residual and recurrent disease: a review of 1,024 cases. *Ann Otol Rhinol Laryngol* 86: 451-462, 1997.
9. Sheehy JL, Patterson ME: Intact canal wall tympanoplasty with mastoidectomy: a review of eight years experience. *Laryngoscope* 77: 1502-42, 1967.

10. Schuring AG, Lippy WH, Rizer FM, Schuring LT: Staging for cholesteatoma in the child, adolescent, and adult. *Ann Otol Rhinol Laryngol* 99: 256-60, 1990.
11. Gristwood RE, Venables WN: Factors influencing the probability of residual cholesteatoma. *Ann Otol Rhinol Laryngol* 99: 120-3, 1990.
12. Rosenfeld RM, Moura RL, Bluestone CD: Predictors of residual-recurrent cholesteatoma in children. *Arch Otolaryngol Head Neck Surg* 118: 384-91, 1992.
13. Gyo K, Hinohira Y, Sasaki Y, Yanagihara N: Residue of middle ear cholesteatoma after intact canal wall tympanoplasty: surgical findings at one year. *Ann Otol Rhinol Laryngol* 99: 615-9, 1996.

