

Endovascular repair of traumatic pseudoaneurysm of the descending thoracic aorta: report of three cases and review of articles

Mohammad Mozaffar¹, Hamidreza Haghhighatkah², Hafez Zirakzadeh³
Morteza Sanei Taheri⁴, Fateme HosseiniZadegan Shirazi⁵

Vascular Surgery Department, Shohadaye Tajrish Hospital, Shahid Beheshti University of Medical Sciences, Tehran, Iran.

Received: 22 Nov 2010

Revised: 3 Mar 2011

Accepted: 8 May 2011

Abstract

Traumatic descending thoracic aorta pseudo aneurysms have been treated traditionally with open surgery in the past, which have had noticeable rates of mortality and morbidity. A safer method of treatment for this disease is made possible with recent progress in endovascular treatment techniques. In this article, we present three cases of Traumatic descending thoracic aorta pseudo aneurysms that were treated with Thoracic endovascular aortic repair (TEVAR) and discharged from our clinic without any complication.

Keywords: trauma, pseudoaneurysm, descending thoracic aorta, endovascular repair.

Introduction

Aortic injury is a rare but lethal lesion in the patients who arrive at the emergency room after falling down.

The conventional treatment of aortic injuries with open techniques has been accompanied with high rates of morbidity and mortality. In a meta-analysis which was published in 1994 and studied articles of 20 years, mortality rate of open techniques was reported to be 32% and 9.9% paraplegic after the surgery [2].

Endovascular treatment of traumatic thoracic aorta injuries has many advantages over open surgery. Patients involved in

traumatic accidents frequently have multiple organ system injuries like lung contusion, rib fracture, abdominal organ injuries and head trauma. Thoracotomy, clamp of aorta and massive blood transfusion which are likely to happen in open surgery can be very harmful in these patients. For a long time, the only treatment option of thoracic aorta injuries has been open surgery. Recent advances in the field of endovascular surgery and interventional radiology have opened a new chapter in the treatment of this lethal lesion. The advantage of EVAR over open surgery in the treatment of traumatic aortic injuries is shown in several studies [3, 4]. Aortic repair with endovascular graft is a non invasive and

1. Associate Professor of Vascular Surgery, Shohadaye Tajrish Hospital, Shahid Beheshti University of Medical Sciences and Health Services, Tehran, Iran. mohamad_mozafar@Yahoo.com

2. Assistant Professor of Radiology, Shohadaye Tajrish Hospital, Shahid Beheshti University of Medical Sciences and Health Services, Tehran, Iran. drhaghhighatkah@yahoo.com

3. **(Corresponding author)** Resident of General Surgery, Shohadaye Tajrish Hospital, Shahid Beheshti University of Medical Sciences and Health Services, Tehran, Iran. htfzrk@yahoo.com

4. Assistant Professor of Radiology, Shohadaye Tajrish Hospital, Shahid Beheshti University of Medical Sciences and Health Services, Tehran, Iran. drhaghhighatkah@yahoo.com

5. Resident of General Surgery, Shohadaye Tajrish Hospital, Shahid Beheshti University of Medical Sciences and Health Services, Tehran, Iran. fati_h80@yahoo.com

safe method which has lower rates of morbidity and mortality [4].

The use of endovascular grafts in the treatment of traumatic arterial lesions was first described by Dotter in 1969 [5]. Dake, in 1994 first reported the treatment of a traumatic aortic aneurysm with an endovascular graft [6]. Endovascular treatment methods are advancing rapidly in recent years. Here we present two cases of falling down in which the patients were successfully submitted to endovascular treatment for traumatic pseudoaneurysm of the descending thoracic aorta.

Case study

The first case

A 17 year old male worker was referred to our institution about 30 minutes after falling down 20 meters from a building. On arrival at the emergency department the patient was conscious with a Glasgow Coma Scale score of 15. The patient's vital signs included a blood pressure of 110/70 mm Hg, a heart rate of 88 beats/min and a respiratory rate of 19. The examination of head and neck revealed no abnormality. The patient's chest expansion was symmetric and his lungs were clear to auscultation bilaterally and with no emphysema. His abdomen was nondistended. Tenderness, abrasion and bruise were detected at the left side of the

upper lumbar vertebral column. Genitalia were normal. No pelvic instability or long bone fractures were appreciated at initial examination and the patient was spontaneously moving all extremities.

After getting an IV line and sending a blood sample for hemoglobin and cross matching tests a FAST ultrasonography was performed due to abdominal tenderness and there was no fluid in peritoneum. A chest x-ray was then obtained and there was no evidence of pneumothorax or rib fracture but the mediastinum was wide (Fig. 1). A Foley catheter was placed and gross hematuria was detected. The vital signs were stable after 3 hours of observing the patient. A CT scan of thorax and abdomen was then performed and showed a hematoma at the upper pole of the right kidney without any extravasation of contrast from urinary tract. Other hematomas were also observed at the right psoas and paravertebral muscles. The chest CT scan with intravenous contrast revealed a traumatic pseudoaneurysm of the descending thoracic aorta just 15 millimeters from the left subclavian artery origin. The length of the pseudoaneurysm was 40 millimeters (Figs. 1&2). Pleural effusion and bilateral lower lobe pulmonary contusions were detected as well. The patient was taken to the intensive care unit.

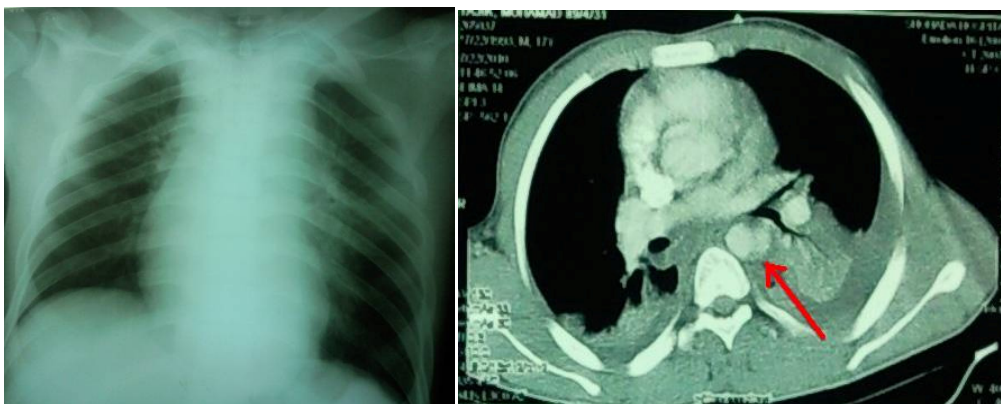


Fig. 1. A. The mediastinum appears to be wide in the chest x-ray; B. The pseudoaneurysm is marked with red flash in the CT scan

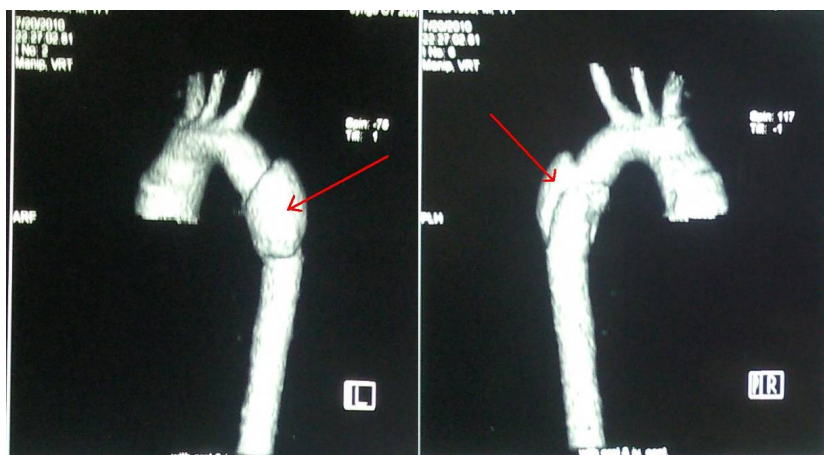

Fig. 2. The thoracic aorta CT angiography. The pseudoaneurysm is marked with red flash about 15 millimeters distal to the left subclavian artery origin.

An endovascular approach to repair the pseudoaneurysm was chosen considering the overall condition of the patient. The patient was taken to the operating room for endovascular stenting where a team of vascular surgeons, radiologists and anesthesiologists were present. The procedure was carried out under general anesthesia. After gaining access to organ open exploration of the left femoral artery with a small angiographic incision was performed and the pseudoaneurysm was revealed at 15 millimeters distal to the origin of the left subclavian artery. The length of pseudoaneurysm was 45 millimeters. The graft was then placed via a femoral sheath (Zenith TX2 graft). The CT angiography after the procedure demonstrated exclusion of the pseudoaneurysm with no evidence of an endoleak and the 80 millimeters graft could be seen behind the left subclavian

artery (Fig. 3).

Ten days after the injury another abdominal CT scan was performed. This time the prerenal hematoma revealed smaller but hydronephrosis of right kidney and dilatation of right urethra were present with a calcified density at the distal portion of the right urethra. The patient was taken to the operating room again to evaluate the urethra. A one centimeter stone was detected at the distal of right urethra. The stone was taken out and a double-J catheter was placed in the urethra. A few days later the patient was discharged from our institute.

The second case

A 24 year old male laborer was taken to our emergency department about 20 minutes after falling down 18 meters from a building. On arrival the patient was agitated but conscious. He could obey commands but unable

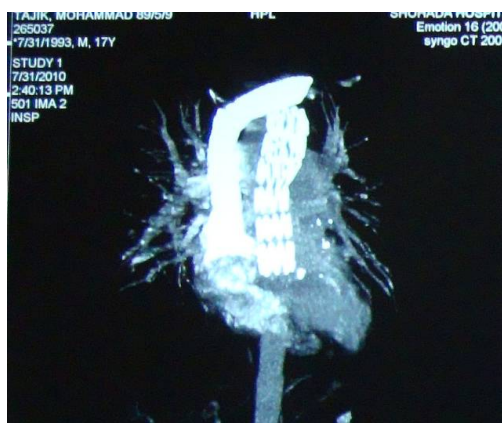

Fig. 3. CT angiography after repairing the pseudoaneurysm with graft.

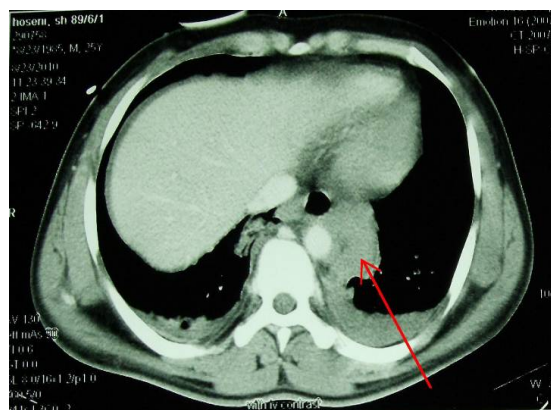


Fig. 4. CT scan of the abdomen. The lesion suspicious to hematoma is marked.

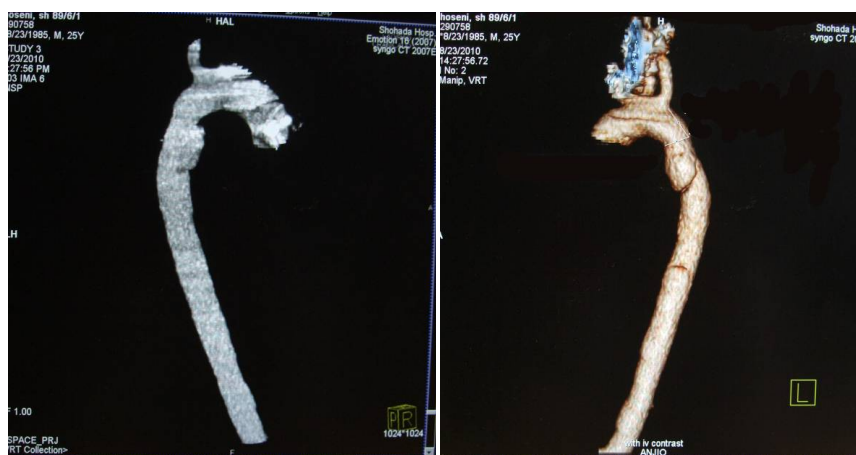

Fig. 5. The pseudoaneurysm is marked in 2D and 3D reconstruction of the thoracic aorta in CT angiography.

to speak. His pulse rate was 78, blood pressure 70/40 and respiratory rate 28. The mandible deformity was obvious and bleeding from oral cavity led to respiratory disturbance. The patient was intubated and his oral cavity suctioned. Two IV lines were inserted and blood samples for hemoglobin and cross match tests were sent and IV fluid therapy with Ringer serum was started. The chest expansion was symmetric and the lungs were clear to auscultation bilaterally. Both hemithoraxes were tapped and no pneumothorax or hemothorax was present. The abdomen was not distended and no abdominal guarding was present but tenderness could not be evaluated because the patient was agitated. The pelvis was stable and no deformity observed in the extremities. Distal pulses could not be detected because of the low blood pressure. After receiving two liters of Ringer serum the blood pressure reached

90/50. A diagnostic peritoneal lavage was performed and had negative result. One unit of blood was then transfused. The patient's vital signs became stable. A foley catheter was placed but no gross hematuria was detected.

After two hours vital signs remained stable. The patient was sent to radiology for a chest X-ray. Fracture of third and fourth ribs and pneumothorax were present at the right hemithorax, hence a chest tube was inserted immediately. The mediastinum was normal. An abdominal CT scan was performed to rule out retroperitoneal hematoma due to decline in initial blood pressure. The liver, spleen and retroperitoneum were normal but a density suspicious to hematoma was detected at the descending thoracic aorta (Fig. 4).

A CT angiography of the thoracic aorta revealed an outpouching vessel measured

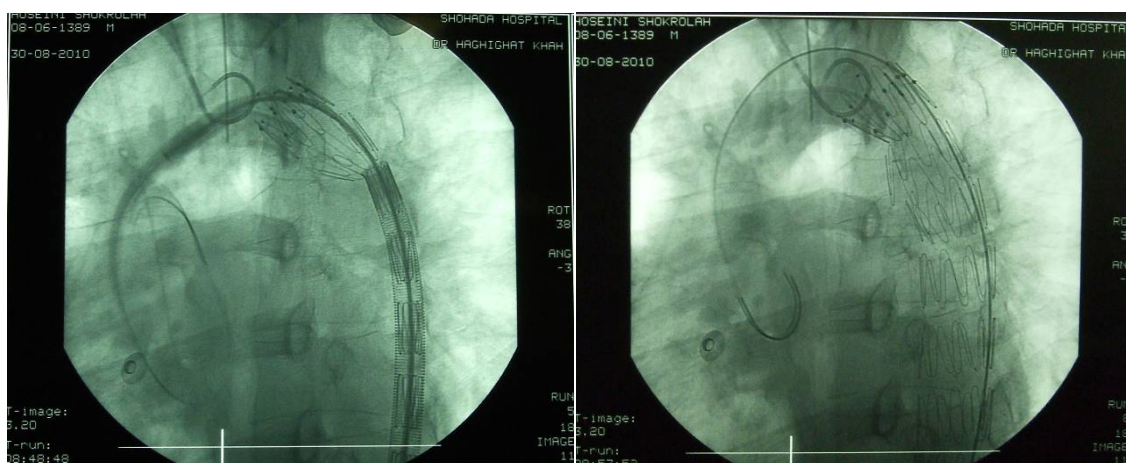


Fig. 6. The angiogram of inserting the graft into the descending thoracic aorta.

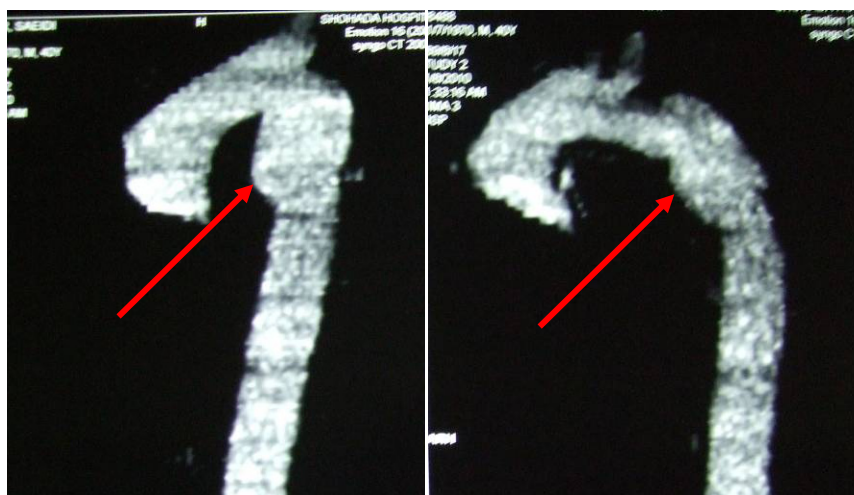


Fig. 7. The CT angiography of thoracic aorta revealed a pseudoaneurysm.

25×18 millimeters at the beginning of descending thoracic aorta, with no periaortic hematoma (Fig. 5). The patient was taken to surgical intensive care unit.

After preparing the facilities the patient was transferred to operating room and left femoral artery was explored under general anesthesia with a small incision. An angiography was performed and a pseudoaneurysm was observed about 12 millimeters distal to the left subclavian artery origin with the length of 35 millimeters. A 26×135 millimeters Zenith TX2 endograft was placed at the pseudoaneurysm site via the femoral sheath (Fig. 6). The arteriotomy was then closed with Prolene 6-0.

The patient was ex-tubated and discharged from our hospital with good condition a few days later and referred for maxillofacial surgery.

The third case

A 42 year old male driver was taken to our emergency department about 1 hour after a car accident. On arrival the patient's vital signs were as follows: pulse rate 110, respiratory rate 40, GCS 13 and blood pressure 90/60. The lungs expansion was normal but the left ribs had tenderness. The abdominal examination revealed generalized tenderness without rebound and guarding. The pelvis was stable and a deformity was detected in the left femur that showed an unstable fracture. The patient was resuscitated and a

FAST sonography was performed which showed no free fluid in the abdominal cavity. X-rays revealed fractures in three ribs in the left hemithorax, Pubic symphysis, left Iliac wing and left Femur. The Mediastinum appeared to be wide. Respiratory distress was occurred due to lung contusion after a while, hence patient was intubated and prophylactic chest tube inserted in the left hemithorax because of rib fracture.

The CT angiography of thoracic aorta was performed after detecting wide mediastinum and a 40 millimeters pseudoaneurysm was observed about 13 millimeters after the origin of left subclavian artery (Fig. 7).

The patient was transferred to intensive care unit. Acute tubular necrosis and renal failure occurred after a while which did not respond to hydration and medical therapy therefore patient underwent dialysis. Femur and pelvic fractures were treated with traction initially. A second CT angiography was done after two weeks which showed no growth in the size of pseudoaneurysm. The patient became febrile and sepsis due to pneumonia was diagnosed. Antibiotics were administered and tracheostomy was performed. Also external fixation for femur fracture was done. After two months, sepsis was treated and renal function returned to normal and the patient weaned from mechanical ventilation.

Patient was then transferred to operating room and his left femoral artery explored

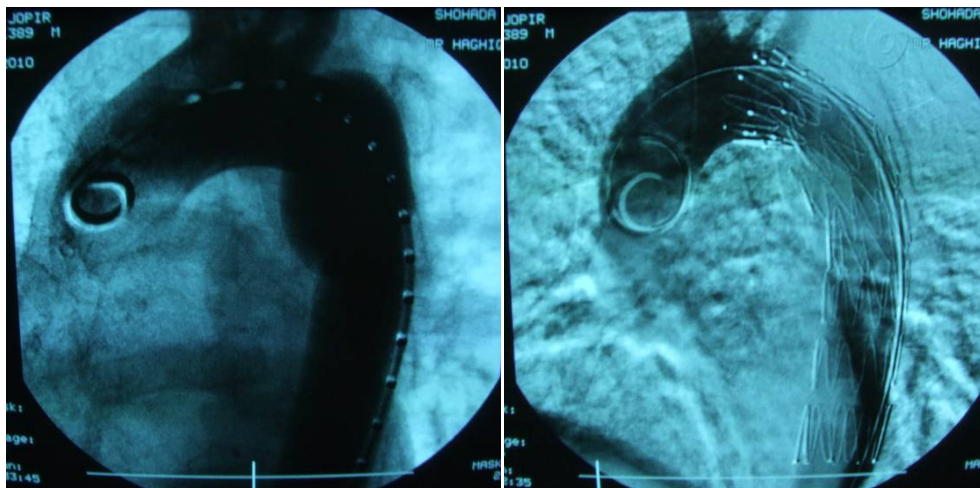


Fig. 8. The first picture shows the location of pseudoaneurysm and the second picture shows the stent graft after placing it from the origin of subclavian artery.

under general anesthesia and cannulated. The guide wire was passed and the pseudoaneurysm localized with angiography. After that the right axillary artery was cannulated and a pig tail catheter was inserted in the ascending thoracic aorta via axillary artery to facilitate the angiography. The stent graft catheter was inserted in the left femoral artery and guided to the descending thoracic aorta and the endograft placed at the origin of the left subclavian artery (Fig. 8). A control angiography demonstrated no leakage. The patient was discharged from our institute after a while with good condition.

Discussion

The classic treatment of a thoracic aortic pseudoaneurysm which is via open repair and aortic clamping has many complications, although it has acceptable results. The volume of hemorrhage is more than endovascular treatment and spinal cord ischemia can cause paraplegia in the open technique. In one study the complications of endovascular treatment of thoracic aorta aneurysms were as follows: cerebrovascular accidents 5%, paraplegia 3.7%, and aneurysm recurrence 7.4% whereas in the open technique paraplegia had occurred in 10% to 22% and renal failure and respiratory distress in up to 40% of the patients [7]. In another study mortality and paraplegia rate has been reported to be 21% and 7% respectively in

open technique whereas no case of mortality or paraplegia was seen in endovascular method [8]. The recent advances in endovascular methods have led to better treatment results and less complication.

Thoracotomy performed in the open surgery could have its own complications like atelectasia and pneumonia which are very hazardous to traumatic patients who may suffer from rib fracture and lung contusion. These complications are avoidable with endovascular technique.

The endovascular method for repair of injuries to the thoracic aorta eliminates the need for prolonged general anesthesia and intubation time and this can lead to less post operative ICU stay and hospitalization [9,10]

Although in some studies there was no significant difference between open and endovascular techniques [11]. In a meta-analysis published in 2009 the success rate of endovascular methods in treating large vessel injuries above the diaphragm has been reported to be 96.7% whereas its complications were 6.4% [12]. Recently, intravascular techniques have been used in repairing concomitant traumatic injury of two large intrathoracic vessels (Subclavian and thoracic Aorta) [13].

Endovascular repair of aorta can be performed without the need for anticoagulant therapy [14] and this can be of benefit in some patients in which anticoagulation is forbidden due to brain or intra-abdominal organ injuries.

The effectiveness of endovascular grafts in the long term has not been adequately evaluated yet and this should be concerned. Recently, some cases of intravascular graft collapse after several years of implantation has been reported [15]. Another important issue is the risk of graft infection and more studies are required to assess this risk.

We presented three cases of traumatic thoracic aorta pseudoaneurysms where an endovascular graft was used for treatment in a post traumatic patient. This suggests that endovascular method can be used as a safe and effective method of treatment in the high risk patients with multiple injuries.

References

1. Singh MJ, Rohrer MJ, Ghaleb M, Kim D. Endoluminal stent-graft repair of a thoracic aortic transection in a trauma patient with multiple injuries: case report. *J Trauma* 2001; 51:376–38.
2. U.O. von Oppell, T.T. Dunne, M.K. De Groot and P. Zilla, Traumatic aortic rupture: twenty-year metaanalysis of mortality and risk of paraplegia, *Ann Thorac Surg* 1994; 58: pp. 585–593.
3. G.L. Tang, H.Y. Tehrani, A. Usman, K. Katarriya, C. Otero, E. Perez and M.K. Eskandari, Reduced mortality, paraplegia, and stroke with stent graft repair of blunt aortic transections: a modern meta-analysis, *J Vasc Surg* 2008; 47: pp. 671–675.
4. E.S. Xenos, N.N. Abedi, D.L. Davenport, D.J. Minion, O. Hamdallah, E.E. Sorial and E.D. Endean, Meta-analysis of endovascular vs open repair for traumatic descending thoracic aortic rupture, *J Vasc Surg* 2008; 48: pp. 1343–1351.
5. Dotter CT. Transluminally placed coil spring end arterial tube grafts: long term patency in canine popliteal artery. *Invest Radiol* 1969;4:329-332.
6. Dake MD, Miller DC et al. Transluminal placement of endovascular stent grafts for treatment of descending thoracic aortic aneurysm. *N Eng J Med* 1994; 331:1729-1734.
7. Mitchell RS. Endovascular stent graft repair of thoracic aortic aneurysms. *Semin Thorac Cardiovasc Surg* 1997;9:257–268.
8. Rousseau H, Dambrin C, et al. acute traumatic aortic rupture: a comparison of surgical and stent-graft repair. *J Thorac Cardiovasc Surg* 2005 May; 129(5):1050-5.
9. Hughes GC, Lee SM et al. Endovascular repair of descending thoracic aneurysms: results with "on-label" application in the post Food and Drug Administration approval era. *Ann Thorac Surg* 2010 Jul; 90(1):83-9.
10. Carmona P, Collado B, Soriano JL, Mateo. Open surgery and endovascular treatment on the descending thoracic aorta: 15 years' experience. *Rev Esp Anestesiol Reanim* 2010 May; 57(5):293-6.
11. Azzadeh A, Keyhani K, Miller CC 3rd, Coogan SM, Safi HJ, Estrera AL. Blunt traumatic aortic injury: initial experience with endovascular repair. *J Vasc Surg* 2009 Jun; 49(6): 1403-8.
12. Hershberger RC, Aulivola B, Murphy M, Luchette FA. Endovascular grafts for treatment of traumatic injury to the aortic arch and great vessels. *J Trauma* 2009 Sep; 67(3): 660-71.
13. Teso D, Bloch R, Pohlman T, Karmy-Jones R. Simultaneous Endovascular Repair of Traumatic Rupture of the Right Subclavian Artery and Thoracic Aorta. *Ann Thorac Surg* 2011 Jan; 91(1): 281-3.
14. Garcia-Toca M, Naughton PA, Matsumura JS, Morasch MD, Kibbe MR, Rodriguez HE, Pearce WH, Eskandari MK. Endovascular repair of blunt traumatic thoracic aortic injuries: seven-year singlecenter experience. *Arch Surg* 2010 Jul; 145(7): 679-83.
15. Shukla AJ, Jeyabalan G, Cho JS. Late collapse of a thoracic endoprosthesis. *J Vasc Surg* 2011 Jan 5.