

Arthroscopic treatment of synovial chondromatosis of the shoulder joint: case report and review

A.A. Khorsandi, MD.¹

Department of Orthopedics, Iran Mehr Hospital, Iran University of Medical Sciences, Tehran, Iran.

Abstract

Two cases (20 and 15 years old) of shoulder joint synovial chondromatosis were initially treated with arthroscopic debridement. One was further treated with a second arthroscopy and partial synovectomy (case 1); the second was fully treated by arthroscopic surgery (case 2). The postoperative control X-ray revealed no loose body and the joint was normal. One of the cases (case 1) was affected by Degenerative Joint Disorders (DJD) according to X-ray and arthroscopic findings after treatment; physiotherapy was started as soon as possible. The use of arthroscopic surgery allowed the patients to return to normal activity much sooner than a formal open synovectomy. Additionally, the morbidity associated with arthroscopic techniques is much lower than that of an open procedure.

Synovial chondromatosis is a condition resulting from intrasynovial formation of multiple metaplastic cartilaginous foci. When these foci are enlarged, they become pedunculated and are extruded into the joint as loose bodies. Subsequently, these loose bodies calcify and ossify and continue to grow because they are nourished by the synovial fluid that surrounds them. Although synovial chondromatosis can affect most joints, it very rarely affects the shoulder joint.

Keywords: synovial chondromatosis, synovial osteochondromatosis, synovectomy, debridement, arthroscopic surgery of the shoulder joint.

Introduction

Synovial chondromatosis is a rare, debilitating condition that affects diarthrodial joints. It has been reported to affect, in order of frequency, the knee, hip, elbow, wrist, ankle and shoulder. The largest series of patients with synovial chondromatosis was reported by Mayo clinic, and of their 32 cases, only one involved the shoulder. The first case involving the shoulder was reported by G. Richard Paul in 1970. He described a patient with shoulder involvement. He also observed a patient with bilateral synovial chondromatosis, first noted in one shoulder at 31 years of age and seen in the other shoulder 10

years later. Although, the cause of the condition is not known, it results from intrasynovial formation of multiple metaplastic cartilaginous foci. When these foci enlarge, they become pedunculated and are extruded into the joint as loose bodies; these further grow and can subsequently affect the bursae and tendon sheaths as well as eroding articular surfaces. When afflicting the shoulder, this disorder has traditionally been treated with open surgery, but recent developments indicate that arthroscopic treatment yields better results with reduced morbidity. The current paper presents two case reports of synovial chondromatosis of the shoulder treated with arthroscopic surgery.

1. **Corresponding author**, Assistant Professor of Orthopedic and Shoulder Surgery, Iran University of Medical Sciences, Iran Mehr Hospital, Gholhak, Tehran, Iran. Tel:+9821 22435390, email:alikhorsandi@yahoo.com>

Case reports

Case 1

A 20 year - old male was seen at Columbia Presbyterian Hospital in New York City. He reported constant pain and stiffness in his right shoulder. He said that the pain had started when he was still in high school, and that his pain prohibited him from playing golf and hockey. The patient reported that the pain and stiffness had recently increased. When examined, his forwards flexion was 160 degrees, his external rotation was 50 degrees and his internal rotation was to the sacrum. A neurovascular examination of the upper extremities revealed no weakness and there was no evidence of previous injury to the joint. The impingement test performed was negative and there were no signs of muscular atrophy. The laboratory studies that were performed included: CBC, ESR, U/A, Ca, P, Serum electrolyte, and serum alkaline phos-

phatase. All were normal. However, X - rays taken from multiple views of the right shoulder revealed the presence of loose bodies, which are a symptom of synovial chondromatosis and DJD. The coronal, sagittal, and oblique axial MRI views revealed the presence of a large intra-articular effusion of the glenohumeral joint with the presence of multiple osteocartilaginous loose bodies consistent with the diagnosis of synovial osteochondromatosis.

As a result of this diagnosis, the patient underwent arthroscopic debridement of the synovium on July 20, 1992. During the course of the operation 40-50 loose bodies were removed. It was felt that nearly all of the loose bodies had been removed. Therefore a large gaitor was used to remove all the loose bodies. since there were so many areas of active red synovitis, a second look and a second synovectomy was performed. A 13 mm OB/GYN catheter was inserted into the joint. This large

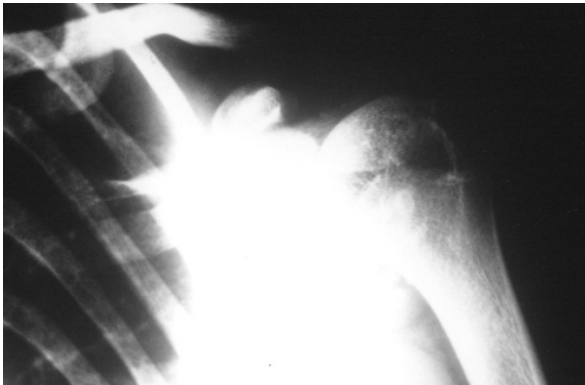


Fig. 1. Before surgery.

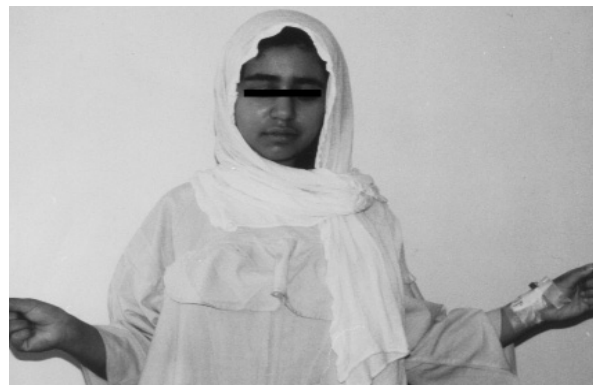

Fig. 3. External rotation before surgery.



Fig. 2. Forward flexion before surgery.



Fig. 4. Internal rotation before surgery.

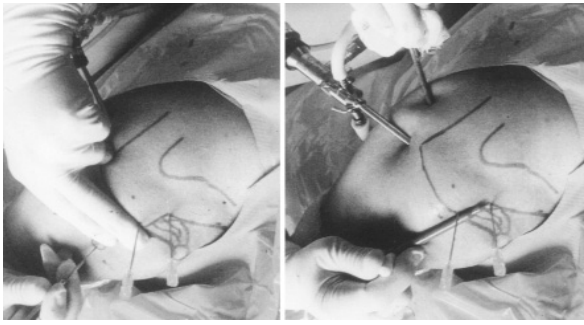


Fig. 5. Arthroscopic view.

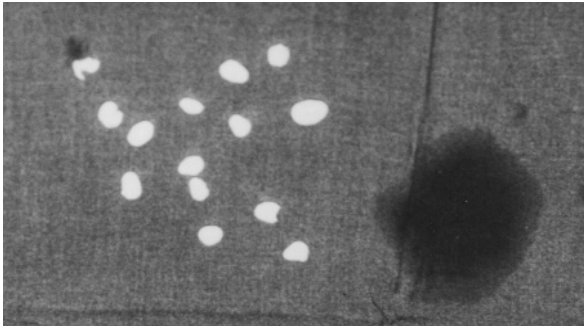


Fig. 6. Loose bodies.

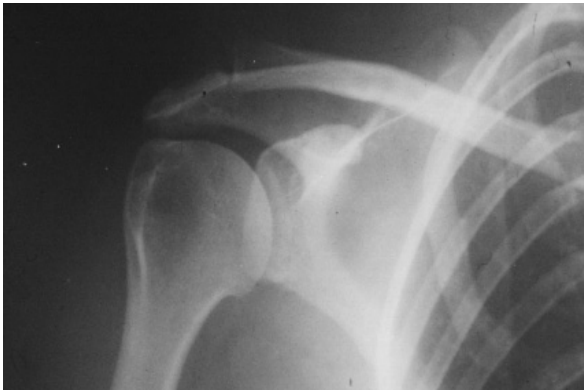

Fig. 7. Control X - ray after surgery.

cannula was then used to suck out all the remaining loose bodies from the anterior and posterior parts of the glenoid. After this, a further synovectomy was performed.

Four days after operation, the patient showed moderate swelling of the shoulder joint. A control X - ray showed a few loose bodies that still remained in the joint. In spite of this, the patient's symptoms greatly improved. Another arthroscopy was recommended and physiotherapy was started. After two months and five days, the second arthroscopic procedure was performed. More loose bodies were removed

from the glenohumeral and subcoracoid regions of the joint. During the procedure, a control X- ray showed at least eight loose bodies. These eight loose bodies were trapped in the synovium. As it was felt that it was too dangerous to remove these loose bodies, they were left alone.

X- Rays taken four months and two weeks postoperatively demonstrated no new loose body formations. The patient reported no pain. The forward flexion was 180 degrees, external rotation was 70 degrees, and internal rotation was to the T8.

Nine months postoperatively, the patient's range of motion had decreased, which is not uncommon. The patient's forward flexion was 170 degrees, his external rotation was 70 degrees, and his internal rotation was T 8. One year and seven months after his second synovectomy, the patient's forwards flexion had increased to 175 degrees, his external rotation decreased to 60 degrees, and his internal rotation improved to T 5. New X-rays revealed no new loose bodies and the patient was doing well.

Case 2

A 15 year - old female was seen in August 1999 in Iran Mehr hospital in Tehran. She complained of intermittent moderate right shoulder pain and a mild swelling that aggravated with activity and diminished with rest. In addition, she reported frequent locking and giving way, but she did not report any true dislocation. There was swelling at inspection and crepitus in palpation. Apprehension test, anterior draw test, and sulcus sign were all negative. Her shoulder's range of motion was limited: Forward flexion was 150 degrees, external rotation 50 degrees, and internal rotation to T10. X-rays revealed multiple loose bodies without any sign of DJD (figure 1). Laboratory tests including CBC, ESR, U/A, Ca, P, serum electrolytes, and serum alkaline phosphatase were all normal.

The patient underwent shoulder arthroscopy,



Fig. 8. Forward flexion after surgery.



Fig. 9. External rotation after surgery.

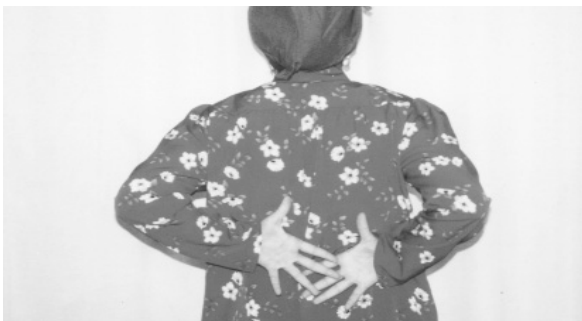

Fig. 10. Internal rotation after surgery.

and 14 loose bodies were removed without synovectomy. The loose bodies were nearly spherical in shape and 3-9 mm in diameter. Articular surfaces of the humeral head and glenoid fossa were normal. Microscopic examination of all 14 loose bodies showed synovial chondromatosis. Three days after operation, physiotherapy was started and continued for 10 days. Her symptoms disappeared and her shoulder range of motion increased. In the last follow up, five months postoperatively, she did not show any signs or symptoms mentioned above and her shoulder range of motion was nearly normal: forward flexion was 175 degrees, external rotation 70 degrees, and internal rotation to T2.

There were no loose bodies on X-ray and the patient was well (figures 1-10).

Discussion

Typically, synovial chondromatosis is a slow degenerative disease that usually effects large joints (knee, elbow, shoulder, and hips) in young adults and ultimately leads to joint destruction [1]. After extensive study of this disease, Dr. James Milgram identified three distinctive stages of the disease [2].

In the first stage, there is active synovial disease only, with no loose bodies, the second stage shows transitional versions with both active intrasynovial proliferation and free loose bodies. The third phase shows multiple free osteochondral bodies with no demonstrable intrasynovial disease.

Although Dr. Milgram and colleagues advocated the simple removal of the loose bodies, especially for patients in the third stage of the disease, others do not agree. They stress the need for synovectomy and recommend removal of the source of the cartilaginous metaplasia. However, recurrences after arthrotomy and partial synovectomy have been reported [3]. Christensen and Poulson have 5 recurrences in a series of 16 patients with synovial chondromatosis of the shoulder treated with arthrotomy [4]. Surgical treatment of synovial chondromatosis by open arthrotomy potentially requires a longer postoperative course of rehabilitation. Full visualization of the entire joint space is often difficult, requiring a maneuver of "milking" the loose bodies from the posterior aspect of the joint, in comparison, the arthroscopic technique has far fewer comorbidities and a shorter course of rehabilitation.

In the 3 previously reported cases of arthroscopic treatment for synovial chondromatosis of the shoulder [5,6,7], the patients returned to work shortly after the procedures as did our patients. The key to the arthroscopic technique is the use of multiple portals that allow complete visualization of the glenohumeral joint space

and associated recesses along with easy retrieval of loose bodies. Removal of the free intra-articular loose bodies does not always result in radical synovectomy because of the complexity of the anatomy in that region [8]. Extra-articular loose bodies [9], in a few cases, may be confused with a low-grade chondrosarcoma [10]. In contrast, an intra-articular location favors the benign diagnosis of synovial chondromatosis [11]. In such cases, MRI or CT scan with or without arthrography might pinpoint the exact site of involvement. Plain X-ray demonstrates only loose bodies in approximately 50% of cases [12]. Diagnosis of synovial chondromatosis is often delayed because the symptoms are generally mild initially [13, 14]. The patient often reports a history of moderate pain, swelling, and stiffness with duration of several months. The differential diagnosis includes: arthropathies, which are present with intra-articular loose bodies, DJD, neurotrophic arthritis pseudo-gout, tuberculosis arthritis, lymphoma, RA, and osteochondral fractures, which should be ruled out [15].

In these two cases, the patients were relieved from pain and returned to normal function. It is believed that the disease may be self-limiting [2]. Removing the loose bodies may be all that is necessary during the arthroscopic operation [16]. Finally, the natural course of the synovial chondromatosis varies in some patients [17]. It becomes progressively disabling, so that some types of operative procedures must be performed [18].

It is our belief that arthroscopy offers a better visualization of the glenohumeral joint, decreases postoperative pain, and allows a shorter course of postoperative rehabilitation with earlier functional return.

References

1. Pual GR, Leach RE. Synovial chondromatosis of the shoulder. *Clin Orthop* 1970; 68: 130-135.
2. Milgram JW. Synovial osteochondromatosis: a histopathologic study of thirty cases. *J Bone Joint Surg Am* 1977; 59: 792-801.
3. Jeon IH, Ihn JC, Kyung HS. Recurrence of synovial chondromatosis of the glenohumeral joint after arthroscopic treatment. *Arthroscopy* 2004; 20:524-527.
4. Christensen JH, Poulsen JO. Synovial chondromatosis. *Acta Orthop Scand* 1975; 46: 919-925.
5. Covall DJ, Fowble CD. Arthroscopic treatment of synovial chondromatosis of the shoulder and biceps tendon sheath. *Arthroscopy* 1993; 9: 602-604.
6. Richman DJ, Rose DJ. The role of arthroscopy in the management of synovial chondromatosis of the shoulder. *Clin Orthop* 1990; 257: 91-93.
7. Fowble VA, Levy HJ. Arthroscopic treatment for synovial chondromatosis of the shoulder. *Arthroscopy* 2003; 19: [PubMed abstract].
8. Gasbarrini A, Biscaglia R, Donati D, Casadei R, Picci P. Synovial chondromatosis of the shoulder. a review of the literature and description of a clinical case. *Chir Organi Mov* 1997; 82: 73-81.
9. Werner A, Wild A, Mueller T, Borys A, Gohlke F, Krauspe R. Primary synovial chondromatosis of the shoulder. *Zorthop Ihre Grenzgeb* 2002; 140: 404-408.
10. Anract P, Katabi M, Forest M, Benoit J, Witvoet J, Tomeno B. Synovial chondromatosis and chondrosarcoma: a study of the relationship between these two diseases. *Rev Chir Orthop Reparatrice Appar Mot* 1996; 82: 216-224.
11. Covall DJ, Fowble CD. Arthroscopic treatment of synovial chondromatosis of the shoulder and biceps tendon sheath. *Arthroscopy* 1993;9:602-604.
12. Richmann DJ, Rose DJ. The role of arthroscopy in the management of synovial chondromatosis of the shoulder: a case report. *Clin Orthop* 1990; 257: 91-93.
13. Mishra KP. Synovial chondromatosis of the shoulder joint: a case report and review of literature. *East Afr Med J* 1987; 55: 130-132.
14. Sim FH, Dahlin DC, Ivin JC. Extra-articular synovial chondromatosis. *J Bone Joint Surg Am* 1977; 59: 492-495.
15. Tomes FR, Hardin NJ, Pledger Sr. Synovial chondromatosis of the shoulder: a case report. *Mil Med* 1978; 143: 872 - 874.
16. Pual GR, Leach RE. Synovial chondromatosis of the shoulder. *Clin Orthop* 1970; 68: 130-5.
17. Volpin G, Nerubay J, Oliver S, Katznelson A. Synovial osteochondromatosis of the shoulder joint. *Am Surg* 1980;46: 422-424.
18. Edinger DT, Manley PA. Arthrodesis of the shoulder for synovial osteochondromatosis. *J Small Anim Pract* 1998; 39: 397 -400.