

Primary Hodgkin's lymphoma of the parotid gland: a case report

N. Azarpira, MD.¹, M. J. Ashraf, MD.², and B. Khademi, MD.³

Department of Pathology, Transplant Research Center, Shiraz University of Medical Sciences, Shiraz, I.R. Iran

Abstract

We report a 30 year old woman who presented with a painless preauricular mass of two months duration. Superficial parotidectomy was performed for the patient. Histological examination and immunohistochemical findings were in favor of mixed cellularity Hodgkin's lymphoma (MCHD). According to this diagnosis the patient received local radiotherapy and during 4 months of follow-up no recurrence was seen. To our knowledge only one such case has been reported in the English literature to date by Uchinuma in 1988.

Keywords: Parotid, Lymphoma, Hodgkin's

Introduction

Lymphoid lesions of the parotid gland are much rarer entities than their epithelial counterparts. These lesions consist of reactive lesions such as hyperplastic intraparotid lymph nodes, lymphoepithelial cysts, lymphocytic sialoadenitis, and malignant lymphomas. In the literature, primary malignant parotid lymphomas have been rarely described. They form 0.2-0.8% of all malignant tumors in the parotid gland [1].

To establish the diagnosis of primary malignant lymphoma of the salivary gland, the lymphoma should be the principle man-

ifestation of the disease, with histologic proof of salivary parenchymal involvement [2]. The parotid gland is the most commonly affected site, whereas the submandibular salivary glands are affected in approximately 15% of cases [3,4]. Women develop lymphoma of salivary glands more frequently than men, especially if one considers those lymphomas that arise in association with Sjogren's disease. The peak age is in the sixth and seventh decades of life. Surveying the pertinent literature, one finds that Hodgkin's lymphoma rarely affects the salivary glands [2,4].

Primary salivary gland lymphomas are usually of the low-grade or intermediate-grade B cell lymphoma type, with the varied subtypes seen in nodal presentation. It

1. **Corresponding author:** Pathologist. Address: Transplant Research Center, Nemazi Hospital, Shiraz University of Medical Sciences, Shiraz, Iran. Telefax: 0098711-6276211, email: negarazarpira@yahoo.com

2. Department of Pathology, Shiraz University of Medical Sciences, Shiraz, Iran.

3. Department of Otolaryngology, Shiraz University of Medical Sciences, Shiraz, Iran.

is generally agreed that the prognosis of salivary gland lymphomas is more favorable than for those arising at nodal sites [2,8]. This is probably related to the frequently encountered nodular growth pattern or low grade histology and the initially low stage of the lymphoma at the time of diagnosis [9,10].

Case report

A 30 year old woman presented with a painless preauricular mass. Mean time of swelling preoperatively was 2 months. In past medical history no rheumatologic disease was present.

On physical examination the patient was afebrile and no cervical, axillary or inguinal lymphadenopathy or organomegaly was present. Radiological study of the chest was normal with no mediastinal widening. Clinically benign tumors of the salivary gland such as mixed tumor were suspected. Thus, a superficial parotidectomy was performed. Grossly the specimen consisted of a parotid gland which measured 5×4×2 cm. In cut section a fish fleshy enlarged lymph node 2×2×1 cm was present in the normal parenchyma of the gland (Fig. 1).

In histopathology, the architecture of a normal parotid gland was present with an enlarged intraglandular lymph node that was totally effaced by a large number of eosinophils, plasma cells, lymphocytes and atypical mononuclear cells admixed with classic Reed-Sternberg cells (Figs. 2,3).

For definite diagnosis the sections were immunostained by streptavidin-biotin method with the following panel of antibodies: (CD 15, DAKO, 1/100, antimouse), (CD30, DAKO 1/100, antimouse), (CD 45, DAKO 1/100, antimouse), (CD20, DAKO, predilute, antimouse). The classic Reed-Sternberg

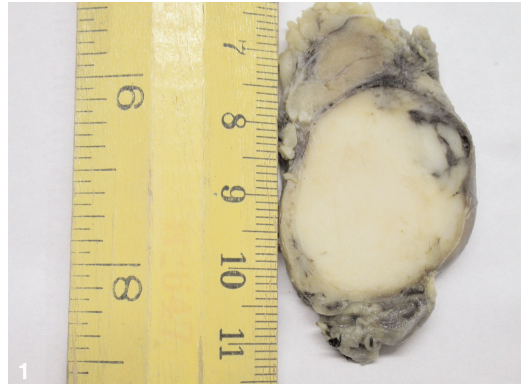

Fig. 1. An enlarged lymph node within the parotid parenchyma.

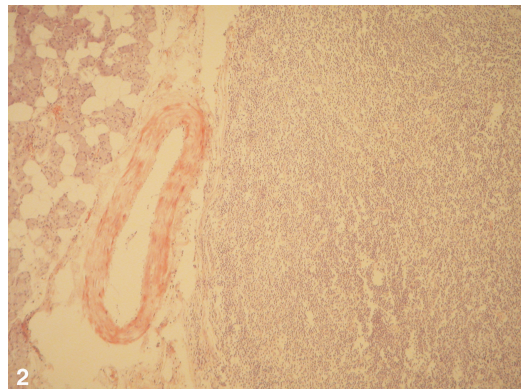


Fig. 2. Aggregation of lymphoid tissue adjacent to normal parenchyma of the parotid gland. (Hematoxylin –Eosin ×200)

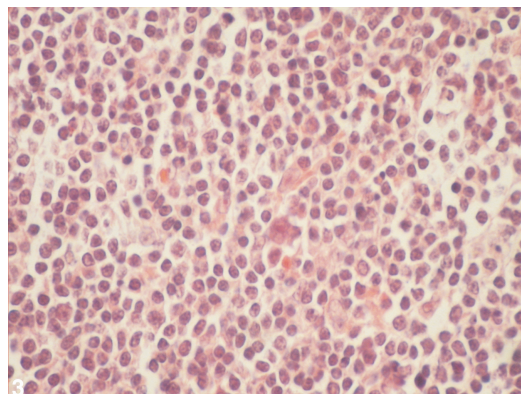


Fig. 3. Low power view of a mixed population of cells and Reed-Sternberg cells. (Hematoxylin –Eosin ×400)

cells were positive for CD15 and CD30 with negative staining for CD45.

Discussion

Malignant lymphoma in the parotid region may arise from an intraparotid lymph node or in the gland itself. In the former instance, the histologic features and natural history of the disease are those of nodal lymphoma in general.

When the salivary gland tissue is involved, this may represent the expression of disseminated involvement or, more commonly, a primary process of this organ [2,6]. The large majority of primary lymphomas of the salivary gland involve the parotid gland, but several cases of submaxillary gland disease are on record. Clinically, most present as unilateral masses [2]. The large majority of salivary gland lymphomas are of B-cell derivation composed of large cells, small cells, or mixed. The lymphomas composed of small lymphoid cells often arise against a background of Mikulicz's disease [2,4]. Some salivary gland lymphomas are of follicular type, with a follicular pattern of growth. The majority are currently regarded as belonging to the MALT /marginal zone type by a very slow evolution and an excellent long-term prognosis. In contrast, lymphomas composed of large cells run a rapidly progressive clinical course.

Finally, primary Hodgkin's lymphoma of salivary glands are rarely reported [4,8]. In Hodgkin's lymphoma the classic Reed-Sternberg cell with appropriate milieu in variable degrees are present. Our report represented a documented case of MCHD arising from an intraparotid gland lymph node, and review of the literature revealed only one such case in 1988 [10].

Acknowledgement

We are thankful to Miss Abedi and Mrs. Hakimzadeh for good slide preparation.

References

1. Von Stritzky M, Wereldsma JC, Pegels JG. Parotid mass as first symptom of a malignant lymphoma. *J Surg Oncol* 1998; 67(1):25-27
2. Juan Rosai. Major and minor salivary gland. In: Rosai and Ackerman's *Surgical Pathology*. 9th ed. NY: Mosby; 2004. pp. 896-897
3. Schmid U, Helbron D, Lennert K. Primary malignant lymphomas localized in salivary glands. *Histopathology* 1982; 6(6): 673-687.
4. Andrew G. Huvos and Augusto F. G. Paulino. Salivary glands. In: Stacy E. Mills, Darryl Carter, Victor E. Reuter et al. *Sternberg's diagnostic surgical Pathology*, 4th ed. Philadelphia: Lippincott & Williams Wilkins; 2004. pp. 933-962
5. Mehle ME, Kraus DH, Wood BG, Tubbs R, Tucker HM, Lavertu P. Lymphoma of the parotid gland. *Laryngoscope* 1993; 103: 17-21
6. Gleeson MJ, Bennett MH, Cawson RA. Lymphoma of salivary glands. *Cancer* 1986; 58:699-704
7. Chomette G, Guilbert F, Auriol M, Vaillant JM. Lymphoma of the salivary glands: New nosologic frontiers. *Rev Stomatol Chir Maxillofac* 1990; 91(1):32-35
8. Yench MW. Primary parotid gland Hodgkin's lymphoma. *Ann Otol Rhinol Laryngol* 2002 ;111(4): 338-342.
9. Tanaka T, Sugiura T, Watanabe S, Saito R, Ogura Y, Hayashi K, Ohnoshi T. A salivary gland lymphoma involving contralateral parotid gland and submaxillary gland with a review of the literature. *Hiroshima J Med Sci* 1984; 33: 113-123
10. Uchinuma E, Abe K, Shioya N. A case of Hodgkin's disease arising from an intraglandular lymph node in the parotid gland. *Br J Plast Surg* 1983; 11(3): 252-254