

Osteoid osteoma of a scapula: a case report in a 34 years old woman

Hojjat Hossein Pourfeizi¹, Jafar Ganjpour Sales², Asghar Elmi³, Ali Tabrizi³

Department of Orthopedics, Tabriz Medical University, Tabriz, Iran.

Received: 25 February 2012 Revised: 12 May 2012 Accepted: 23 May 2012

Abstract

Osteoid osteoma is a benign bone tumor and accounts for 10% of benign tumors. Almost any bones can be involved but half of cases involving femur or tibia. Osteoid osteoma is a rare tumor of the scapula with only 18 reported cases in the literature. We presented a case of osteoid osteoma of the scapula in right shoulder in angle of coracoid and geloneid in a 34- year old woman. She had right radicular shoulder pain increased at night for 4 years. An important point about this case is that, patient was treated in long-term with miss diagnosis of cervicospinal discopathy. The key of diagnosis in this patient was paying attention to the nature of night increasing pain and performing bone scan. After the operative curettage of the tumor, the pain dramatically stopped and a few weeks of physical therapy led to full range of motion in her shoulder.

Keywords: Osteoid osteoma, Scapula, Shoulder.

Introduction

Osteoid osteoma is the third most common benign bone tumor. It usually affects the diaphysis of long bones, especially the femur or the tibia, although many believe it is nonneoplastic. It was first described in 1935 by Jaffe (1). It accounts for 10% of benign bone tumors (2). It is twice as common in males as in female, and the highest incidence occurs in the second and third decades (3). After 30 years old, it is rare. The coracoid process is a rare location for a scapular tumor. In a series of 243 bone tumors and tumor-like conditions of the scapula, only 18 cases involved the coracoid process (4).

The proximal femur is the most common

location followed by the tibia, posterior elements of the spin and the humerus (5).

Pain is usually only symptom of disease presented in patients and is typically describe as mild and intermittent of first constantly with increased severity at night. Intermittent and aching night pain readily relieves using salicylate which marks the early phase, but later the pain becomes constant and severe and may not respond to medication (6).

The location of this neoplasm remains unclear, though it has developed in the coracoid process and the subglenoid region (7). Radiographic findings include sclerosis, but a nidus may be difficult to see on radiography. Bone scans and CT are often required

1. Associate Professor of Orthopedics, Orthopedics Department, Tabriz Medical University, Tabriz, Iran. hojjat.pourfeizi@gmail.com

2. Assistant of Orthopedics, Orthopedics Department, Tabriz Medical University, Tabriz, Iran. j-ganjpour@yahoo.com

3. (**Corresponding author**), Assistant of Orthopedics, Orthopedics department, Tabriz Medical University, Tabriz, Iran. elmimail@yahoo.com

3. Resident of Orthopedics, Orthopedics Department, Tabriz Medical University, Tabriz, Iran. ali.tab.ms@gmail.com

to localize the lesion accurately. Treatment includes surgical excision of the nidus (8).

Case report

The patient was a 34-year old woman with chief complaint of right radicular shoulder pain for 4 years which referred to Shohada Training Hospital of Tabriz University of Medical Sciences.

The pain was decreased, with daily activity and increased at night.

At physical examination there was tenderness around shoulder with joint movement restriction over 90° of abduction with painful external rotation.

Shoulder plain x-rays were normal. The bone scan revealed obvious increased uptake at superolateral angle of scapula (Fig. 1). The CT scan showed relatively ossified 1cm nidus with mild peripheral hyperdensity (Fig. 1). The lesion was at a few millimeters from subchondral bone of glenoid (Fig 2). Nerve Conduction Velocity (NCV) revealed neurogenic pattern at L5-L6 level muscles.

Surgical Technique: In the supine position with right shoulder elevation we performed a J shape incision such as the one used for coracoclavicular screw fixation. (Fig-3) Anterior insertion of deltoid to clavicle was incised with 1cm remnant.

After coracoid exposure, we performed drill hole with 2.7 drillbit on the tip of the coracoid. Coracoid was cut leaving its tendon insertions attached. On the base of coracoid next to the glenoid there was small dimpling. After corticotomy 1.51/5cm dense calcified tissue was removed and the hole completely curetted.

Coracoid was reattached using screw and deltoid sutured to clavicle. (Fig. 4) The original pain was subsided immediately after the surgery. In order to improve the range of motion of the shoulder, physical therapy was performed when the surgical pain relieved. Two months after surgery full range of motion in shoulder was obtained. Histologic diagnosis was osteoid osteoma.

Discussion

Because the scapula is a rare site for oste-

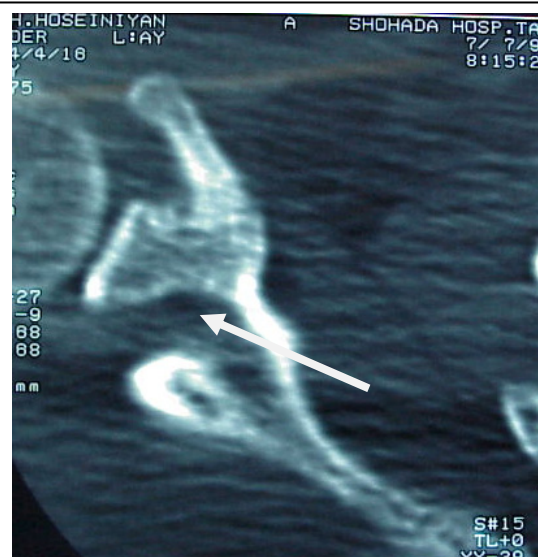

Fig. 1. CT scan shows hypodense lesion with same surrounding hyperdensity at coracoglenoid junction.

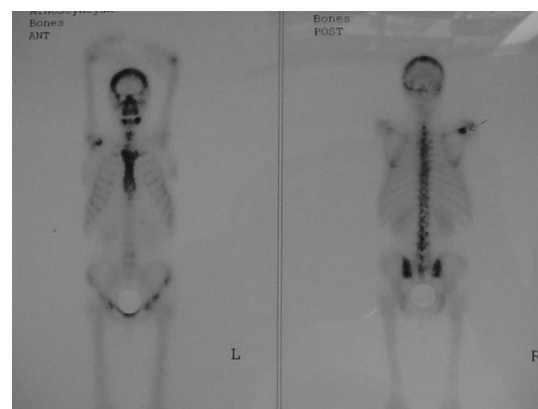


Fig. 2. Bone scan shows marked increased uptake at super lateral angle of scapula.

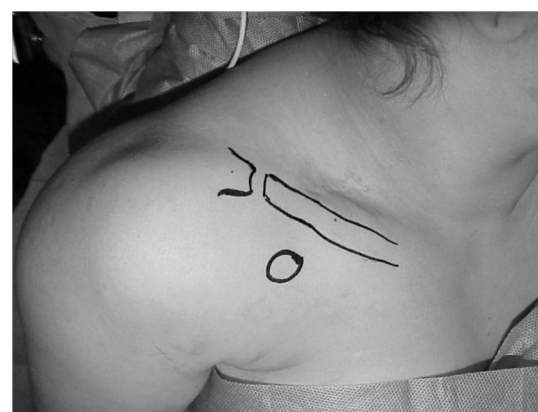

Fig. 3. Roberts approach of acromioclavicular joint and coracoid process of scapula.

oid osteoma, it is not often included in the differential diagnosis of chronic shoulder pain (7). The night pain seen is often attributed to rotator cuff pathology. However,

the age range of the patients in these cases would make rotator cuff pathology less likely. Glanzmann et al reported osteoid osteoma presented by localized stiffness of the anterosuperior capsule which led to the chief complaint of painful restriction of external rotation in the adducted arm position only (7). In fact, osteoid osteoma typically occurs in adolescence, whereas rotator cuff pathology would be unusual in that population. In particular, juxta-articular osteoid osteoma often presents a diagnostic dilemma secondary to referred pain, neurologic deficits, and global extremity weakness (8). The sensitivity of soft tissue radiographic techniques for the shoulder can also be problematic. Lesions in the labrum may be identified but may not be the cause of the patient's symptoms (9). According to Ogose et al report, bone tumors of the coracoid process may be difficult to detect on plain radiographs. In the patient with persistent shoulder pain unresponsive to the selected treatment, additional imaging studies should be considered to eliminate the possibility of a bone lesion (10).

Benign osseous lesion of the shoulder is uncommon, osteoid osteoma and osteoblastoma occur in the proximal humerus or scapula in 10 to 15% of cases and when they do occur, favor the proximal humerus or glenoid (11). The en bloc excision in uncommon subglenoid region can be problematic, since the surgical exposure is difficult, and shoulder Joint function can be affected if the lesion is subchondral (12).

Mosheiff et al reported a case of osteoid osteoma of the scapula with excision of the lesion by guided needle biopsy (8). In surgical treatment by Ponali et al, the excision of the lesion and grafting was performed by a deltopectoral approach (10). One year after the surgery, the patient remains pain free and has full range of motion with no recurrence of the tumor. Another reported by Akpınar et al, the en bloc excision of the osteoid osteoma was managed by an anterior approach using an osteotomy of the coracoid process had successful results (11).

Du ssaussois L et al reported a new thera-

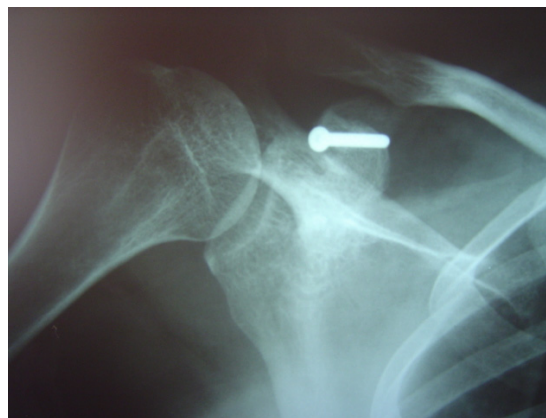

Fig. 4. Post up controlled shoulder plain x-ray.

peutic modality uses in a patient with an osteoid osteoma of the scapula. They successfully destroyed the nidus by percutaneous laser photocoagulation under CT guidance. Clinical improvement was manifested after 72 hours and the patient remained asymptomatic at months follow up (14). In Degreef et al case report, osteoid osteoma in the acromion was successfully treated by an acromioclavicular (AC) joint resection (4).

At our case the unusual site as well as age and gender of the patient and common complaint of radicular neck and shoulder pain with mechanical nature caused long delayed diagnosis and treatment. Although osteoid osteoma is a very rare cause of radicular shoulder pain but it's ignoring result in prolonged relentless night pain. Paying attention to night increasing nature of pain is the key guide of diagnosis.

In osteoid osteoma choice of treatment is radio frequency ablation (R.F.A). This treatment was noninvasive and had good results (14). In RFA a minimum amount of bone is removed during the procedure and the patient can return to normal function almost immediately (15). Another treatment of osteoid osteoma is surgical excision of the nidus (9-12), but anatomic unusual site can produce some technical and rehabilitation difficulties. In our experience in training center of orthopedics, operation procedure was as successful as non-surgical treatment especially in patients with unusual anatomical presentation.

Conclusion

Osteoid osteoma of the scapula is a challenging case to diagnose for several reasons. Because a differential diagnosis is unlikely and far-fetched, these tumors can be misdiagnosed for long time and treated as cervical radicular pain.

References

1. Jaffe H. Osteoma: a benign osteoblastic tumor composed of osteoid and atypical bone. *Arch surg* 1935; 31:709.
2. Swee RG, Mcleod RA, Beabout JW. Osteoid osteoma. *Radiology* 1979;130: 117-123.
3. Dahlin DC. Bone tumors: general aspects and data on 6,221 cases. Springfield, Illinois: Charles C Thomas, 1978: 43-569 75-85.
4. Degreef I, Verduyck J, Debeer Ph, De Smet L. An unusual cause of shoulder pain: Osteoid osteoma of the acromion: A case report. *J Shoulder Elbow Surg* 2005; 14:643-644.
5. Bloem J, Kroon M. Osseous lesions, *Radiologic clinics of North American*, 1993; 31(2):261-277.
6. Edeiken J, Dalinkam, Karasick D. Edeiken's roentgen diagnosis of diseases of Bone. 4th Baltimore, Williams Wilkins; 1990; p.44-64.
7. Glanzmann MC, Hinterwimme S, Woertler Klaus, Andreas B. Osteoid osteoma of the coracoid masked as localized capsulitis of the shoulder. *J Shoulder Elbow Surg* 2011; 20,e4-e7.
8. Moshieff R, Leibergall M, Zivi, Amirg, Segal D. Osteoid osteoma of the scapula. *Clin Orthop* 1991; 262:129-131.
9. Anne MK, Ronald M S, Erika L, O'Brien SJ and Drakos MC. Arthroscopic Removal of an Osteoid Osteoma of the Shoulder. *The Journal of Arthroscopic and Related Surgery* 2002; 18(7): 801-806.
10. Ogose A, Sim FH, O'Connor MI, Unni KK. Bone tumors of the coracoid process of the scapula. *Clin orthop* 1999; 358:205-214.
11. Poyanli O, Unay K, Akan K, Ozkan K, Temiz D. Subchondral osteoid osteoma of the glenoid. *Chir Organi Mov* 2009; 93(1):79-81.
12. Akpinar S, Demirors H, Hersekli MA, Yildirim T, Barutcu O, Tandogan RN. Osteoid osteoma in the base of the coracoid process of the scapula. Excision by anterior approach: a case report. *Bull Hosp Jt Dis* 2001; 60(1):47-9.
13. Dussaussois L, Stelmaszyky, Golzariang. Percutaneous treatment of an osteoid osteoma of the scapula using a laser under scanner control. *Acta orthop Belg* 1998; 64(1):88-91.
14. Daria Motamedi, Thomas J. Learch, David N. Ishimitsu, Kambiz Motamedi, Michael D. Katz, Earl W. Brien, Lawrence Menendez. Thermal Ablation of Osteoid Osteoma: Overview and Step-by-Step Guide. *RadioGraphics* 2009; 29:2127-2141.
15. Akhlaghpour S, Tomasian A, Arjmand SA, Ebrahimi M, Alinaghizadeh MR. Percutaneous osteoid osteoma treatment with combination of radiofrequency and alcohol ablation. *Clinical Radiology*

