

## Case Reports

### PENDRED'S SYNDROME REVISITED

M.DJALILIAN, M.D., M.S., M.FARHADI, M.D., AND F.NAZEM, M.D.

*From the Department of Otorhinolaryngology, Iran University of Medical Sciences, Tehran, Islamic Republic of Iran.*

#### ABSTRACT

Pendred's syndrome is defined as a triad of congenital perceptive hearing loss, goiter, and abnormal perchlorate test.

Three brothers with Pendred's syndrome [P.S.] are reported. The oldest brother has hearing loss (he has been deaf and mute since childhood) and has a large goiter. A thyroid scan revealed euthyroid multinodular goiter and a perchlorate test was performed, and reported abnormal.

His brother had the same manifestations but with less severity and after subtotal thyroidectomy, the pathology report revealed follicular carcinoma.

The youngest brother had hearing loss since childhood but a normal sized thyroid. We report three patients and compare the frequency of their symptoms with that reported in the literature.

*MJIRI, Vol.2, No.4, 305-311,*

#### INTRODUCTION

Pendred's syndrome is an autosomal recessive form of sensorineural deafness associated with goiter in that the perchlorate test shows an abnormal organification of non-organic iodine. Perchlorates when administered to a healthy subject, bring about the immediate release of inorganic-bound iodine from the thyroid gland, while the organic-bound iodine remains affected. If perchlorate is given, following a tracer dose of iodine 131, a slight fall, if any, in the activity of the gland will be the only reaction in normal subjects. This demonstrates the fact that inorganic iodine is very rapidly assimilated (perchlorate test). On the other hand, an abnormal fall in the activity will be seen in patients suffering from Pendred's syndrome. The disease is presumed to result from a defect in the peroxidase system, possibly a reduction in the amount of peroxidase enzyme; the greater the defect the greater the fall in activity. The disease is found throughout the world and may account for 1 to 7 percent of cases of deafness.

There is no apparent tendency in the male-female ratio of the syndrome.<sup>1</sup> The most important feature of the defect is that only the basal cochlea is retained while the apical cochlea turns from a common cavity. The defect is caused by a fault in the development of the modiolus in the seventh fetal week. The lesion in the ears of patients with Pendred's disease similar to the thyroid defect possibly results from a deficiency in the peroxidase enzyme system. Three brothers of seven siblings who are affected by Pendred's syndrome are reported.

#### CASE REPORT

##### CASE I:

A 23 year old male was referred to the E.N.T. clinic for hearing loss evaluation. He has been deaf and mute since childhood.

His parents are related and he has five brothers and two sisters. His father died at age 70 of hypertension,

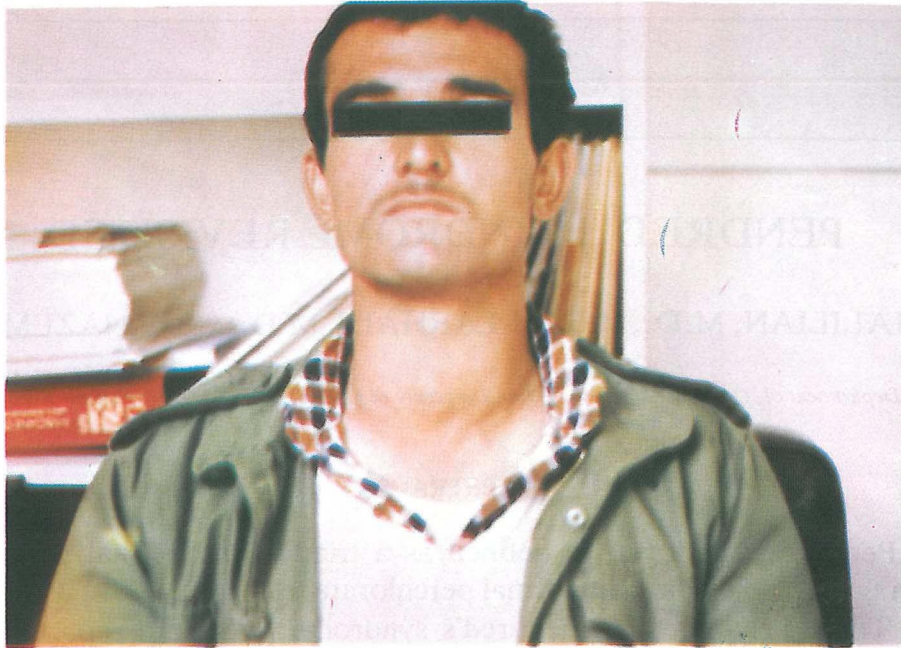

Fig 1. Case one depicting large goiter.

his mother is 60 years old and living. Two of his brothers have goiter associated with hearing loss (case II, III). One brother has hearing loss without goiter. The other brother is 32 years old and healthy without hearing loss and goiter.

Of his two sisters, the older one has goiter without hearing loss, and the other is in good health without any hearing loss or goiter. The past history was unremarkable.

On physical examination, he was well developed, well nourished, and had a large goiter (Fig. 1). Blood chemistry and urine analysis were within normal limits. Pure tone audiometry showed total deafness. The eye examination was unremarkable.

Thyroid scan (Fig.2) reported a euthyroid multinodular goiter and perchlorate test showed abnormal organification of nonorganic iodine (about 45%). Because of difficulty in breathing, thyroid extract was given for one year without any change in the size of the thyroid. Subtotal thyroidectomy was subsequently done without any problems, followed by thyroid extract.

#### CASE II:

A 22 year old male, brother of the first case had severe hearing loss since childhood accompanied with a large goiter (Fig.3). Blood tests and urine analysis was unremarkable; eye examination for retinitis pigmentosa was negative.

Thyroid scan (Fig. 4) reported euthyroid multinodular goiter; the fall in the perchlorate test showed about

55% abnormal organification of nonorganic iodine. Because of a sensation of pressure on his neck and difficulty in breathing, he was treated with thyroid extract for one year without any change in size of goiter, so he underwent subtotal thyroidectomy. The pathology report was follicular carcinoma (Fig.5).

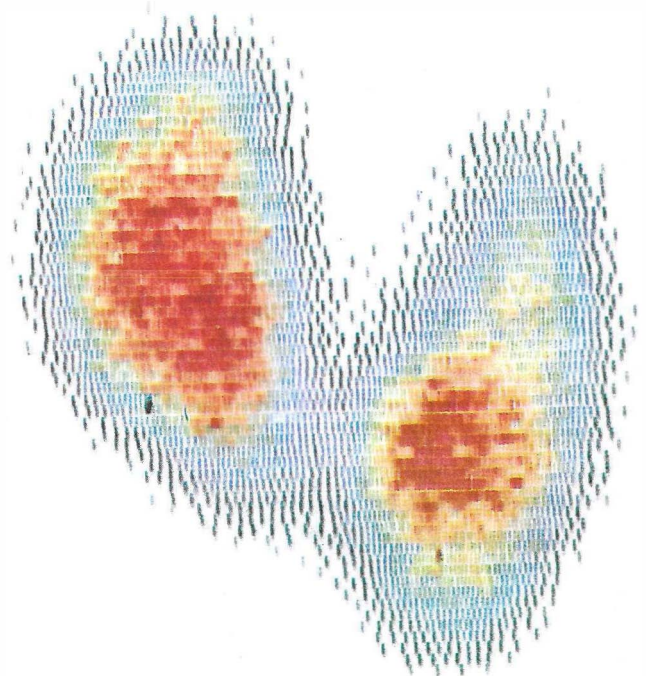


Fig 2. Thyroid Scan of patient one.



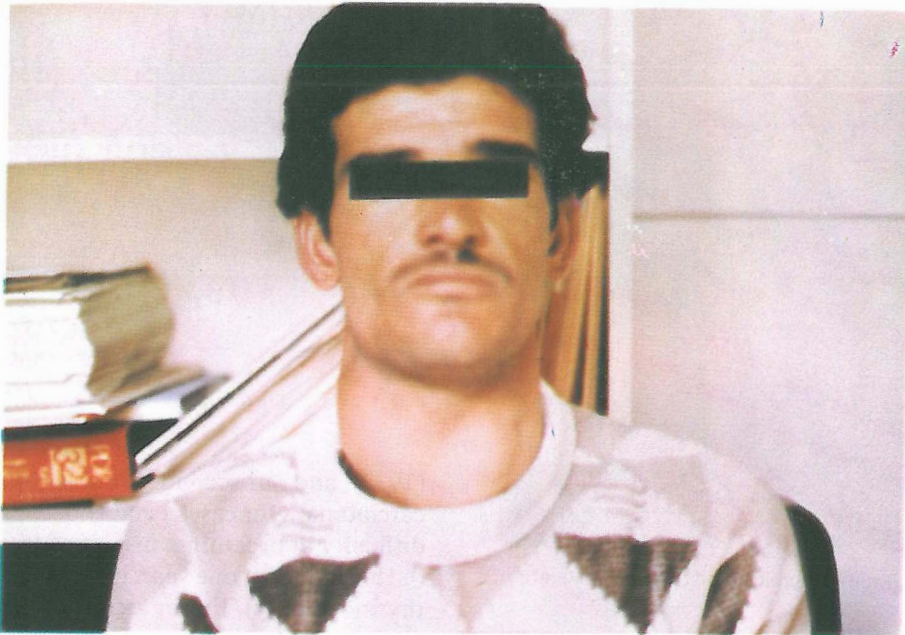


Fig 3. Large goiter of the second patient.

**CASE III:**

A 15 year old male was brought to the E.N.T. clinic for hearing loss since childhood. On E.N.T. examination, thyroid was of normal size (Fig.6). Eye examination for retinitis pigmentosa was negative, blood tests and urine analysis were normal. Fall in perchlorate test was 60%. The patient was treated with thyroid extract.

1,000,000 and in England,<sup>7</sup> 8/100,000.

Because the goiter develops slowly, the incidence in children is reported to be only 0.58/100,000.<sup>5</sup>

The disease is clearly inherited as an autosomal recessive, with some variability of expressivity of the gene. In the homozygote the hearing loss is sensorineural and usually static, but there have been observations

**DISCUSSION**

Pendred's syndrome is an autosomal recessive form of sensorineural deafness with goiter. It has been known for some centuries that there is a relationship between endemic goiter and deafness. In 1824 Wood<sup>2</sup> mentioned a relationship between sporadic goiter and deafness. However, as his description was not complete, the syndrome has been named after the English general practitioner Pendred<sup>3</sup> who in 1898, described two deaf-mute sisters with pronounced goiter. The diagnosis of this disease was further advanced in 1958 by Morgan and Trotter<sup>4</sup> by the use of the perchlorate test, which showed an abnormal organification of non-organic iodine. The disease is found throughout the world. In 1965, Fraser<sup>1</sup> was able to collect 233 cases from the literature, and at the same time defined Pendred's syndrome as a triad of congenital perceptible hearing loss, goiter, and pathological perchlorate test.

Thould<sup>5</sup> and Scowen in 1964 reported that Pendred's disease may account for 1 to 7 percent of severely to profoundly deaf children. The incidence, as stated in literature, varies considerably. In Sweden<sup>1</sup> it is 1/

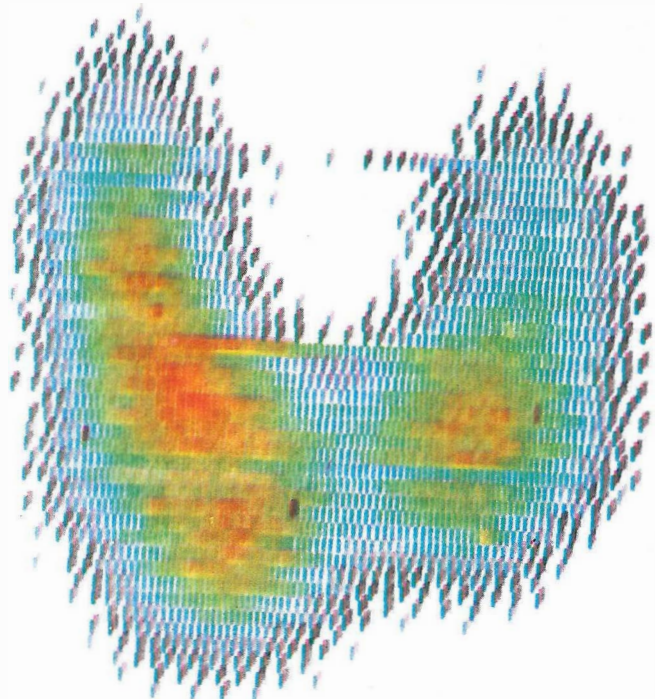


Fig 4. Thyroid scan of patient two.



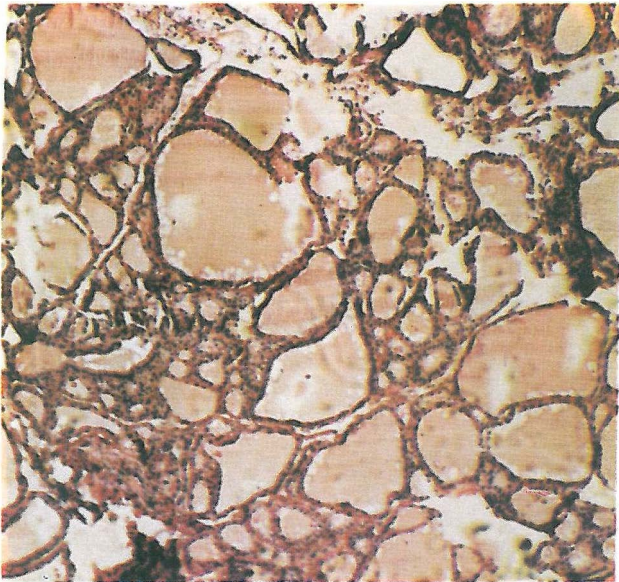


Fig 5. Photomicrograph of thyroid gland of second patient.

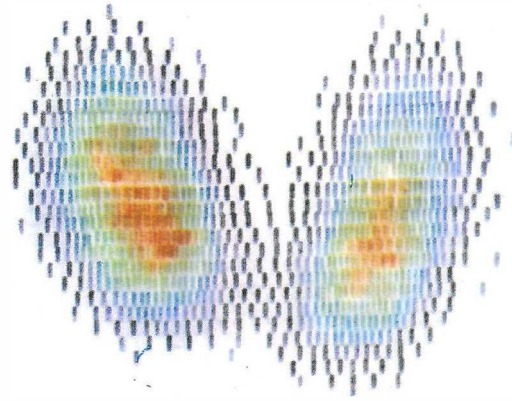


Fig 6. Thyroid scan of the third patient.

of possible progression.

The hearing loss is usually severe to profound, mainly affecting the hightones, but there may be some cases of unilateral hearing loss.<sup>10</sup> After reviewing the audiogram of 23 patients with Pendred's syndrome one had no response, 12 out of 23 were severely deaf, 8 of 23 were less severely deaf, and 2 of 23 had low levels of hearing loss. Vestibular responses were quite variable in these patients.

The first histologic description was reported by Hvidberg-Hansen and Jorgensen in 1968;<sup>8</sup> the findings were bilateral malformation of cochlea of Mondini type. In 1986 Torsten, Johnson and associates reported pathologic exams of six temporal bones from five patients with confirmed P.S. The characteristic Mondini cochlea<sup>9</sup> was found in all preparations. They concluded that the inner ear malformation in P.S. is more in accordance with Mondini's original description that in other syndromes in which a Mondini-like cochlea has been described. The most characteristic feature is that the basal turn is retained while the apical turn makes a large common cavity. Temporal bone histopathologic studies indicated that neuroepithelium of the cochlea of spiral ganglion cells was absent. The macula was normal with ossification of the endostium of the labyrinthine wall. Since the hearing loss is sensorineural type, patients can't get benefit out of any medications, except advise using hearing aid, in those patients who are deaf and mute. We are hoping cochlear implant to be useful for them in near future.

The goiter will usually be apparent before the age of 8 and in some instances may be found at birth.<sup>7</sup>

The patients are usually euthyroid.<sup>7</sup> It has been found that pathologic goiter in P.S. is not associated with cancer but case 7 of Peter Illum and associates

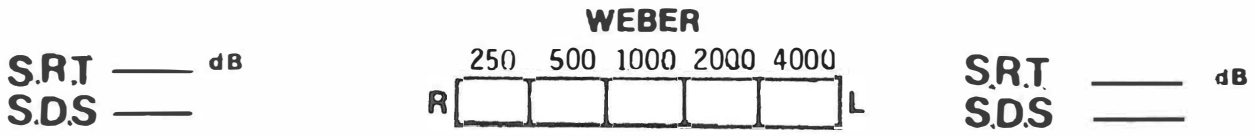
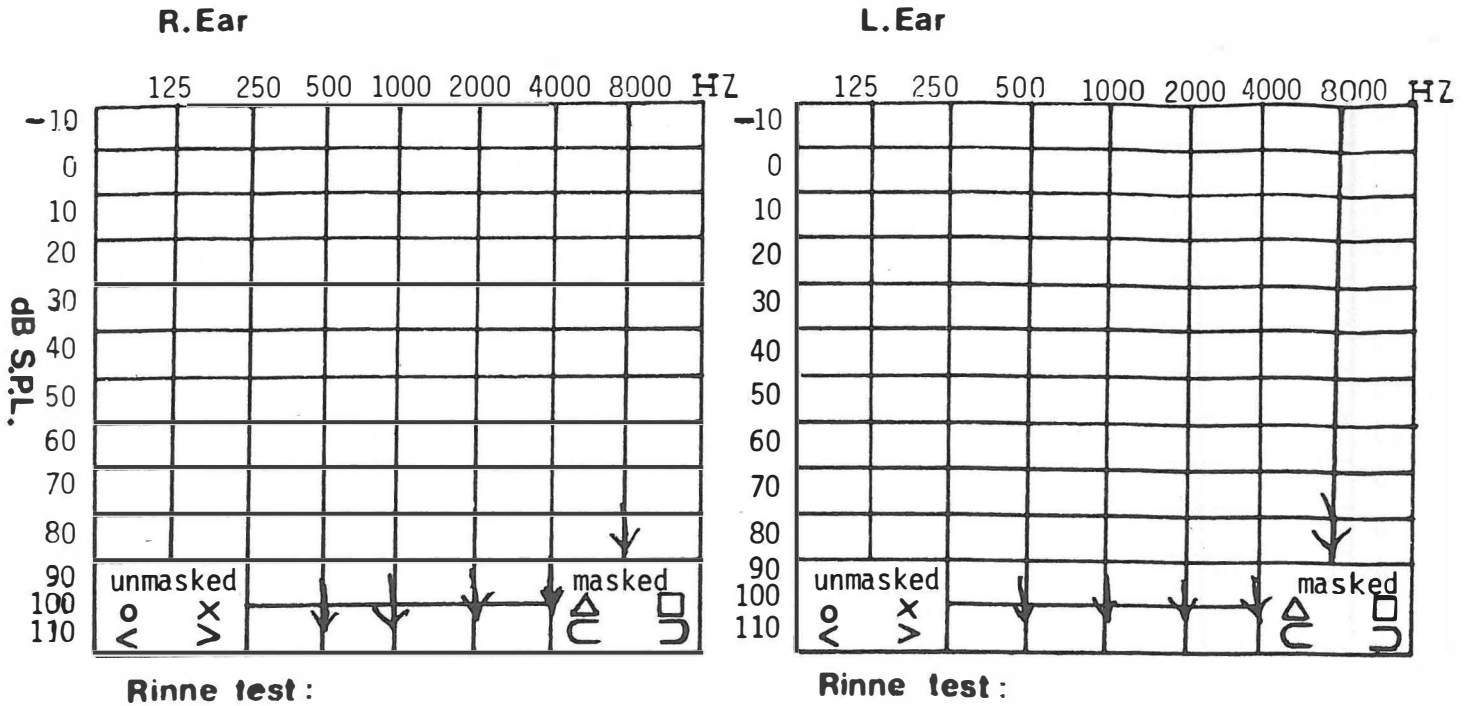
(1972), and our second case was reported as follicular carcinoma. Our cases I and II because of having some difficulty in breathing, inspite of treatment with thyroid hormone for one year, underwent surgery (subtotal thyroidectomy). Fraser feels that the frequency of the allele in this disease is approximately 0.008 and that the mutation rate may be 56/1,000,000 loci per gametes. It has also been noted<sup>1</sup> that heterozygotes may show a decrease in protein bound iodine. Statistically this decrease in P.B.I. is significant at the 2% level.

Initially, the goiter is diffuse and soft, but gradually it will develop a tendency to become nodular and hard, particularly in women, this is caused by the prolonged increased stimulation with thyroid stimulating hormone (TSH), which is a result of the relative insufficiency.

## REFERENCES

1. Fraser GR: Association of congenital deafness with goiter (Pendred's syndrome) *Ann Hum genet* 18: 207-249, 1965.
2. Wood K: Some observations upon local prevalence of iodine and its connections with goiter. *Men Manchr Lit Phil Soc* 4:88-103, 1824.
3. Pendred V: deaf-mutism and goiter. *Lancet* II:532, 1896.
4. Morgans ME, Trotter WR: Association of congenital deafness with goiter. *Lancet* I:607-609, 1958.
5. Thould AK, Scowen EF: The syndrome of congenital deafness and simple goiter. In: Pitt-Rivers R (ed): *Transactions of the Fourth International Goiter Conference*, London 1960, Oxford, England. Pergamon Press. p22, 1961.
6. Nilsson LR, Borgfors N, Gamstorp I, et al: Nonendemic goiter and deafness. *Acta Paediatr Scand* 53: 117-131, 1964.
7. Jensen J: Malformations on inner ear in deaf children. *Acta Radiol* 8:1-95, 1969.
8. Hvidberg-Hansen J, Jorgensen MB: The inner ear in Pendred's syndrome. *Acta Otolaryngol* 66:129-153, 1968.
9. Mondini C: Anatomia surdi nati sectio: De Bononiensi scientarium et artium instituto atque academia commentarii, Bononiae (opu scula), 7:419-431, 1791.
10. Torsten J, Jorgensen MB, Johnsen S: Mondini cochlea in Pendred's syndrome. A histological study. *Acta Otolaryngol (Stockh)* 102: 239-247, 1986.
11. Illum P, et al: Fifteen cases of Pendred's syndrome. *Arch Otolaryngol* 96: 294-304, 1972.

Pendred's Syndrome



**Reflexometry**

Test Tone Ear	Probe Tone Ear	Reflex Thresholds in dB HTL			
		500 Hz	1000 Hz	2000 Hz	4000 Hz
Right	Left	N.R.	N.R.	N.R.	N.R.
Left	Right	N.R.	N.R.	N.R.	N.R.

Test Tone Ear	Probe Tone Ear	Reflex Thresholds in dB HTL			
		500 Hz	1000 Hz	2000 Hz	4000 Hz
Right	Left				
Left	Right				

**Contralateral**

R | C<sub>s</sub> =  
L | C<sub>s</sub> =

**Ipsilateral**

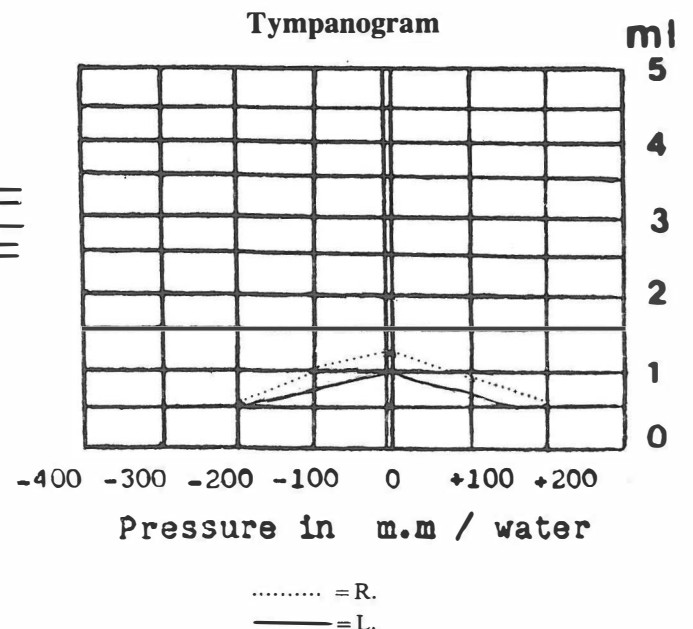
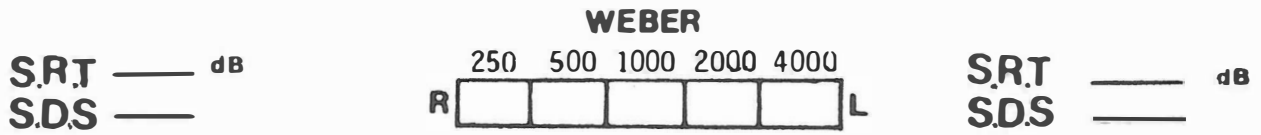
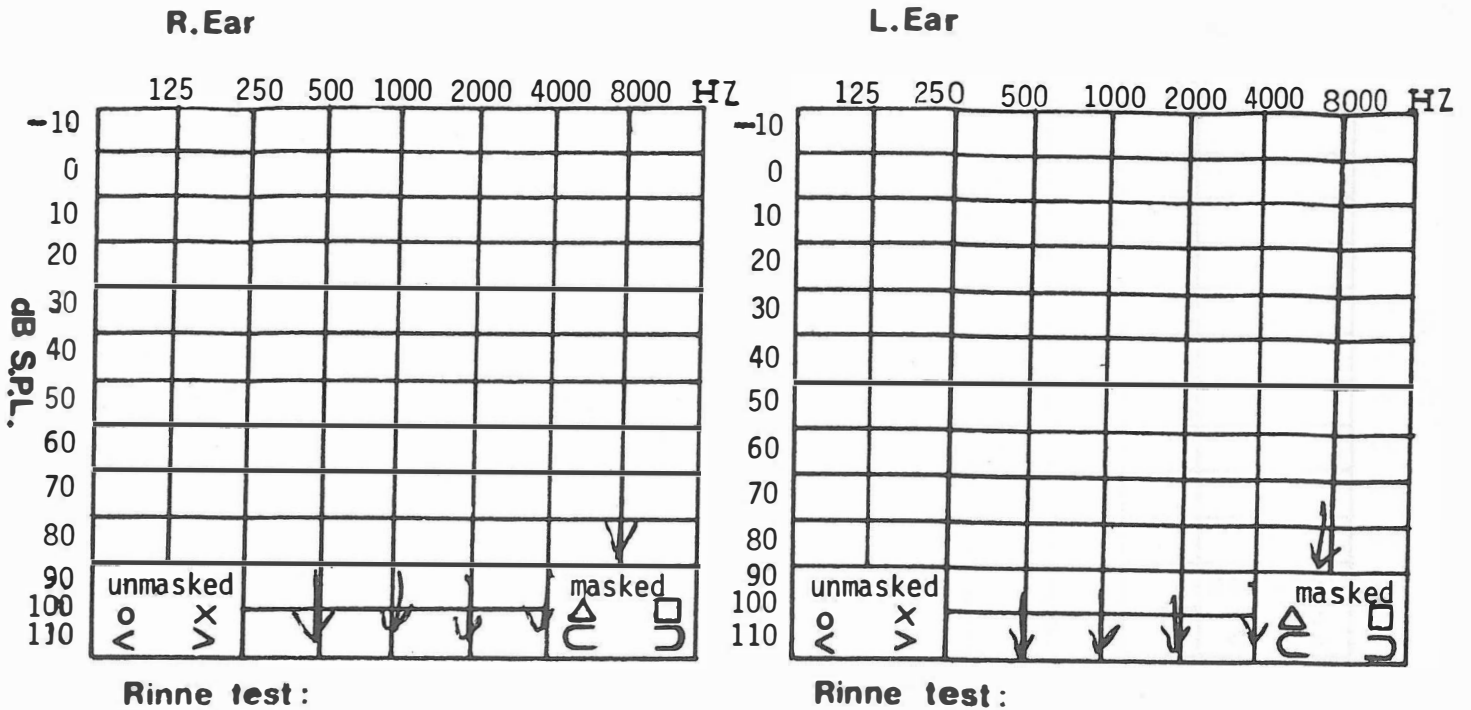


Fig.7. Audiological evaluation of case 1.



**Reflexometry**

Test Tone Ear	Probe Tone Ear	Reflex Thresholds in dB HTL			
		500 Hz	1000 Hz	2000 Hz	4000 Hz
Right	Left	N.R.	N.R.	N.R.	N.R.
Left	Right	N.R.	N.R.	N.R.	N.R.

Test Tone Ear	Probe Tone Ear	Reflex Thresholds in dB HTL			
		500 Hz	1000 Hz	2000 Hz	4000 Hz
Right	Left				
Left	Right				

Contralateral

R | C<sub>s</sub> =  
L | C<sub>s</sub> =

Ipsilateral

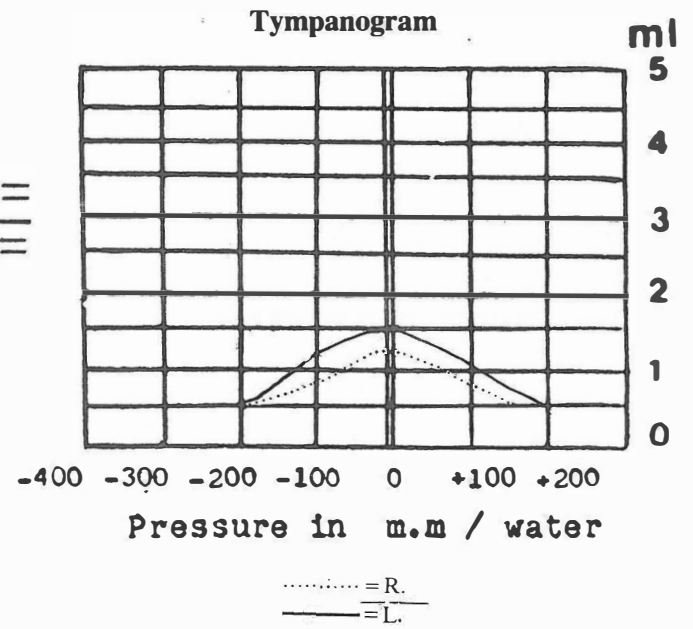
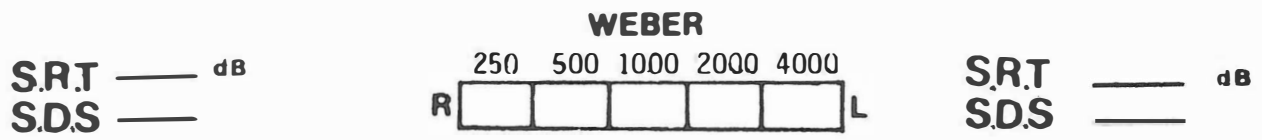
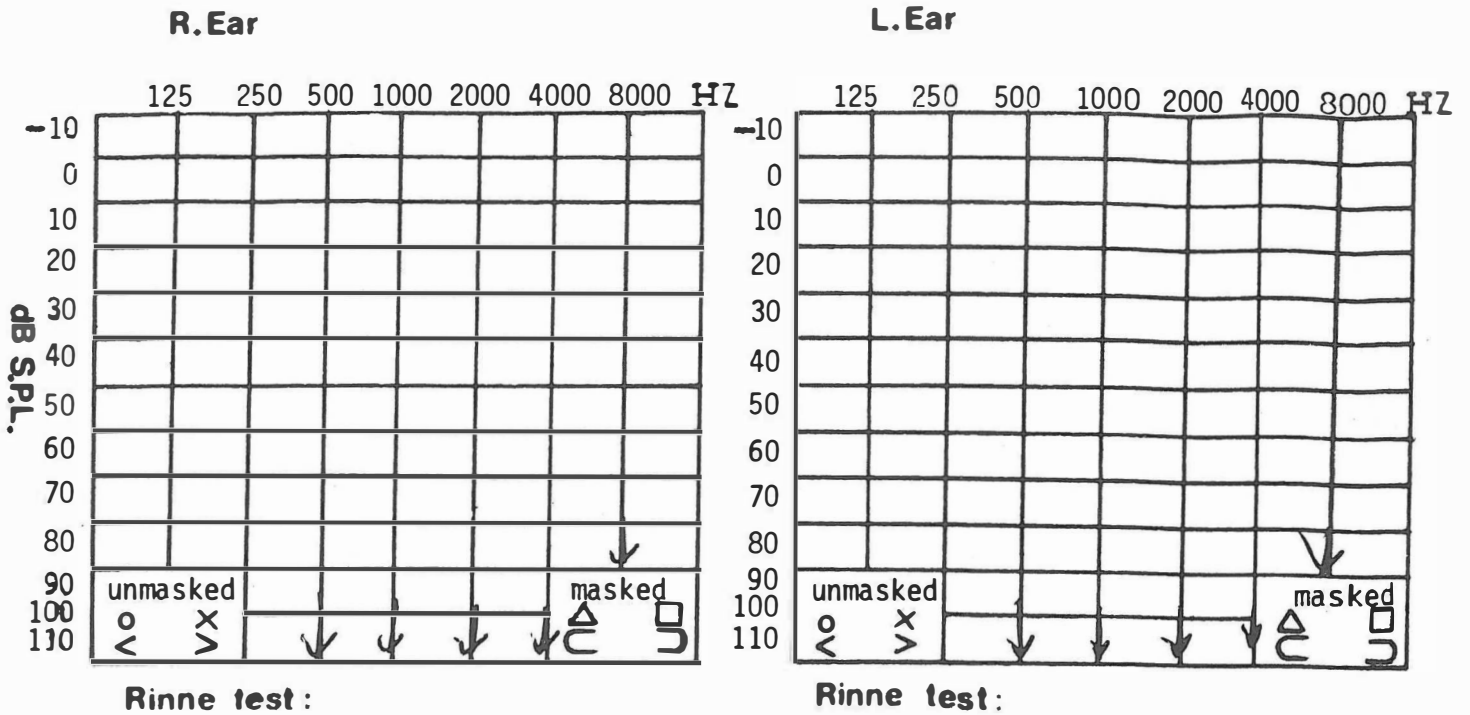


Fig.8. Audiological evaluation of case 2.

Pendred's Syndrome



Reflexometry

Test Tone Ear	Probe Tone Ear	Reflex Thresholds in dB HTL			
		500 Hz	1000 Hz	2000 Hz	4000 Hz
Right	Left	N.R.	N.R.	N.R.	N.R.
Left	Right	N.R.	N.R.	N.R.	N.R.

Test Tone Ear	Probe Tone Ear	Reflex Thresholds in dB HTL			
		500 Hz	1000 Hz	2000 Hz	4000 Hz
Right	Left	[Handwritten curve]			
Left	Right	[Handwritten curve]			

Contralateral

R | C<sub>s</sub> =  
L | C<sub>s</sub> =

Ipsilateral

Tympanogram

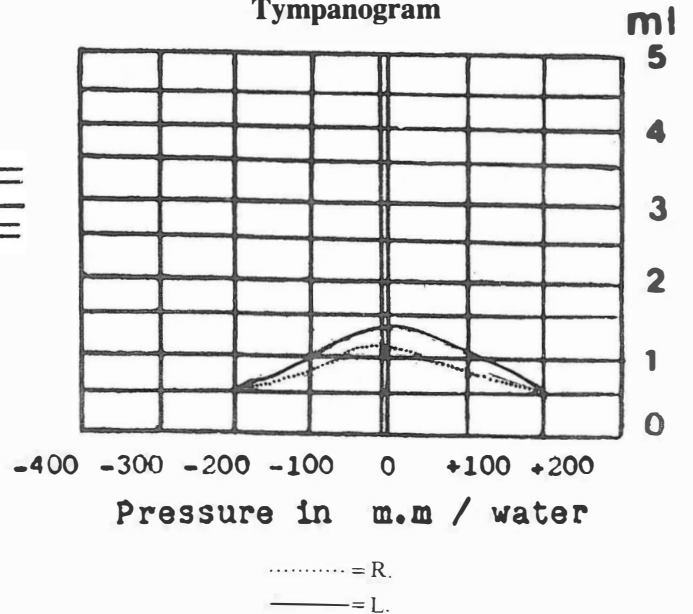


Fig.9. Audiological evaluation of case 3.

