

Osteoarticular allograft reconstruction of the distal radius after giant cell tumor resection

Khodamorad Jamshidi, MD,¹, Hamid Modaresnejad, MD.²

Department of Orthopedics, Shafa Yahyaiyan Hospital, Iran University of Medical Sciences, Tehran, Iran.

Abstract

Background: Resection of the distal end of the radius is indicated in the treatment of locally aggressive primary benign and malignant bone tumors. The aim of this study was to evaluate the technique of osteoarticular allograft reconstruction of the distal radius after wide excision of a giant-cell tumor.

Methods: We analyzed 15 patients retrospectively who had reconstruction of the distal aspect of the radius with use of an osteoarticular allograft, between 1981 and 2005 after excision of a giant-cell tumor with a minimum follow-up of 2 years (range: 26–125 months, median: 45 months).

Results: 15 consecutive patients with a Campanacci grade 3 giant-cell tumor of the distal radius formed the study population. Three patients had a local recurrence at 8, 14 and 18 months. Non-union of the osteotomy line was diagnosed 6 months after surgery in one case and needed bone grafting. Distal radio-ulnar joint instability was observed in nine cases. Subchondral bone alterations and joint narrowing were present in all cases but were painful in only one patient. Five patients needed a revision of the osteoarticular allograft, at an average of 5.4 years (range: 0.8 to 12 years) after the initial reconstruction. The reason for the revision was a fracture of the allograft in four patients and recurrence of the tumor in one. Of the fifteen patients in whom the osteoarticular allograft survived, five patients reported no functional limitation, eight had limitation in the ability to perform strenuous activities, and two had limitation in the ability to perform moderate activities. The average range of motion of the wrist was 35 degrees of dorsiflexion, 30 degrees of volar flexion, 10 degrees of radial deviation, 14 degrees of ulnar deviation, 55 degrees of supination, and 70 degrees of pronation.

Conclusion: Reconstruction of the distal aspect of the radius with use of an osteoarticular allograft was associated with a low rate of recurrence of the tumor, a moderately high rate of revision, and little pain in association with common activities, good function, and a moderate range of motion.

Keywords: distal radius, giant-cell tumor, osteoarticular allograft.

Introduction

Giant cell tumor of bones is an unusual neoplasm that accounts for 4% of all primary tumors of bone. Usually, the age of patients' ranges from 20 to 55 years, and the peak age in-

cidence is in the third decade of life, with slight female predominance (1.2:1). It is a locally aggressive tumor which involves the ends of long bones in skeletally mature individuals in more than 80% of cases, and 75% of them occur around the knee joint. The tumor usually involves the metaphysis and the epiphysis, but is

1. Corresponding author, Associate Professor of Orthopedics, Iran University of Medical Sciences. Shafa Yahyaiyan Hospital, Tehran, Iran. Tel: +98 021 88501208, e-mail: jamshidi_k@yahoo.com

2. Orthoped.

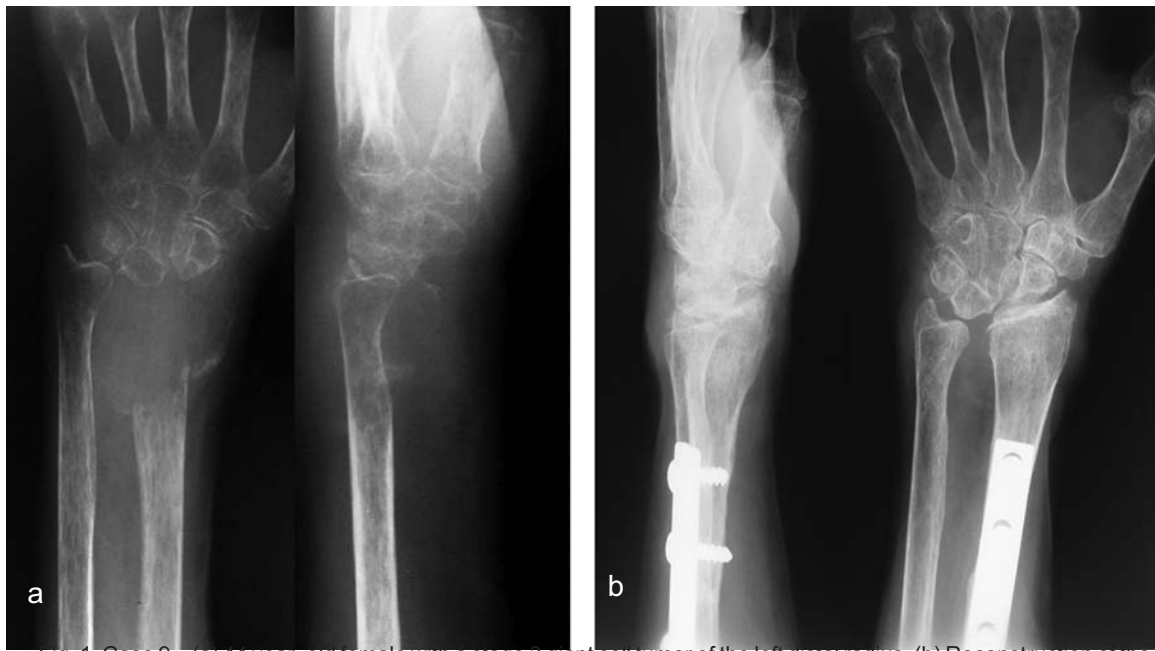

Fig. 1. Case 9 – (a) 44 year-old female with a stage 3 giant cell tumor of the left distal radius. (b) Reconstruction of the resected segment with an osteoarticular allograft, fixed with a dorsal plate.

occasionally limited to the metaphysis, and in only 2 per cent of the patients is it adjacent to an open growth plate. The tumor on occasion invades the articular space, also involving the ligaments and the synovial membrane. Extension to an adjacent bone through the joint occurs in 5 per cent of the tumors. Less frequently, giant cell tumors occur in the vertebrae (2-5%) and in the sacrum (10%) [1].

The distal aspect of the radius is a relatively common site of skeletal neoplasm and is the third most common location (after the distal aspect of the femur and the proximal aspect of the tibia) of giant-cell tumors. Giant-cell tumors of the distal aspect of the radius can exhibit extraosseous extension at the time of initial presentation, and there may be high rates of local recurrence after intralesional procedures. Giant cell tumor of bone remains a difficult and challenging management problem because there are no absolute clinical, radiographic, or histologic parameters that accurately predict the tendency of any single lesion to recur or metastasize [2].

Enneking's and Campanacci's radiographic classifications and surgical staging are helpful

in planning the initial surgical treatment, because they have observed that a number of the active (Stage 2) lesions and most of the aggressive (Stage 3) lesions have a higher incidence of local recurrence when treated by curettage alone [3](Fig. 1a).

Resection of the distal aspect of the radius may be indicated for certain malignant lesions and for recurrent or locally invasive benign lesions. Giant-cell tumors of the distal aspect of the radius can exhibit extraosseous extension at the time of initial presentation, and there may be high rates of local recurrence after intralesional procedures [4]. Reconstruction of the wrist after excision of the distal aspect of the radius is a challenge because of the high functional demands on the hand, the young age and relatively long life expectancy of many patients who have a giant-cell tumor, the limited surrounding soft tissue, and the proximity of adjacent nerves and tendons. Various procedures, including resection arthroplasty, prosthetic replacement, and arthrodesis with use of a massive autogenous graft from the tibia or the iliac crest, ulnar translocation, centralization of the

Patient	Gender	Age (Years)	FW-UP (Months)	Length of resection (cm)	Affected side (L/R)	ROM (Flex/Ext)	Function (%)	Recurrence (Months)
1	M	39	125	6	R	60/35	90	-----
2	F	44	122	6	R	65/45	91	8
3	M	60	54	7	L	45/25	94	-----
4	M	36	48	8	L	60/35	90	-----
5	M	50	37	6	R	70/60	95	-----
6	M	40	31	16	R	60/40	91	-----
7	M	65	27	9	R	50/35	90	-----
8	F	27	32	8	R	55/40	92	18
9	F	40	41	6	L	65/55	90	-----
10	F	45	38	8	L	30/20	85	-----
11	F	32	28	7	L	45/25	87	-----
12	M	34	30	6	L	60/30	90	14
13	F	20	50	6	L	70/45	95	-----
14	F	40	50	9	L	70/65	90	-----
15	F	35	60	7	R	60/35	90	-----

Table 1. Patients' demographics.

carpus over the remaining ulna, use of a non-vascularized or vascularized fibular graft with or without arthrodesis, and allograft replacement, have been used for reconstruction [5,6]. The use of an osteoarticular allograft allows more accurate size matching than a fibular graft, which also results in more donor site morbidity. Fibular harvesting is another reason to prefer the allograft technique. Moreover, the use of an allograft requires a shorter operation time and a stable radio-carpal joint with a better functional outcome [7]. Free vascularized fibular graft reconstruction should be reserved for children, in whom a biological reconstruction simultaneously replaces the bone defect and prevents a future upper-extremity length discrepancy [8, 9,10]. Joint degenerative changes, subchondral fractures and instability are well-documented problems of osteoarticular allograft, especially in weight-bearing joint reconstructions, such as distal femur. However, graft failures are also reported in upper limb reconstructions [11]. The aim of this study was to assess the clinical, radiographical and overall functional results of a group of 15 patients treated with osteoarticular allografting of the distal radius after excision of a giant-cell tumor with a long follow-up.

Methods

From September 1981 to August 2005, 20 pa-

tients underwent a distal radius resection and reconstruction with an osteoarticular allograft after excision of a giant-cell tumor at our hospital. We analyzed 15 patients retrospectively who had a minimum follow-up of 2 years (range: 27–125 months, median: 45 months) (Table 1). There were seven males and eight females, whose age ranged from 20 to 65 years (mean 40 years).

All fifteen patients were evaluated preoperatively with appropriate studies, including radiography, bone-scanning, and magnetic resonance imaging. All patients who had a primary lesion had a needle or incisional biopsy for diagnosis before the reconstruction. Patients were considered candidates for the reconstruction if they had a primary giant cell tumor that had extended through the cortex or articular surface of the distal aspect of the radius or a recurrent giant cell tumor that was invasive. Ten patients due to recurrent giant cell tumor were candidates for the reconstruction and only five of them were operated for the first time.

The osteoarticular distal radial allografts were fresh frozen and obtained from our hospital bone bank. The organization, screening measures, technology of procurement, cryopreservation, handling, and storage methods of this tissue bank have been described previously and are in accordance with the guidelines of the

Shafa Yahyaian Hospital Tissue Bank [12]. Soft-tissue tendinous insertions and ligaments were retained on the allograft. An appropriate allograft was chosen for reconstruction with use of radiographic size matching. At the time of the reconstruction, the graft was thawed in 37-degree Ringer's lactate and antibiotic solution.

The reconstruction was performed through a dorsal approach to the wrist, with wide or marginal resection of the tumor by one surgeon. The allograft was stabilized with internal fixation, usually a dorsoradial 4.5-millimeter dynamic-compression plate (Fig. 1b). The palmar ligaments of the wrist and the triangular fibrocartilage complex were sutured to the corresponding ligaments of the allograft. The wrist joint was fixed with Kirschner wires, which were removed after three to four weeks. The limb was immobilized in an above-the-elbow cast or splint for six to eight weeks and then motion of the wrist was started gradually.

All patients were followed for at least two years (range: 26-25 months, median: 45 months). The patients were assessed clinically and radiographically for recurrence of the tumor, fracture, non-union, infection, and other complications. They also were assessed for pain, the ability to perform specific activities, work restrictions, and range of motion. Clinical outcome evaluated wrist motion (flexion and extension) and deformity. Pain, functional activity and emotional acceptance were assessed according to the MSTTS scoring system [13].

Results

The average age of the fifteen patients was 40 years (range: 20-65 years). Eight patients were female and seven were male. Seven lesions involved the right wrist and eight involved the left wrist. Ten patients were initially seen because of pain in the wrist or the distal aspect of the radius; one, because of a pathological fracture; four, because of a mass in the wrist. Five giant-cell tumors were primary lesions and ten were

recurrent. None of the patients had metastatic disease, as seen on bone scans and radiographs of the chest. All of the primary lesions were locally invasive and had extended through the distal radial cortex or subchondral bone. Of the patients who had a recurrent lesion, three had previous intralesional curettage with use of methylmethacrylate and seven, with bone grafting.

Three patients had a local recurrence of the tumor after the reconstruction. In one of these patients, who had had a primary giant-cell tumor, the lesion recurred 18 months after the reconstruction in the soft tissue and the small recurrence was excised without functional consequences. In two others, who had reconstruction due to recurrence of the tumor, the lesions recurred after eight and fourteen months. In one of these patients, the reconstruction was converted into a wrist arthrodesis because of extensive radiocarpal joint involvement. Five patients needed a revision of the osteoarticular allograft. The reason for the revision included fracture in four patients (Fig. 2) and recurrence of the tumor in one. Primary fusion of the graft was achieved in 14 patients. The average time of union was 3.5 months (range: 2.5-6 months). Non-union of the osteotomy line in one patient was diagnosed 6 months after surgery and needed a bone graft, which achieved an excellent fusion after a few months.

Of the fifteen patients who had a surviving osteoarticular allograft, two patients were limited in their ability to perform moderate activities, eight were limited in their ability to perform strenuous activities, and five had no limitation. The average range of motion of the wrist (and standard deviation) was 35 ± 14.5 degrees (range: 15-70 degrees) of dorsiflexion, 19 ± 14 degrees (range: -5-55 degrees) of volar flexion, 15 ± 15 degrees (range: 5-30 degrees) of radial deviation, 14 ± 7 degrees (range: 5-35 degrees) of ulnar deviation, 60 ± 21 degrees (range: 15-90 degrees) of supination, and 70 ± 16.0 degrees (range: 45-90 degrees) of pronation.

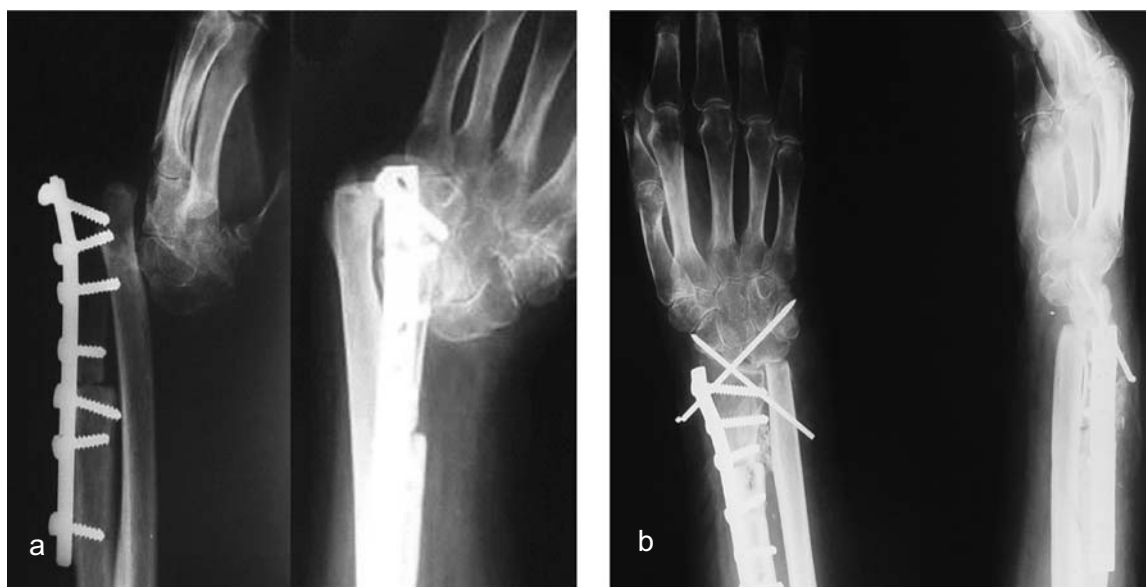

Fig. 2. Case7- 65-year-old male with a stage 3 giant cell tumor of the right distal radius, (a) allograft fracture and joint dislocation. (b) Exchanging the osteoarticular allograft and wrist fixation with pins.

Radiographs showed narrowing of the joint space in all patients, ulnocarpal impaction in thirteen, carpal subluxation in six, formation of osteophytes and subchondral sclerosis in eight, and widening of the distal radioulnar joint in nine.

Discussion

The distal radius is an uncommon site for benign tumors but it is the third most common site of occurrence of giant cell tumors [1,2]. Cortical breakthrough or pathologic fracture is often present with extra compartmental tumor extension. In these cases, curettage of the lesion is not feasible because of the lack of residual bone stock and radio–carpal joint disruption. Furthermore, a high incidence of recurrences is reported. Therefore, resection is the treatment of choice in these cases [4,6,14]. The oncological goal is the prevention of local recurrence with adequate resection. Thus, when the architecture of the distal aspect of the radius has been preserved, intralesional curettage is the procedure of choice for primary benign lesions, and many believe that recurrent benign lesions should be treated with repeat curettage. However, when a

lesion is malignant or an extra-compartmental benign lesion extends through the radial cortex or subchondral bone and the residual bone stock is poor, reconstruction of the distal aspect of the radius with use of an osteoarticular allograft permits wide or marginal resection and a lower rate of local recurrence [15].

Recurrence rates of giant cell tumors are higher in the distal radius than at other long-bone sites. This is probably due to the anatomical structure of the distal radius [2, 4]. The rate of local recurrence in the current series was low (only three of fifteen patients), but it is four times more than Mankin's or Bianchi's study. The reason may be that the rate of recurrent patients in our study who became candidates for reconstruction comprised 70% of the study population and patients who had had a primary giant-cell tumor comprised only 30% of our cases. The overall rate of recurrence of giant-cell tumors was 20 per cent (three of fifteen). This rate is considerably lower than that reported after intralesional procedures involving the distal aspect of the radius. Similarly, Sheth et al. found no local recurrence in ten patients in whom a giant-cell tumor of the distal aspect of

the radius had been excised en bloc compared with five recurrences in eighteen patients in whom a similar lesion had been treated with intralesional curettage and cryosurgery. Bianchi used three different approaches, depending on tumor expansion, and found that a lateral or volar approach offers the best exposure in terms of ease of management of the neurovascular bundle, the distal radius and the radio–carpal and radio–ulnar joints [7,16,17,18]. In addition, most of the soft tissue component of tumors was in the volar side in our series (Fig. 3). We performed resection and reconstruction only through a dorsal approach. After osteotomy and elevation of the proximal segment, the soft tissue component was excised without any problem.

Kocher et al reported a high complication rate following osteoarticular allograft reconstruction of the distal radius. Complications included non-union and delayed union, fracture of the graft, subluxation of the wrist, and donor-site morbidity. Kocher et al reported seven grafts out of 24 were converted into an arthrodesis because of four graft fractures, two problems of persistent pain and one case of volar dislocation [19]. In our series, graft fracture occurred in four cases (26.6%). This is similar to Mankin's study. The fracture occurred in all of the cases in the metaphyseal area at least six months after reconstruction. These fractures happened with low energy trauma. Mild dorsal ulnar subluxation is quite frequent and occurred in 62% of our cases, but we consider it only a minor cosmetic problem. It did not influence wrist motion and pain and with careful reconstruction of capsule and ligaments this problem can be avoided. Articular degenerative changes of cartilage and subchondral bone occurred in all of our patients, predominantly on the radial side, just like Donati's study.

There is no doubt that a painless, stable and functional osteoarticular graft of the wrist is preferable to an arthrodesis. A matched radial allograft corresponds better to the geometry of

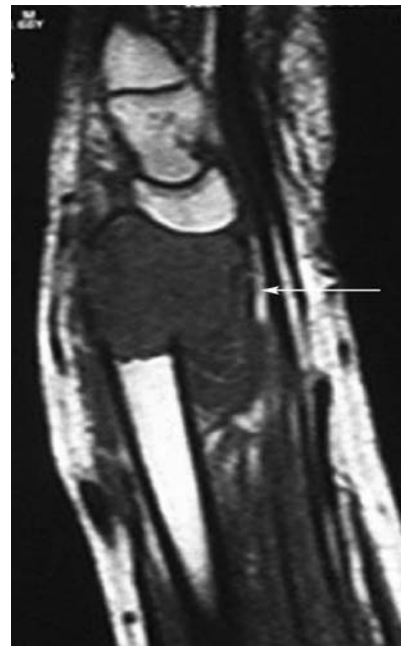


Fig. 3. Case9 - MRI of distal radius: Note the soft tissue component in the volar side

the resected segment than any other graft and should result in a better functional outcome [19, 20]. Flexion and extension of the patients in our series is better than previously reported by Maruthainar et al. following reconstruction with an autologous fibular graft [21] and similar to Bianchi's study [7]. Enough metaphyseal and subchondral bone must remain after curettage to permit packing with cement. The use of cement as a packing material is difficult when less than 50 per cent of the circumference of the bone remains or when there is large or multiple defects in the cortical or subchondral bone [2]. Funderburk's study suggests that the risk of local tumor recurrence after curettage and reconstruction with autogenous bone graft or cement is similar [5]. The local recurrence rate after wide resection and osteoarticular allograft reconstruction in our study was about 20% that was two times less than Funderburk's study but there was no difference in functional outcome.

Reconstruction of the distal aspect of the radius with use of an osteoarticular allograft was associated with a low rate of recurrence of the

giant cell tumor, a moderately high rate of revision, and little pain in association with common activities, good function, and a moderate range of motion. Mechanical failure of the reconstruction is rare. Painless degenerative changes occur in all of these grafts but range of motion is usually well preserved. Osteoarticular allografts are an option for reconstruction of the distal aspect of the radius after excision of giant cell tumors.

References

1. Briggs TWR, Cobb J, McAuliffe T, Pringle J, Kemp H. Giant cell tumors of bone. *The Journal of Bone and Joint Surgery* 1990; 72B: 937.
2. Harness NG, Mankin HJ. Giant-cell tumor of the distal forearm. *The Journal of Hand Surgery* 2004; 29A: 188–193.
3. Enneking WF. A system of staging musculoskeletal neoplasms. *Clinical Orthopedics and Related Research* 1986; 204: 9–24.
4. Sheth DS, Healey JH, Sobel M, Lane JM, Marcove RC. Giant cell tumor of the distal radius. *The Journal of Hand Surgery* 1995; 20A: 432–440.
5. Vander Griend RA, Funderburk CH. The treatment of giant-cell tumors of the distal part of the radius. *The Journal of Bone and Joint Surgery* 1993; 75-A: 899-908.
6. Cheng CY, Shih HN, Hsu KY, Hsu RWW. Treatment of giant cell tumor of the distal radius. *Clinical Orthopedics and Related Research* 2000; 383: 221–228.
7. Bianchi G, Donati D, Staals EL, Mecuri M. Osteoarticular allograft reconstruction of the distal radius after bone tumor resection. *J Hand Surg Br* 2005; 30:369-373.
8. Innocenti M, Delcroix L, Manfrini M, Ceruso M, Capanna R. Vascularized proximal fibular epiphyseal transfer for distal radial reconstruction. *The Journal of Bone and Joint Surgery* 2004; 86A: 1504–1511.
9. Vail TP, Urbaniak JR. Donor-site morbidity with use of vascularized autogenous fibular grafts. *The Journal of Bone and Joint Surgery* 1996; 78A: 204–211.
10. Aithal VK, Bhaskaranand K. Reconstruction of the distal radius by fibula following excision of giant cell tumor. *International Orthopedics* 2003; 27: 110–113.
11. Lewis MM. Bone tumor surgery. Limb sparing techniques. Philadelphia: JB Lippincott; 1988. P. 255–259.
12. Jamshidi KM, Jabalameli M, Ameri E. The early results of massive osteoarticular allograft in the surgical treatment of lower limb bone tumors. *The Journal of Kerman University of Medical Sciences* 1998; 5(3):117-122.
13. Enneking WF, Dunham W, Gebhardt MC, Malawar M, Pritchard DJ. A system for the functional evaluation of reconstructive procedures after surgical treatment of tumors of the musculoskeletal system. *Clinical Orthopedics and Related Research* 1993; 286: 241–246.
14. Campanacci M, Laus M, Boriani S. Resection of the distal end of the radius. *Italian Journal of Orthopedics and Traumatology* 1979; 5: 145.
15. Donati D, Bini SA, Bacci G, Campanacci M. Follow-up protocols in orthopedic oncology. *Tumori* 1998; 84: 57–59.
16. Tsai TM, Stilwell JH. Repair of chronic subluxation of the distal radioulnar joint (ulnar dorsal) using flexor carpi ulnaris tendon. *Journal of Hand Surgery* 1984; 9B: 289–294.
17. Senechaud C, Savioz D, Della Santa D. Stabilization of the distal radioulnar joint by Hui-Lindscheid ligamentoplasty. Report of 10 cases. *Annals of Hand and Upper Limb Surgery* 1996; 15: 70–79.
18. Holtslag HR, van der Hoeven H, Alting MP. Instability of the distal radio – ulnar joint: stabilization by a Gore-Tex ligament. *Plastic Reconstructive Surgery* 1999; 104: 699–704.
19. Kocher MS, Gebhardt MC, Mankin HJ. Reconstruction of the distal aspect of the radius with use of an osteoarticular allograft after excision of a skeletal tumor. *The Journal of Bone and Joint Surgery* 1998; 80A: 407–419.
20. Delloye C, De Nayer P, Vincent A. Osteochondral allografts in arm and forearm surgery. *Acta Orthop Belgica* 1991; 57 (Suppl. 2): 75–83.
21. Maruthainar N, Zambakidis C, Harper G, Calder D, Cannon SR, Briggs TWR. Functional outcome following excision of tumours of the distal radius and reconstruction by autologous nonvascularized osteoarticular fibula grafting. *The Journal of Hand Surgery* 2002; 27B: 2: 171–174.