

A rare ovarian tumor, leydig stromal cell tumor, presenting with virilization: a case report

Soheila Aminimoghaddam¹, Atefeh-Sadat Ebrahimi², Forough Hashemi³

Department of gynecology, Firoozgar Hospital, Tehran University of Medical Sciences, Tehran, Iran.

Received: 4 March 2012

Revised: 25 August 2012

Accepted: 10 September 2012

Abstract

Leydig stromal cell tumor is a rare ovarian tumor that belongs to the group of sex-cord stromal tumors. They produce testosterone leading to hyperandrogenism. We present a 41yr old woman with symptoms of virilization and a mass of right adnexa via ultra Sonography, and a rise of total and free serum testosterone. An ovarian source of androgen was suspected and a surgery performed. A diagnosis of leydig-stromal cell tumor was confirmed.

Our report is a reminder that although idiopathic hirsutism and other benign androgen excess disorder like Polycystic Ovarian Syndrome (PCOs) are common, ovarian mass should be considered in differential diagnosis.

Keywords: Leydig stromal cell tumor, Androgen secreting neoplasm, Virilizing ovarian tumors, Sex cord-stromal cell tumor.

Introduction

Sex cord-stromal tumors of ovary account for approximately 5-8% of all ovarian tumors (1-5). They are composed of granulosa cells, theca cells, sertoli cells, leydig cells and fibroblasts singly or in various combinations (2,6).

Leydig stromal tumor is a rare member of this group that accounts for less than 0.1% of all ovarian tumors (7,8). They are usually benign, unilateral (2, 6-10) and characterized by the presence of crystals of reinke in the steroid cells (8,9,11).

They are functional tumors and one of the

ovarian virilizing tumors. They produce testosterone, leading to hyperandrogenism and virilization (hirsutism, voice deepening, clitoromegaly, increased muscle mass, et al) in woman who are mostly postmenopausal (7,8,11).

Here we report a 41-years old woman with virilization and an ovarian leydig stromal cell tumor.

Case report

A 41-year-old woman with a 5-year history of amenorrhoea was admitted to our hospital because of relapsing vaginal bleeding, hirsutism, acne, some skin lesion especially

1. Gynecologist-Oncologist, Assistant Professor of Medicine, Department of gynecology, Firoozgar Hospital, Tehran University of Medical Sciences, Tehran, Iran. dr.aminimoghaddam@yahoo.com

2. (Corresponding author), MD, Resident of gynecology, Department of gynecology, Firoozgar Hospital, Tehran University of Medical Sciences, Tehran, Iran. md.a_ebrahimi@yahoo.com.sg

3. MD, clinical and anatomical pathologist, Assistant Professor of Medicine, Department of pathology, Firoozgar Hospital, Tehran University of Medical Sciences, Tehran, Iran. fhashemi54@yahoo.com

on her abdomen, deepening of the voice and feeling of pressure in the pelvic for past 6 months. She first had gone to a dermatologist office with an excessive hair growth on the body and acne. Because of an abnormality in her serum androgen and a pelvic mass in the ultrasonography, physician referred her to a gynecologist.

High levels of circulating total testosterone and free testosterone were found. Both FSH and LH were below 0.5 (Iu/L). Adrenocorticotropin hormone (ACTH), dehydroepiandrostone sulfate (DHEAS), thyroid function test and urine free cortisol level with a volume of 1300ml were normal. CEA and CA125 biomarkers were also normal.

Ultra sound revealed a uterus with 12.5 x 3.8x7 cm in diameters with a myomatosis pattern and an endometrial length of 7mm. A heterogenous mass of about 62x65mm with multiple calcification areas was seen in right adenex, so an ovarian mass or pedunculated myoma was suggested. On her transvaginal examination, right adenex fullness with a uterus larger than normal size in a postmenopausal woman was detected.

She underwent an exploratory laparotomy, total hysterectomy, infracolic omentectomy, bilateral salpingo-oophorectomy and peritoneal washings.

In pathologic report, macroscopic finding includes an encapsulated creamy – gray solid mass with smooth and lobulated external surface, with areas of orange discoloration. In microscopy: ovarian stroma, leydig cells and spindle stromal cells without atypia were seen (Figs. 1,2).

A benign Leydig stromal cell tumor was reported with no omental or lymph node involvement and cytology of peritoneal washing was negative for malignant cell. Abdominal skin biopsy showed no significant pathologic change. At post operative follow-up, serum testosterone level decreased, and there was regression of the virilizing changes.

Discussion

Sex cord-stromal tumors are groups of tu-

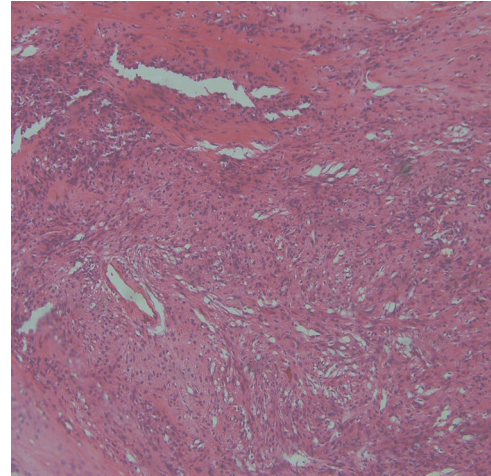


Fig 1. Ovarian stroma with leydig cells and spindle stromal cells (Hematoxylin Eosin staining)

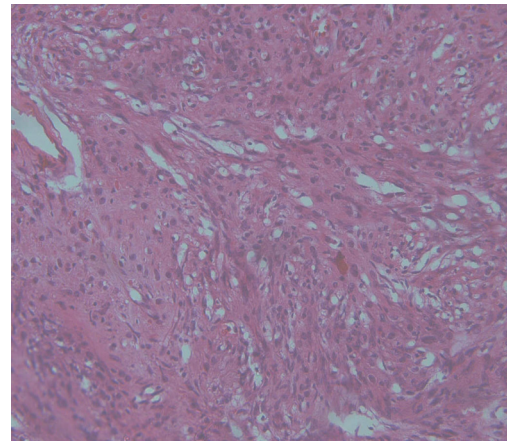


Fig 2. Polygonal and spindle cells of tumor with obvious vasculature (Hematoxylin Eosin staining)

mors composed of granulosa cells, theca cells, sertoli cells, leydig cells and fibroblasts of stromal origin, singly or in various combinations (2,6). They account for approximately 5-8% of all ovarian tumors and because they are rare tumors, there is a limitation in understanding their natural history, management, and prognosis (1-5). Women older than 50 years of age show the most incidence of ovarian sex cord-stromal tumors although a significant proportion occurs in premenopausal women (2). Leydig Stromal cell tumor is a rare case of these tumors that mostly occurs in a post menopausal women (2,7,8,11,12). In two reports with series of

cases, the average age of patients was 60 years (6) although the patient in this study was younger.

Ovarian tumors that induce virilization (like hirsutism, enlargements of clitoris, the voice deepening, etc) constitute less than 0.2% of hyperandrogenism. The time to onset of symptoms is usually faster in these tumors than the other causes of hyperandrogenism such as polycystic ovary syndrome (PCOS) (12), similar to our patient whose symptoms appear within months.

Leydig Stromal cell tumors account for less than 0.1% of all ovarian tumors (7,8,12). They are usually benign and unilateral (2,6-10,12). Evidence of virilization as a result of hyper androgenism, is seen in approximately one-half of the patients, and one-third have presented with estrogenic manifestation (6). About 30% of patients such as patient in this study may have endometrial hyperplasia and dysfunctional uterine bleeding (13). When abnormal vaginal bleeding is present or a thickened endometrial lining on ultrasound detected, endometrial biopsy must be done to exclude endometrial cancer prior to surgery (12). When the tumor is removed, the virilizing changes will regress but may not disappear. Aetiologies of the estrogenic changes include: estrogen secretion by the tumor, peripheral conversion of androgen, associated stromal hyperthecosis or a combination of these factors. All the cases reported until now, have been clinically benign. This tumor is distinguished from the sertoli-leydig cell tumor by the absence of a sex-cord component (follicular granulosa cells which are homologue of sertoli cells in the testis) (6).

This tumor is composed of nodules of leydig cells with a neoplastic stromal proliferation. The stromal component resembles the theca cell tumor, and the presence of crystals reinke in the steroid cell identifies them as leydig cells (6,11). Some ovarian leydig cell tumors arise in the hilus from hilar leydig cells which can be identified in over 80% of normal adult ovaries. Other leydig cells tumors that are located within

the ovarian stroma are referred to as non hilar leydig cell tumors, and the term leydig cell not otherwise specified is used when it is impossible to be certain about the origin (6,9).

The main treatment of the sex cord –stromal ovarian tumors is surgery (2). Unfortunately clinical presentation and sonographic appearance cannot predict which mass is malignant (12). These tumors often are just diagnosed via surgery, and a correct frozen–section diagnosis seems to be difficult. More than 90% of these neoplasms are unilateral and confined to the ovary. A conservative surgery with unilateral salpingo-oophorectomy and a careful staging are justified reasonable for patients who want to preserve their fertility with the absence of extraovarian spread. If advanced-stage disease or bilateral ovarian involvement is present or the patient does not want to preserve her reproductive potential, abdominal hysterectomy and bilateral salpingo-oophorectomy should be performed. In addition a surgical staging is necessary. This includes a thorough exploration of the abdominal cavity, washing for cytologic analysis, multiple biopsies, omentectomy, and pelvic and para-aortic lymph node sampling or dissection (2). In some cases, androgen secreting tumors response to gonadotropin releasing hormone agonist, therefore in patients who surgery is not straightforward such as high surgical risk, this treatment can be used (12,13).

Conclusion

Although polycystic ovary syndrome (PCOS) and non-malignant androgen excess disorders are common causes of hyperandrogenism, other aetiologies such as ovarian tumors should be considered. A complete evaluation should be done in a woman with skin disorder (such as hirsutism and acne) that can be related to hyperandrogenism.

References

1. Berek JS, Natarajan S. Ovarian and fallopian tube cancer. In: Berek & Novak's Gynecology. 14th ed. 2007; pp. 1458-1547.

2. Colombo Ni, Parma Ga. Ovarian sex cord-stromal tumors. In: Gershenson DM, Mcguire Mc, Gore M, Quinn M A, Thomas G, editors. *Gynecologic Cancer*. 2nd ed. United statesof America: Elsevier; 2005; pp 503-507.
3. Johns Hopkins pathology. Ovarian cancer diagnosis type of tumors. Johns Hopkins pathology; 2001. Available from: <http://ovariancancer.jhmi.edu/stromal.cfm>
4. Esheba GE. Sex cord stromal ovary tumor pathology. Medscape references. drugs, diseases and procedures. 2011. Available from: <http://emedicine.medscape.com/article/1627984-overview>.
5. Karlan BY, Markman MA, Eifel PJ. Ovarian cancer, peritoneal carcinoma, and fallopian tube carcinoma. In: Devita VT, Hellman S, Rosenberg SA, eds. *Cancer principle & practice of oncology*. 7nd ed. USA: Lippincott Williams & Wilkins. 2005; pp.1364-1397.
6. Roth LM. Sex cord stromal tumor of the ovary . Young RH, Scully RE. Steroid cell tumor of the ovary. In: Fox H, Wells M, editors. *Obstetrical and Gynecological pathology*. 5nd ed. United kingdom; 2003; pp.745-765, 845-849.
7. Nardo LG, Ray DW, Laing I, Williams C, McVey RJ, Seif MW. Ovarian Leydig cell tumor in a peri-menopausal woman with severe hyperandrogenism and virilization. *Gynecol Endocrinol*. 2005 Oct; 21(4):238-41. Available from: <http://www.ncbi.nlm.nih.gov/pubmed/16316848>.
8. Haji AG, Sharma S, Babu M, Vijaykumar D, Chitrathara K. Androgen secreting steroid cell tumor of the ovary in a young lactating women with acute onset of severe hyperandrogenism: a case report and review of literature. *J Med Case Reports* 2007. 18(1):182. Available from: <http://www.jmedicalcasereports.com/content/1/1/182>.
- 9 . Magyar E, Kisfaludy N. Leydig cell tumors not classified as Sertoli-Leydig group. *CME Journal of Gynecologic Oncology* 2002; 7: 164–166. Available from: www.cme.hu/dlObject.php?aid=360&/164-66xx.PDF.
10. Crum CP, Nucci M R, Lee K. Sex cord-stromal and miscellaneous tumors of the ovary. In: Crum CP, Nucci M R, Lee K, editors. *Diagnostic Gynecologic and obstetric pathology*. 2nd ed. Elsevier saunders. 201; pp.938-945.
11. Paoletti M, Pridjian G, Okagaki T, Talerman A. A stromal Leydig cell tumor of the ovary occurring in a pregnant 15-years-old-girl ultrastructural finding. *Wiley online library* 2006. Available from: <http://onlinelibrary.wiley.com/doi/10.1002/10970142%2819871201%2960:11%3C2806::AID-CNCR2820601135%3E3.0.CO;2-E/pdf>.
12. Faria AM, Perez RV, Marcondes JA, Freire DS, Blasbalg R, Soares J, et al. A premenopausal woman with virilization secondary to an ovarian Leydig cell tumor. *Nat Rev Endocrinol*. 2011 Apr; 7(4):240-5. Epub 2011 Feb 15.
13. Bancos I, Prawius H. Leydig cell tumor of the ovary in a postmenopausal woman presenting with virilization. *The Endocrinologist*. 2008 june. volume 18, number3. Pp 146-149. Available from: <http://ovidsp.tx.ovid.com/sp-3.5.1a/ovidweb.cgi>.