

Treatment of neglected malunion of the distal radius: a cases series study

Asghar Elmi¹, Ali Tabrizi², Alireza Rouhani³, Fardin Mirzatolouei⁴

Received: 26 March 2013

Accepted: 14 June 2013

Published: 17 Feb 2014

Abstract

Background: Malunion is the most common complication following distal radius fractures. Aim of this study was to evaluate the results of distal radius corrective osteotomy and plate fixation by dorsal approach in the malunion.

Methods: In this retrospective study, 14 patients with neglected distal radius malunion from 2005 to 2011 were studied. All patients were treated with an opening wedge osteotomy with a dorsal plate and cancellous bone grafting. Radiological and clinical measurements were performed pre and postoperatively. All patients were followed at least for two years.

Results: Fourteen patients with a mean age of 42.5±10.2 years including 2 females (14.2%) and 12 males (85.8%) were studied. Radiological healing was achieved in all osteotomies at a mean of 11.5 (range: 11 to 14) weeks. There were significant differences between wrist function and radiological findings before and after treatment. Following the operation, all patients were relieved of pain. There were not any complications.

Conclusion: Based on our findings, dorsal approach for osteotomy and plate insertion is an effective approach with good final results and no major complication for the treatment of distal radius malunion.

Keywords: Osteotomy, Radius Fracture, Malunited fractures.

Cite this article as: Elmi A, Tabrizi A, Rouhani A, Mirzatolouei F. Treatment of neglected malunion of the distal radius: a cases series study. *Med J Islam Repub Iran* 2014 (17 Feb). Vol. 28:7.

Introduction

Distal radius fractures are the most common fractures in the upper extremity (1). One of the major complications following fractures of the distal end of the radius is malunion (2). While the malunion rate in surgically treated distal radius fractures is 10%, with conservative methods the rate of malunion increased to 23.5% (1,2). Patients with malunion of the distal radius present either with poor radiographic alignment before complete healing of the fracture (nascent malunion) or with functional problems that may be related to inadequate alignment of a healed fracture (mature

malunion) (3). Malunions after distal radius fractures are usually dorsally angulated (3). Corrective osteotomy is now an established treatment for symptomatic cases (3). This study aimed to evaluate long term results of corrective radius osteotomy and dorsal plate fixation in cases with neglected malunion.

Methods

This retrospective study was conducted at the Trauma Center of Northwestern Iran (Shohada hospital affiliated to Tabriz University of Medical Sciences) from 2005 to 2011. In this study, 14 patients suffering from wrist movement disorder due to a

1. Assistant Professor of Orthopedic Surgery, Shohada Hospital, Tabriz University of Medical Sciences, Tabriz, Iran. elmimail@yahoo.com

2. (Corresponding author) Resident of Orthopedics Surgery, Shohada Hospital, Tabriz University of Medical Sciences, Tabriz, Iran. ali.tab.ms@gmail.com

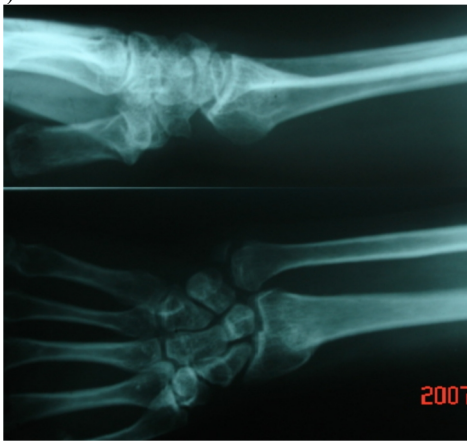
3. Associate Professor of Orthopedic Surgery, Shohada Hospital, Tabriz University of Medical Sciences, Tabriz, Iran. Rouhani.m.d@gmail.com

4. Associate Professor of Orthopedic Surgery, Motahari Hospital, Urumieh University of Medical Sciences, Urumieh, Iran. fardin_tolouei@umsu.ac.ir

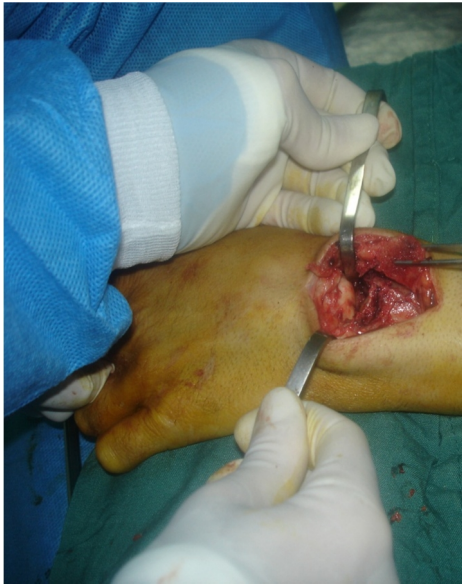

Fig. 1. Dorsal approach was used for osteotomy and fixation in patients with distal radius malunion.

(A)



(B)

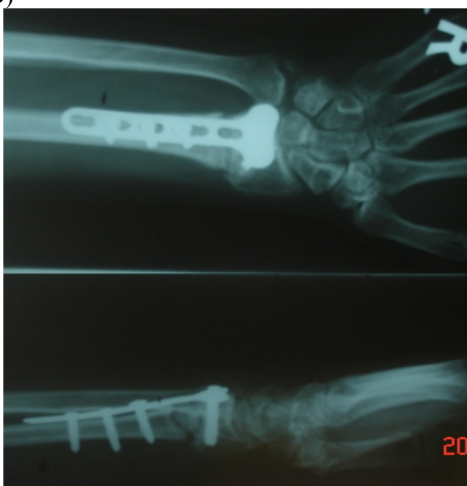

Fig. 2A and 2 B. The patient's; preoperative comparative, Radiographs (A) and postoperative radiographs (B).

previous distal radius fracture with severe malunion, for a period of around two years

following the trauma, were enrolled. Malunions were diagnosed using the radiographs taken upon the patients. Those meeting the inclusion criteria were invited to participate in the study. A written informed consent was also collected from each case. Inclusion criteria were malunion with a dorsal angulation, <1 mm step-off on the radiocarpal joint surface, $>15^\circ$ permanent dorsal angulation in the original fracture site, <20 mm positive ulnar variance, clearly apparent deformities, as well as complaints associated with inefficiency in daily activities (pain, restricted wrist motion and reduction in grip strength). The exclusion criteria were history of previous hand surgery, congenital deformity in limbs, cerebral palsy, patients with metabolic disease and smoking. The patients were followed-up at least for two years. Written informed consent was obtained from all patients. The study was confirmed by the ethics committee of Tabriz University of Medical Sciences.

Operative technique

The surgery was done under general anesthesia, in a bloodless field. Intraoperative fluoroscopy was used for imaging survey. The dorsal wrist approach was done through a 10-cm dorsal curvilinear incision centered over the Lister tubercle (Fig. 1). The extensor tendons of the fingers were retracted medially (toward the ulna) to expose the dorsum of the wrist joint and to allow transverse incision of the capsule. The suitable level of the osteotomy was determined based on preoperative radiographs and intraoperative images. The osteotomy was wedged open to achieve correction. A full-thickness cortico-spongious graft from the iliac crest was fitted into the defect. We used a dorsal T-plate for fixation (Figs. 2A and 2B). The plate was then placed on the bone and fixed. Using the plate as a joystick under C-Arm monitoring, sagittal and frontal plan corrections in the osteotomy site were performed. In patients who had instability due to the distal radio-ulnar joint (DRUJ) repair was performed.

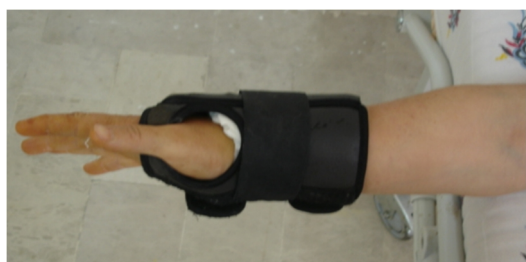

Fig. 3. After 4 weeks plaster slab removal, wrist splint was given for 2 weeks.

(A)



(B)

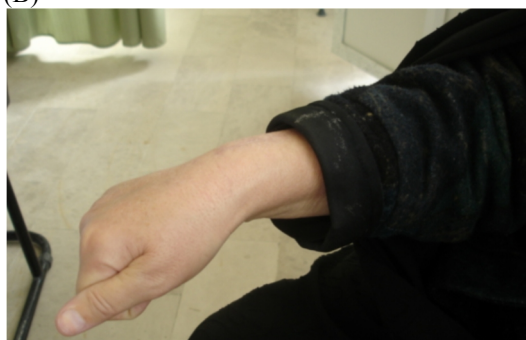

Fig. 4A and 4B. Clinical photo showed that functional improvement after operative treatment.

Follow-up

Following the operation, the wrist was immobilized in a dorsal plaster slab for 4 weeks in all cases. At 4 weeks, radiographs were taken and the plaster was removed.

Afterwards, all patients were given a wrist splint for 2 weeks (Figure 3). For the rehabilitation of patients, free exercises were instituted. Patients pain was evaluated using a visual analog scale (VAS).

Statistical analysis

Descriptive statistical indices (frequency, percentage), mean \pm standard deviation (SD), and Medcalc software were used to statistically analyze the data. Comparison of variable changes before and after the surgical treatment was done using paired T test. In this study, $p < 0.05$ was regarded statistically meaningful.

Results

In this study, 14 patients with a mean age of 42.5 ± 10.2 years including 2 females (14.2%) and 12 men (85.8%) were studied. Radiological healing was achieved in all osteotomies after a mean of 11.5 (range: 11 to 14) weeks. There was no loss of reduction. Mean ulnar variance was 0 (0-2) mm, radial angulation was 24 (21-35) degrees, and volar tilt was 5 (2-9) degrees. There were no postoperative complications in the extensor tendon functions, surgical site infection, nonunion of the graft or plate breakage. Patients' radiological and clinical findings are depicted in Table 1. In all treated patients, function had returned to the initial state (Figure 4A and 4B). After the operation, all patients were relieved of pain. The distal radio-ulnar joint (DRUJ) repair was performed in 9 (64.2%) cases. Measurement of rotation in patients showed a significant improvement in follow up exams with the absence of pain in the distal

Table 1. Clinical and radiographic findings in patients with distal radius malunion.

Variable	Pre-Operative	Post-Operative	p value
Pain (by VAS)	7.5 \pm 1.4	2.3 \pm 0.5	0.01
Ulnar variance(mm)	13.2 \pm 2.3	1 \pm 0.5	<0.001
Radial tilt angle(degree)	30.2 \pm 8.2	4.2 \pm 2.1	0.04
Radial inclination angle(degree)	19.7 \pm 5.6	22.3 \pm 1.7	0.02
Wrist flexion(degree)	40.4 \pm 14	54.6 \pm 12.3	0.02
Wrist extension(degree)	52.1 \pm 6.2	58.3 \pm 8.2	0.04
Radial deviation(degree)	5.5 \pm 2	7.5 \pm 1.4	0.01
Ulnar deviation(degree)	17 \pm 3.2	22 \pm 2.4	0.03
Forearm pronation(degree)	62.5 \pm 4.2	75.5 \pm 9.5	<0.001
Forearm supination (degree)	56.4 \pm 9.6	77.2 \pm 10.5	<0.001

radio-ulnar joint (DRUJ) (Table1).

Discussion

Anatomic restoration is necessary to maintain sufficient function of the wrist following distal radius fractures (4). Inappropriate treatment of distal radius fractures can lead to serious complications (3,4). Malunion can cause dysfunction of wrist joint so that patients are facing with many problems in performing daily tasks (5). Jacob et al (6) found that a dorsal angle of more than 20° and a radial inclination of less than 15° were associated with more complaints and patient dissatisfaction. Surgical treatment that is the ideal treatment can be obtained through an optimal anatomic correction (6). In the past two decades, osteotomies have been used for the treatment of malunions of distal radius fractures (7,8). Pain was a prominent preoperative complaint; this may be due both to incongruity of the distal radio-ulnar joint and to impingement of the ulnar part of the carpus on the ulnar head (9). Pain relief is one of the key goals in addition to improving their performance. In our patients, postoperative pain relief was complete in all of them. Linder and Stattin (9) study on 6 patients with distal radius malunion showed that postoperatively, ulnar head pain was alleviated after corrective osteotomy. They used of volar approach for the osteotomy with no complications (9). Treatment of distal radius fractures by fixed angle volar plates is widely used (10). The high biomechanical resistance of the plates, as well as the advantages entailed by the volar approach, are the key motives for the use of this method (11). In a study by Kilic et al, fixed-angle volar plates provide a stable fixation after corrective osteotomies of the distal radius and might be a safer alternative to conventional fixation methods (11). Various methods have been used for the treatment of malunion (11). Osteotomy and fixation in the distal radius malunion has not a long history (11). Oskam et al (13) performed a combination of ulnar-shortening osteotomy and radial corrective

osteotomy. It is a reliable technique with good results. In their study, indication for the combined procedure was a relative ulnar length of minimally 6 mm (13). Amy and Donald (14) were expressed that surgical reconstruction for malunion is technically difficult and may not completely restore the anatomy, but at least increased function, decreased pain, and decreased deformity is sufficient (14). Dorsal angulation also affects DRUJ mechanics by altering the congruity of this joint, increasing the likelihood of range of motion deficits in forearm rotation and symptomatic instability. In our study, similar to the previous ones, the treatment using distal radius osteotomy reduces pain and improves the function so that the primary goals of treatment can be achieved. The dorsal plate insertion is associated with a reduction in side effects. The most common side effects listed for volar approach are median nerve injury, flexor tendon dysfunction and complex anatomy in volar site.

Conclusion

Based on our findings, in the distal radius malunion, dorsal approach for osteotomy and plate insertion is an effective treatment with good final results. No complications related to this approach were seen.

References

1. Jakubietz MG, Gruenert JG, Jakubietz RG. Palmar and dorsal fixed-angle plates in AO C-type fractures of the distal radius: is there an advantage of palmar plates in the long term? *Journal of Orthopaedic Surgery and Research* 2012, 7:8.
2. Amadio PC, Botte MJ. Treatment of malunion of the distal radius. *Hand Clin* 1987; 3:541-61.
3. David R. Treatment of the Neglected Distal Radius Fracture. *Clinical Orthopedics & Related Research*, 2005; 431: 85-92.
4. Orbay JL. The treatment of unstable distal radius fractures with volar fixation. *Hand Surgery*, 2000; 5(2):103-112.
5. Hollevoet N, Verdonk R. The functional importance of malunion in distal radius fractures. *Acta Orthopædica Belgica*, 2003; 69(3):239-245.
6. Jacob M, Mielke S, Keller H, Metzger U. Therapieergebnisse nach primär konservativer Versorgung distaler Radiusfracturen bei Patienten im

Alter von über 65 Jahren. Handchir Mickroschir Plast Chir 1999; 31: 241-245.

7. Bushnell BD, Bynum DK. Malunion of the distal radius J Am Acad Orthop Surg 2007; 15:27-40.

8. Posner MA, Ambrose L. Malunited Colles' fractures: Correction with a biplanar closing wedge osteotomy. J Hand Surg Am 1991; 16:1017-26.

9. Linder L, Stattin J. Malunited fractures of the distal radius with volar angulation Corrective osteotomy in 6 cases using the volar approach. Acta Orthop Scand 1996; 67 (2): 179-1 81.

10. Nalbantoglu U, Gereli A, Ucar Y, Turkmen M. Comparison between fixation with dorsal T plate and palmar locking plate in the treatment of unstable displaced distal radius fractures. Acta Orthop Traumatol Turc 2008; 42(5):365-372.

11. Gesensway D, Putnam MD, Mente PL, Lewis JL. Design and biomechanics of a plate for the distal radius. J Hand Surg Am 1995; 20:1021-7.

12. Kilic A, Kabukcuolu YS, Gul M, Sokucu S, Ozdoan U. Fixed-angle volar plates in corrective osteotomies of malunions of dorsally angulated distal radius fractures. Acta Orthop Traumatol Turc 2011; 45(5):297-303.

13. Oskam J , Bongers KM. , Karthaus A.J.M. , Frima AJ , Klasen HJ. Corrective osteotomy for malunion of the distal radius. Archives of Orthopaedic and Trauma Surgery, 1996; 115(3-4):219-222.

14. Amy L A, Donald S H. Reconstructive Osteotomy for Malunion of the Distal Radius. Clinical Orthopaedics & Related Research, 1996 ;(327) :158-171.