

Rare Association of Severe Cryptococcal and Tuberculosis in Central Nervous System in a case of Sarcoidosis

Bahaadin Siroos¹, Zahra Ahmadinejad², Mohamad Tabaeizadeh³
Mojtaba Hedayat Yaghoobi⁴, Alireza Torabi⁵, Majid Ghaffarpour⁶

Received: 28 Apr 2013

Accepted: 7 July 2013

Published: 11 Mar 2014

Abstract

Sarcoidosis is a multisystem noncaseating granulomatous disease with a propensity for lung, eye, and skin which recently have been proposed that mycobacterium tuberculosis may contribute in its pathogenesis, and rarely involves central nervous system (CNS). Despite CD4+ lymphocytopenia, sarcoidosis by itself does not increase risk of opportunistic infections other than cryptococcosis. Nonetheless, simultaneous association of CNS cryptococcosis and tuberculosis infection remains extremely rare event in immunocompetent states, and has not been reported in sarcoidosis yet. We here presented such a case in a 42 years old man, a known case of sarcoidosis with diagnostic and therapeutic difficulties were encountered in a fourteen-month-long hospitalization period.

Keywords: Sarcoidosis, ventriculomeningitis, hydrocephalus, cryptococcosis, Tuberculosis.

Cite this article as: Siroos B, Ahmadinejad Z, Tabaeizadeh M, Hedayat Yaghoobi M, Torabi A, Ghaffarpour M. Rare Association of Severe Cryptococcal and Tuberculosis In Central Nervous System in a case of Sarcoidosis. *Med J Islam Repub Iran* 2014 (11 Mar). Vol. 28:22.

Introduction

Association of CNS cryptococcosis and tuberculosis meningitis remains extremely rare event, especially when a concurrent severe immunodeficiency state such as HIV disease is excluded (1). Thus, limited anecdotal cases of concomitant CNS cryptococcosis and tuberculosis were reported in international literatures. Of our knowledge this association has not been reported in sarcoidosis yet (2-3). We introduced here such a case.

Case Report

A 42-year-old Iranian man, a known case of sarcoidosis, presented with fluctuating hearing loss, headache, confusion and impaired cognition. The patient was in good health until July 2007 that was treated with prednisone and azathioprine for two years with impression of sarcoidosis. He did not receive any medication from 2009 till 2011. In May 2011, he developed hearing loss, headache and perioral skin lesions. The patient was admitted in a local hospital and after some clinical and laboratory evaluation, treated by a three days cyclophosphat-

1. Resident of Neurology, Imam Khomeini Hospital, Iranian Center of Neurological Research, Tehran University of Medical Sciences, Tehran, Iran. bsiroos@gmail.com
2. Associated Professor of Infectious Disease, Imam Khomeini Hospital, Department of Infectious Disease, Tehran University of Medical Sciences, Tehran, Iran. ahmadiz@tums.ac.ir
3. Resident of Neurology, Imam Khomeini Hospital, Iranian Center of Neurological Research, Tehran University of Medical Sciences, Tehran, Iran. motif42@gmail.com
4. Resident of Infectious Disease, Imam Khomeini Hospital, Department of Infectious Disease, Tehran University of Medical Sciences, Tehran, Iran. newdrmy@yahoo.com
5. Resident of Neurology, Imam Khomeini Hospital, Iranian Center of Neurological Research, Tehran University of Medical Sciences, Tehran, Iran. abghsa@gmail.com
6. (Corresponding author) Professor of Neurology, Iranian Center of Neurological Research, Tehran University of Medical Sciences, Tehran, Iran. ghafarpour@sina.tums.ir

mid pulse with impression of sarcoidosis exacerbation. Brain imaging was normal at this time (Fig. 1. A). He improved clinically to some extent; but after one month developed progressive severe headache, fluctuating cognitive impairment, and decreased level of consciousness due to symptomatic communicating hydrocephalus (Fig. 1. B). A ventriculoperitoneal (VP) shunt was inserted emergently in right frontal horn of lateral ventricle. Patient's clinical symptoms were ameliorated relatively with VP shunting. Findings of cerebrospinal fluid analysis showed protein, 1 gr/dl; glucose, 27 mg/dl; without cell. The results of the gram stain, Indian ink and staining for acid fast bacilli, *Mycobacterium tuberculosis* (MTB) polymerase chain reaction (PCR), and results of serum human immunosuppressive virus (HIV) and human T-cell leukemia virus tests all were negative. Thyroid function tests showed subclinical hypothyroidism. Anti Thyroid peroxidase (TPO) antibody was negative. Antinuclear antibody, complement, vitamin B12, and folate levels were normal. In July 2011, prednisolone, 60 mg/day, was started with suggestion of neurosarcoidosis. The disease had an insidious progressive course. Repeated CSF analyses were inconclusive. Hence, a trial of infliximab and rituximab were tried with hypothesis of intractable neurosarcoidosis in September 2011. No

clinical improvement was seen. After 4 months (Jan 2012), due to deterioration of neurological symptoms he was referred to our center. A complete immunological-infectious-rheumatological work up was done on him and the CSF analysis disclosed high protein (about 1350 mg/dl), low glucose; (27 mg/dl) without any cell.

Brain T2W imaging disclosed multiple periventricular hypersignal lesions and non-communicating hydrocephalus (especially left side). Likewise, extensive meningeal enhancement was in favor of chronic progressive inflammatory ventriculomeningitis. We empirically started anti-tuberculosis treatment. Pathological reports of meningeal biopsy showed inflammatory changes without characteristic finding or granuloma. After 5 days, the search for the yeast-specific polysaccharide antigen by a commercial latex agglutination assay became positive for *Cryptococcus neoformans*. The conditions such as rheumatoid factor, sera with >200 mg Fe $^{3+}$ /dL, improper cleaning of the ring slide, and non-specific reactivity in HIV-infected patients which can lead to false positive reactions to Latex Agglutination Test were excluded (4-5). All tested samples of CSF and serum of our patient were negative for Indian ink staining. This staining procedure usually is expected to be positive in 72.4% of patients with cryptococcal meningitis (6). Ampho-

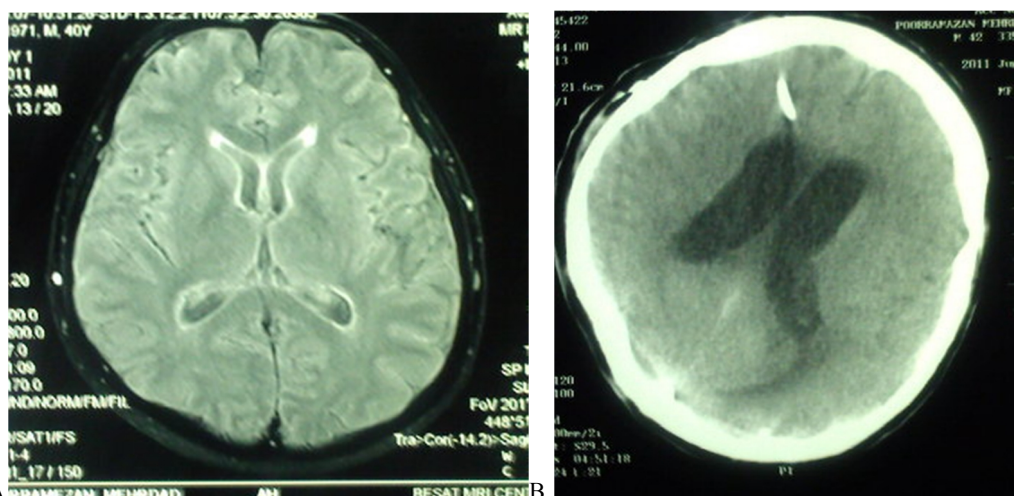


Fig.1. Although at presentation (April 2011), no radiological abnormalities were reported on brain MRI (A), In Jun 2011, because of deterioration of clinical symptoms (diplopia, severe progressive headache, and decreased level of consciousness) due to development of symptomatic communicating hydrocephalus, a ventriculoperitoneal shunt was inserted in right frontal horn of lateral ventricle which led to relative improvement of clinical symptoms (B).

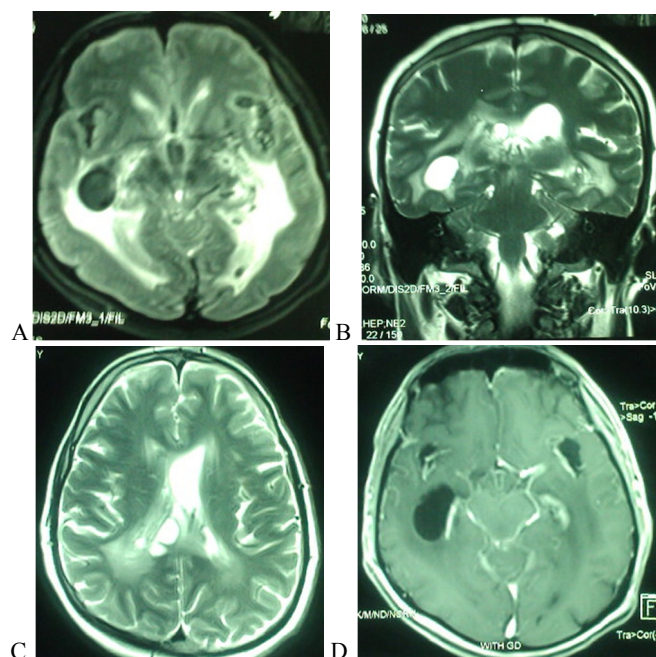


Fig. 2. Imaging study: Extensive periventricular lesions and multiple cystic changes, were detected on FLAIR (A) and T2W (B, C) brain image. MRI with Gadolinium (D) enclosed significant ventricular and basal cisterna enhancement despite of antifungal treatment. Above findings were in favor of persistent infectious inflammatory reaction.

tericin B plus Flucytosine was started with a diagnosis of cryptococcal ventriculitis and anti-tuberculosis drugs were discontinued. Due to cystic changes of ventricles and shunt malfunction, a new ventriculoperitoneal (VP) shunt was inserted in the frontal horn of left lateral ventricle. The patient developed drug induced hepatitis after 5 days. Therefore flucytosine was discontinued. Repeated CSF examinations pointed out persistent increased in albumin content, and low glucose levels without any cell. Microscopic, culture, and PCR for detection of mycobacterium tuberculosis in CSF remained negative for the first two months. Meanwhile, the patient was resistant to fluconazole for treatment of cryptococcus. After two months of systemic antifungal treatment, the patient deteriorated insidiously, with abnormal CSF, protein above 1 gr/dl, glucose below 20 mg/dl, cell; (2 lymphocyte), and Adenosine Deaminase (ADA); (7 IU/L). The MRI findings of brain showed severe meningeal enhancement and progressive white matter lesions (Figure 2). Therefore, reevaluation was done with suspicion of amphotericin resistant fungal infection, shunt superinfection, reactivation of neurosarcoidosis, and

co-infection of cryptococcosis and other infections such as tuberculosis. Because of decreased level of consciousness due to increased intracranial pressure, the patient emergently operated and right temporal horn cystic lesion was evacuated. Gross appearance of brain revealed congested and inflamed cortex with severe rise of Intracranial Pressure (ICP), accompanied with multiple patchy white exudates on the surface of cerebral cortex that was suggestive for fungal infection (cryptococcosis). The CSF sample (from temporal cystic lesion) showed spider web clot appearance which was suggestive for tuberculosis. At this time, PCR test for mycobacterium tuberculosis, Acid Fast Bacilli (AFB) smear, and culture were positive in CSF and brain specimens. No granuloma was reported in pathological studies. Cryptococcal latex agglutination test was positive. Only at this time we had the first positive sign in PCR test and AFB smear and culture for mycobacterium tuberculosis from CSF. Repeated sputum, bronchoalveolar lavage fluid, and urine smear for AFB and tuberculin skin test were all negative. Unfortunately, despite combined therapy of amphotericin B (systemic and intraventricular) and an-

Table 1. Laboratory tests Results

CSF	First admission			Admission in our department			
	Jun 2011	Sep 2011	Jan 2012	Day 21	Day 28	Month 2	Week 10
Source of sample	VPS	L3-L4	VPS	VPS	L3-L4	VPS	VPS
Protein (mg/dl) [†]	1000	1300	1350	980	1560	1000	1300
Glucose (mg/dl) [‡]	27	21	27	21	27	17	20
White cells (per mm ³)	0	0	0	0	5	2	5
Polymorphonuclear cells (%)	0	0	0	0	0	0	0
Lymphocytes (%)	0	0	0	0	100%	100%	100%
Red cells (per mm ³)	0	0	0	0	0	0	0
Gram's staining	No bacteria	Staph.epidermidis [‡]	No bacteria	No bacteria	No bacteria	No bacteria	No bacteria
Bacterial culture	No growth	No growth	No growth	No growth	No growth	No growth	No growth
Indian ink staining	Negative	Negative	Negative	Negative	Negative	Negative	Negative
Cryptococcal antigen [§]	Not performed	Not performed	++++	++	++	++	++++
Cryptococcus culture	Not performed	Not performed	Positive	Negative	Negative	Negative	Negative
AFB smear & Culture	Negative	Negative	Negative	Negative	Negative	Negative	Positive
Mycobacterium PCR	Negative	Negative	Negative	Negative	Negative	Negative	positive
ADA (IU/L)	Not performed	Not performed	5	Not performed	7	7	Not performed
Serum							
Glucose (mg/dl)	120	118	108	128	115	125	116
Cryptococcal antigen	Not performed	Not performed	++++	Negative	++	+++	++++

[†]The reference range for protein is 25 to 55 mg per deciliter.

[‡]The reference range for glucose is 45 to 75 mg per deciliter.

[‡] Vancomycin and Ceftriaxone were prescribed for seven days, but was discontinued because of negative culture and new gram stain tests.

[§] The experiment was done by latex-Cryptococcus antigen detection system.

VPS: Ventriculoperitoneal shunt; ADA: Adenosine deaminase; AFB: Acid fast Bacilli; PCR: Polymerase Chain Reaction

titubercular treatment with five drugs (isoniazid, rifampin, etambutol, pirazinamide and streptomycin), the patient deteriorated clinically and died after several weeks.

Discussion

Simultaneous association of cryptococcosis and tuberculosis is well recognized in immune-compromised states such as patients with HIV and gold-miners especially in a cases of silicosis (1, 7-8). It seems that a common immunological defect may be shared in this rare event. Immunomodulative states such as innate immune system impairment, vitamin D deficiency, HIV, and drug induced immunosuppression due to rituximab and infliximab are risk factors for reactivation of latent infections such as tuberculosis and cryptococcosis (9-10). Dea Garcia-Hermoso and et al. observed that latent cryptococcal infection may become reactivate even 9 to 13 years after dissemination (11). Likewise, recently, Joseph, and et al. postulated that tuberculosis infection

is an independent risk factor for reactivation and dissemination of cryptococcal infection in HIV patients of South Africa (9). This hypothesis is compatible with observations of Murray and et al. in African HIV patients showing that cryptococcal infection is a main cause of late mortality and morbidity in patients with tuberculosis who were treated with antituberculosis drugs (12). On the other side, Ellerbroek and et al. have shown that components of polysaccharide capsule of cryptococcus such as glucurono-xylo-mannan and galactoxylo-mannan can lead to induction of suppressor T cells and inhibition of leukocyte chemotaxis to inflammatory sites (13-14). These phenomena may explain immunosuppression that is accompanied with cryptococcosis and thereby rare but plausible association of cryptococcosis and tuberculosis even in an immunocompetent patient (15). Our patient was a known case of cutaneous sarcoidosis that became complicated by simultaneous cryptococcosis and tuberculo-

sis infection of CNS.

Sarcoidosis is a multisystem noncaseating granulomatous disease with a propensity for lung, eye, and skin which in less than 5 percent of patients involves nervous system (16-17). Its etiology and pathogenesis are not fully identified yet. Recently, immunopathological similarities between sarcoidosis and mycobacterial diseases became an attractive subject for investigators. Both tuberculosis and sarcoidosis are granulomatous diseases that are accompanied with antigen-specific Th1 response (18). Hajizadeh and et al. have reported that antibodies against mycobacterial antigens such as recombinant mycobacterium tuberculosis catalase-Peroxidase and early secreted antigenic target protein were elevated in the sera of patients with sarcoidosis (19). They found significant difference between sarcoidosis patients and PPD negative controls by evaluating immune response to mycobacterial antigens with *x vivo* enzyme-linked immunospot assay (ELISPOT) on peripheral blood mononuclear cells (PBMNC). Eishi and et al could isolate mycobacterial DNA and RNA from sarcoidal tissues by PCR techniques (20). According to these evidences, some investigators postulated that sarcoidosis may be an immune reaction to mycobacterium tuberculosis (21). Nonetheless; immunological reactions in sarcoidosis are complex and usually seem as a paradox. Despite CD4+ lymphocytopenia, sarcoidosis by itself does not increase risk of opportunistic infections other than cryptococcosis (5, 22). Likewise, in spite of significant regional and systemic granulomatous inflammation in patients with sarcoidosis, the immune response to tuberculin is suppressed and lead to allergy (23). Given this, we think that probably after exposure to mycobacterial antigens, some genetic or epigenetic predisposing factors modulate immune system and lead to sarcoidal reactions, like immunological reactions to mycobacterium leprea. Hence, it may be plausible to expect that sarcoidosis patients be susceptible to reactivation of latent mycobacterium in specific conditions

which change aforementioned modulating factors. In our patient, it seems that immunomodulation due to cryptococcosis and drug (rituximab and infliximab) induced immunosuppression may be important in reactivation of latent tuberculosis. Surely, more studies are required to explain correlation between tuberculosis and sarcoidosis and elucidate this hypothesis.

Introduced patient had unusual presentations that led to delayed diagnosis of tuberculosis. Despite several diagnostic work ups, until late stages of disease no evidence of mycobacterium bacilli was detected and all primary work ups were negative for acid fast bacilli. Meningitis due to tuberculosis usually is associated with mononuclear cell in CSF pleocytosis, high albumin content and low glucose level. Only in approximately 5 percent of immunocompetent patients and 11 percent of immunosuppressive patients, CSF cell count would be less than 5 in microliter that it can be an indirect sign of severity of disease (24). Repeated CSF analysis of presented patient during several months disclosed no evidence of pleocytosis that is not typical for tuberculosis. Moreover, untreated tuberculosis infection of CNS has a progressive course and almost always results in death in 3 to 6 weeks (25). Our patient had a slowly progressive course for months without treatment. Probably, cryptococcosis or sarcoidosis-induced immunomodulation or unique strain of mycobacterium tuberculosis species may be shared in this problem.

Conclusion

Although in immunocompetent state and sarcoidosis, co-infection of CNS cryptococcosis and tuberculosis is very rare, clinical deterioration in patients who receive anti cryptococcal treatment should prompt an aggressive work up for identifying additional infectious agent especially tuberculosis; and vice versa. Since miss or delay in diagnosis of an unsuspected disorder can lead to irrecoverable sequels.

References

1. Jarvis JN, Harrison TS. HIV-associated cryptococcal meningitis. *Aids* 2007; 21:2119–2129.
2. Rawat D, Capoor MR, Nair D, Deb M, Aggarwal P. Concomitant TB and cryptococcosis in HIV-infected patients. *Trop Doct* 2008; 38:251-2.
3. Girard N, Cottin V, Hot A, Etienne-Mastroianni B, Chidiac C, Cordier JF. Opportunistic infections and sarcoidosis. *Rev Mal Respir* 2004; 21(6 Pt1):1083-90.
4. Heelan JS, Corpus L, and Kessimian N. False-positive reactions in the latex agglutination test for *Cryptococcus neoformans* antigen. *J Clin Microbiol*. 1991; 29: 1260-1261.
5. Whittier SR, Hopfer L, Gilligan P. Elimination of false-positive serum reactivity in latex agglutination test for cryptococcal antigen in human immunodeficiency virus-infected population. *J Clin Microbiol*. 1994; 32:2158-2161.
6. Saha DC, Xess I, and Jain N. Evaluation of conventional & serological methods for rapid diagnosis of cryptococcosis. *Indian J Med Res*. 2008; 127: pp 483-488.
7. Saag MS, Graybill RJ, Larsen RA, Pappas PG, Perfect JR, Powderly WG, et al. Practice guidelines for the management of cryptococcal disease. *Infectious Diseases Society of America. Clin Infect Dis*. 2000; 30:710-8.
8. Corbett EL, Churchyard GJ, Clayton TC, Williams BG, Mulder D, Hayes RJ, De Cock KM. HIV infection and silicosis: the impact of two potent risk factors on the incidence of mycobacterial disease in South African miners. *Aids*. 2000; 14: 2759–2768.
9. Joseph NJ, Thomas SH, Elizabeth LC, Robin W, and Stephen DL. Is HIV-associated tuberculosis a risk factor for development of cryptococcal disease? *AIDS*. 2010; 20; 24(4): 612–614.
10. Muñoz P, Giannella M, Valerio M, Soria T, Díaz F, Longo JL, Bouza E. Cryptococcal meningitis in a patient treated with infliximab. *Diagn Microbiol Infect Dis*. 2007; 57(4):443-6.
11. Dea Garcia-Hermoso, Guilhem Janbon, and Françoise Dromer. Epidemiological Evidence for Dormant *Cryptococcus neoformans* Infection. *J Clin Microbiol*. 1999; 37(10): 3204–3209.
12. Murray J, Sonnenberg P, Shearer SC, Godfrey-Faussett P. Human immunodeficiency virus and the outcome of treatment for new and recurrent pulmonary tuberculosis in African patients. *Am J Respir Crit Care Med*. 1999; 159:733–740.
13. Lindsay VT, Tawimas S, John AF. Coinfection with *Cryptococcus gattii* and *Mycobacterium tuberculosis* in an otherwise healthy 18-year-old woman. *Can Respir J*. 2011; 18(4):e62-e63.
14. Ellerbroek PM, Walenkamp AM, Hoepelman AI, Coenjaerts FE. Effects of the capsular polysaccharides of *Cryptococcus neoformans* on phagocyte migration and inflammatory mediators. *Curr Med Chem*. 2004; 11:253-66.
15. Roberto M, Leonardo C. Severe brain coinfection by *cryptococcus neoformans* and *mycobacterium tuberculosis* as a consequence of non-bacillary lung tuberculosis. *Arch Neurocienc (Mex)*. 2009; 14(3): 192-195.
16. James DG, Hosoda Y. *Epidemiology in Sarcoidosis and other granulomatous disorders*. New York, Marcel Dekker. 1994;729–43.
17. Prezant DJ, Dhala A, Goldstein A et al. The incidence, prevalence, and severity of sarcoidosis in New York City fire fighters. *Chest*. 1999; 116:1183-93.
18. Dubaniewicz A, Dubaniewicz-Wybieralska M, Sternau A et al. Mycobacterium tuberculosis complex and mycobacterial heat shock proteins in lymph node tissue from patients with pulmonary sarcoidosis. *J Clin Microbiol*. 2006; 44:3448–51.
19. Hajizadeh R, Sato H, Carlisle J, et al. Mycobacterium tuberculosis antigen 85A induces Th1 immune responses in systemic sarcoidosis. *J Clin Immunol*. 2007; 27: 445-54.
20. Eishi Y, Suga M, Ishige I, et al. Quantitative analysis of mycobacterial and propionibacterial DNA in lymph nodes of Japanese and European patients with sarcoidosis. *J Clin Microbiol*. 2002; 40:198-204.
21. Isaac Brownell, Francisco Ramirez-Valle, Miguel Sanchez and Stephen Prystowsky. Evidence for Mycobacteria in Sarcoidosis. *Am. J. Respir. Cell Mol. Biol*. 2011; 45 (5): 899-905.
22. Dumouchel-Champagne H, Charlier-Woerther C, Boibieux A, Ffrench M, Carret G, Chidiac C, Peyramond D, Ader F. Disseminated nontuberculous infections with *Mycobacterium genavense* during sarcoidosis. *Eur Respir Rev*. 2009; 18(114):299-301.
23. Miyara M, Amoura Z, Parizot C, et al. The immune paradox of sarcoidosis and regulatory T cells. *J Exp Med*. 2006; 203:359-70.
24. Walter G. Bradely, et al. *Neurology in Clinical Practice*; Elsevier Inc, 5th edition 2008; 57:1438.
25. Walter G. Bradely, et al. *Neurology in Clinical Practice*; Elsevier Inc, 5th edition. 2008; 57:1437.