

Solitary fibrous tumor of the intrathoracic goiter

Mohammad Vaziri¹, Saadat Molanaei², Zeinab Tamannaie³

Received: 6 April 2013

Accepted: 19 November 2013

Published: 7 July 2014

Abstract

Solitary Fibrous Tumors (SFTs) are rare primary pleural neoplasms which have recently been reported in extra-thoracic sites. In this report, solitary fibrous tumor arising in an intra-thoracic goiter with no evidence of cervical mass in a 74-year-old obese man who was found to have a large superior mediastinal mass with tracheal deviation on Chest X-Ray is presented.

Keywords: Thyroid, Solitary Fibrous Tumor, Intrathoracic Goiter.

Cite this article as: Vaziri M, Molanaei S, Tamannaie Z. Solitary fibrous tumor of the intrathoracic goiter. *Med J Islam Repub Iran* 2014 (7 July). Vol. 28:51.

Introduction

Solitary Fibrous Tumors (SFTs) are rare primary pleural neoplasms which have recently been reported in extra-thoracic sites such as the meninges, nasal cavity, oral cavity, pharynx, epiglottis, salivary glands, thyroid, breast, kidney, bladder and spinal cord (1). In this report, solitary fibrous tumor arising in an intra-thoracic goiter with no evidence of cervical mass is presented.

Case Report

A 74-year-old obese man primarily admitted for prostatectomy, was found to have a large superior mediastinal mass with tracheal deviation on Chest X-Ray (Fig. 1). The patient had a previous history of cough and dyspnea with no personal attention and clinical evaluation. The physical examination was unremarkable with no cervical mass or adenopathy.

Computerized Tomography (CT) scan revealed a large retrosternal mass with right-sided tracheal deviation and compression extending from thyroid tissue with no invasion to surrounding structures and no ap-

parent cervical tumor (Fig. 1). No Ultrasonographic examination or fine-needle aspiration was carried out and in the context of normal laboratory tests (including thyroid function tests) and acceptable cardio-pulmonary evaluation, surgery via a cervical incision with no extension to sternum or thoracic cavity was performed.

In cases of suspected intra thoracic goiters (as in this case with a characteristic CT Scan) needle biopsy is unnecessary and is not recommended as a part of the diagnostic evaluation because an occult tumor would be inaccessible to random biopsy. The indications of trans-thoracic needle biopsy include any symptoms or signs of malignancy such as hoarseness (vocal cord paralysis), Horner's syndrome, Superior Vena Cava Syndrome, tracheal invasion and when a dominant cold nodule is clearly present. The clinical presentation and CT Scan findings in this patient did not suggest any malignant tumor.

Intra-operative findings included a well-circumscribed and brown-yellow mass with no involvement of surrounding structures

1. (Corresponding author) Associate Professor of Thoracic Surgery, Minimally Invasive Surgery Research Center, Iran University of Medical Sciences, Tehran, Iran. dr_m_vaziri@yahoo.com

2. Pathologist, Milad Hospital, Tehran, Iran. research_center88@yahoo.com

3. Minimally Invasive Surgery Research Center, Iran University of Medical Sciences, Tehran, Iran. zeinab_tamannaie@yahoo.com

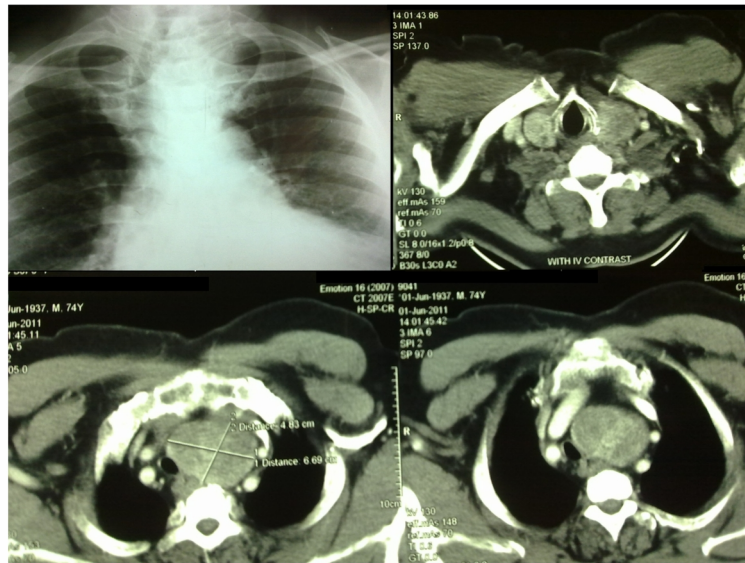


Fig. 1. Chest X-Ray and CT scan: Chest X-Ray shows a mass to the left of the trachea in the antero-superior portion of the visceral compartment with a characteristic tracheal deviation beginning in the cervical portion of the trachea which is typical of an intra-thoracic goiter. CT Scan reveals a large retrosternal mass with well-defined borders and non-homogeneity with discrete non-enhancing low-density areas located anteriorly in the visceral compartment of mediastinum. There is right-sided tracheal deviation and compression with no invasion to surrounding structures.

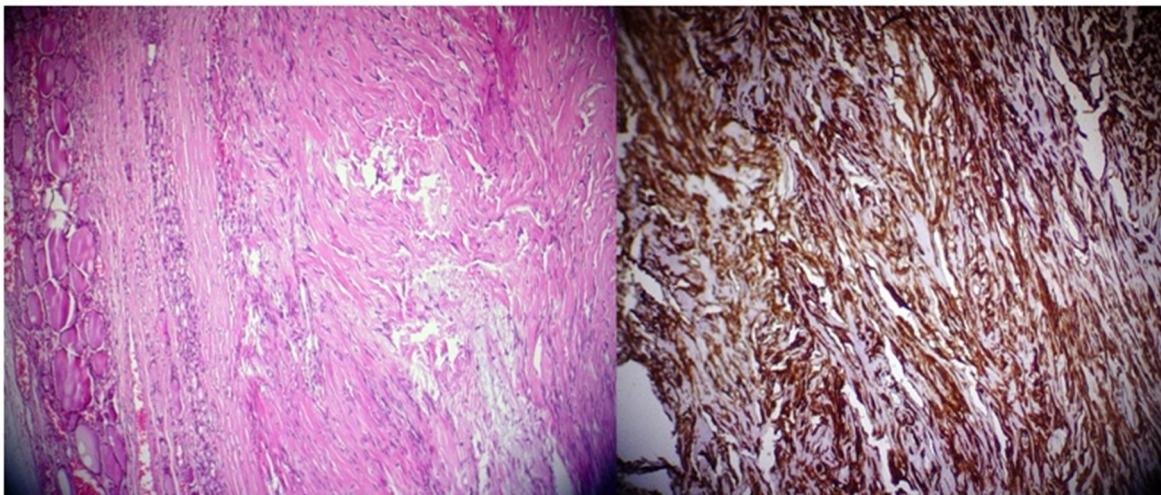


Fig. 2. Histopathologic view: The pathologic picture clearly shows simultaneous presence of thyroid tissue and solitary fibrous tumor which contains goiterous thyroid containing a neoplasm composed of spindle cells in a patternless growth intermingled with collagen bundles. The right portion of the picture shows IHC staining of the tumor with Immunohistochemistry positive reaction to CD 99.

which following total resection was 12*7*5 cm in size and weighing 114 grams. No intra-operative frozen section assessment was required because preoperative diagnosis based on clinical and imaging evaluation, was an intra-thoracic nonmalignant goiter and there was no intra-operative findings to justify this procedure.

Complete (near total) thyroidectomy was performed in order to significantly reduce the recurrence rate and patient is maintained on thyroid hormone replacement therapy with normal thyroid function tests.

Microscopic examination showed goiterous thyroid containing a neoplasm composed of spindle cells in a patternless growth intermingled with collagen bundles (Fig. 2). The tumor had high cellularity with no atypia, rich vascularization, rare mitotic figures and no necrosis.

According to the pathologist opinion, no high power field of histopathology finding was necessary because the reported diagnosis (thyroid SFT) was readily made by the depicted magnification (x4) and characteristic IHC evaluation. No Ki67 labeling in-

dex and TTF-1 or thyroglobulin immunohistochemistry assessments were required because the pathologist was certain of the diagnosis of a solitary fibrous tumor.

Immunohistochemistry (Fig. 2) revealed positive reaction for Vimentin, CD 34 and CD 99 in addition to negative reaction to Cytokeratin, Desmin and S100. After two years of follow-up, no evidence of local recurrence or distant metastasis is recorded.

Discussion

Most patients with substernal goiters which are considered masquerading lesion of a mediastinal tumor are thick-necked women in the seventh or eighth decade of life with a long-standing benign lesion. It is very unusual to encounter a patient with an intra-thoracic goiter containing a tumor such as Solitary Fibrous Tumor (SFT).

SFT is a rare primary localized pleural tumor which has been known by a variety of names that reflect its clinical course and controversies surrounding its histogenesis (2). Occurrence of this tumor in various reported extra-thoracic sites including thyroid (1) may demonstrate a mesenchymal origin of this mysterious neoplasm.

The distinction of SFT from other spindle cell malignancies may be difficult especially in the thyroid gland which may be the site of metastatic spread from other organs (mostly lung, kidney and larynx). Primary thyroid spindle cell lesions can be derived from follicular, C-cell or mesenchymal components and may be the result of neoplastic processes including Riedel thyroiditis, solitary fibrous tumor, leiomyoma, medullary carcinoma, anaplastic carcinoma, sarcoma and squamous cell carcinoma (3).

SFTs are usually encapsulated well-circumscribed masses with smooth external surfaces which on cut section are grey-white to tan with possible areas of hemorrhage or necrosis. Histologically, localized fibrous tumors appear as low-grade neoplasms of variable cellularity which is inversely related to the collagen content with minimal nuclear pleomorphism and rare mitoses. The most frequent microscopic

pattern is the “patternless pattern” in which there is intermingling of tumor cells and collagen in a random fashion and the second most common pattern is hemangiopericytoma-like appearance.

The cornerstone diagnostic tool for SFT is immunohistochemistry and the findings of CD34, vimentin positive and keratin negative tumor are so characteristic that make the exclusion of other tumors relatively straightforward. In this regard it has been suggested that mesenchymal tumors of the thyroid, reported in previous studies as Leiomyoma, Neurilemmoma and Hemangiopericytoma should probably classified as SFT (3).

The diagnosis of a thyroid SFT is rarely reached before surgical excision and pathological examination of the mass and because of the diversity of histologic patterns, percutaneous biopsy samples are insufficient for diagnosis. Accordingly we think that radiological tools like ultrasonography and percutaneous techniques such as FNA are not useful and indicated in a probable thyroid SFT as well as in any intrathoracic goiter.

Due to rarity of thyroid SFT in general and SFT arising in an intrathoracic goiter in particular, sound prediction and recommendation regarding the clinical behavior of the tumor or necessity of adjuvant therapy, respectively can not be made but cumulative data from previous reports suggest a benign nature and similar clinical-histological characteristics of its pleural counterpart (4). However, malignant solitary fibrous tumor of the thyroid with local recurrence and pulmonary metastasis has been reported (5).

We conclude that careful attention should be paid to the morphological and histological characteristics of thyroid SFT as the most important indicators of the outcome and all SFTs need long-term follow-up with aggressive surgical resection as the treatment of choice for the recurrence.

Reference

1. Vallat-Decouvelaere AV, Dry SM, Fletcher CDM. Atypical and malignant solitary fibrous tumors in extrathoracic locations: evidence of their comparability to intra-thoracic tumors. *Am J Surg Pathol.* 1998; 22:1501-1511.
2. Abu Arab W. Solitary fibrous tumors of the pleura. *Eur J Cardiothorac Surg.* 2012;41: 587-597.
3. Papi G, Corrado S, LiVolsi VA. Primary spindle cell lesions of the thyroid gland; an overview. *Am J Clin Pathol.* 2006; 125 Suppl: S95-123.
4. Rodriguez I, Ayala E, Caballero C, De Miguel C, Matias-Guiu X, Cubilla AL et al. Solitary fibrous tumor of the thyroid gland: report of seven cases. *Am J Surg Pathol.* 2001; 25(11):1424-1428.
5. Ning S, Song X, Xiang L, Chen Y, Cheng Y, Chen H. Malignant solitary fibrous tumor of the thyroid gland: Report of a case and review of the literature. *Diagn Cytopathol.* 2011; 39(9):694-699.