

## Solitary plasmacytoma of the thumb: A rare case report

Dawood Jafari, MD.<sup>1</sup>, Hamid Taheri, MD.<sup>2</sup>, Hooman Shariatzadeh, MD.<sup>3</sup>  
Farid Najd Mazhar, MD.<sup>4</sup>, Alireza Pahlevansabagh, MD.<sup>5</sup>

*Department of Hand Surgery, Shafa Yahyaian Hospital, Iran University of Medical Sciences, Tehran, Iran*

### Abstract

A solitary plasmacytoma of bone occurs in approximately 2-5% of patients with myeloma. The lesion mostly found in the axial skeleton and have infrequently been reported to arise in the hand, and usually occur in the distal phalanges. We report the interesting case of a 75-year-old man who developed a solitary lytic lesion of the thumb proximal phalanx. This lesion was explored through MR imaging and histologic examination, and then a final diagnosis of plasmacytoma was determined. He was treated with fractionated radiotherapy and no complication was detected with this procedure. The clinical, imaging, and histologic findings of this case are presented here.

### Keywords

plasmacytoma, thumb, proximal phalanx.

### Introduction

The plasma-cell neoplasms are lymphoid neoplastic proliferations of B cells that account for approximately 1-2% of human malignancies [1] and it may classified as multiple myeloma, solitary bony plasmacytoma and peripheral extramedullary plasmacytoma.

The plasmacytoma, was first mentioned in 1891 by Unna and later described by Schridde in 1905 [2]. A solitary plasmacytoma of bone occurs in approximately 2-5% of patients with myeloma [3]. Criteria for solitary plasmacytoma include a histologically confirmed single lesion, a negative skeletal survey, and no evidence of tumor in the bone marrow [1]. Patients with solitary plasmacytoma of bone are usually

male and are in their sixth or seventh decade of life at diagnosis [1]. Solitary plasmacytomas are unpredictable in their behavior; they may remain localized for several years or they may disseminate. Solitary plasmacytomas are most often found in the axial skeleton [4] and these lesions have infrequently been reported to arise in the hand [5]. In the hand these most frequently occur in the distal phalanges [5].

The following case illustrates the presentation and treatment for this unusual tumor affecting proximal phalanx of thumb. In spite of searching through English literature we could not find any case report of solitary plasmacytoma of thumb proximal phalanx.

### Case report

A 75-year-old right-handed farmer man pre-

1. Assistant Professor of Orthopaedic Surgery, Iran University of Medical Sciences, Tehran, Iran.

2. Assistant Professor of Orthopaedic Surgery, Iran University of Medical Sciences, Tehran, Iran.

3. Assistant Professor of Orthopaedic Surgery Iran University of Medical Sciences.

4. Hand Surgery Fellow, Iran University of Medical Sciences, Tehran, Iran

5. **Corresponding author**, Hand Surgery Fellow, Department of Hand Surgery, Shafa Yahyaian Hospital, Baharestan Sq. Tehran, Iran. Tel: +982133542022. Email: pahlevansabagh@yahoo.com

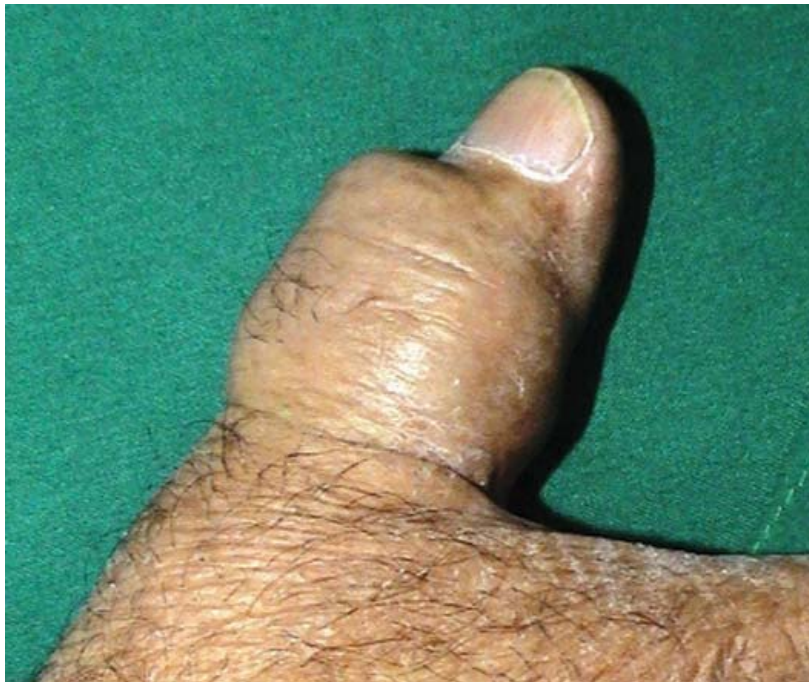

Fig 1. Photography of right thumb, with the lesion.

sented to our department with an enlarging mass on the right thumb. The lesion formed on the dorsal surface of the proximal phalanx, 1 year before the presentation. He had no history of previous trauma or infection. His past medical history consisted a cervical spine fracture, which was treated with spinal fusion 7 years ago. At presentation, the lesion appeared to cover the entire proximal phalanx, which was diffusely swollen (Fig 1). Thus patient had severely limited range of motion for thumb IP joint. The mass was not tender and thumb had normal two point discrimination. There was no alteration in skin or proximal adenopathy. There was no hypercalcaemia or preoperative anaemia and erythrocyte sedimentation rate and C-reactive protein, were within normal limits.

Radiographs showed a completely lytic highly destructive lesion involving proximal phalanx of the thumb with expansion of the underlying bone. There was a large soft tissue mass without calcification on the dorsal aspect of proximal phalanx (Fig. 2).

The MRI study showed a locally aggressive

and destructive lesion, involving proximal phalanx, and was isointense on T1-weighted images and hyperintense on T2-weighted images. The tissue mass was expanded to the IP joint and dorsal aspect of proximal phalanx, nonetheless technetium-99m bone scan showed a single focal area of mild increase uptake at the right

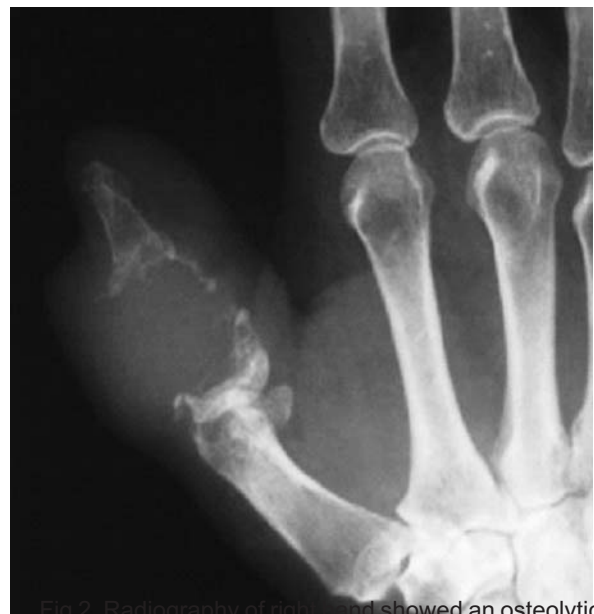

Fig 2. Radiography of right hand showed an osteolytic lesion of thumb proximal phalanx.

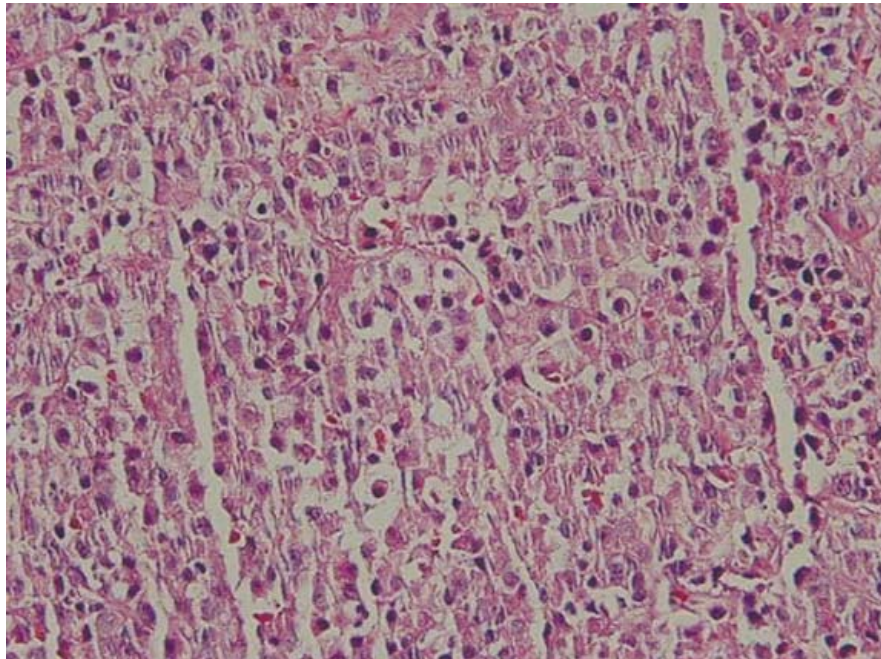


Fig 3. Photomicrographs of this case shows proliferated round cells.

thumb.

An open incisional biopsy under general anesthesia was taken from the mid-lateral aspect of the proximal phalanx. Grossly the lesion was found to be tan-gray in color and soft, and microscopically consisted proliferated round small cells that resemble normal plasma cells with occasional eccentric nucleoli. Binucleated cells were occasionally present (Fig. 3). For definite diagnosis immunohistochemistry examination was performed. Immunohistochemical staining revealed that tumor cells had positive reaction for Lambda light chain and Vimentin and negative reaction for CKAE1/AE3 and Kappa light chain.

Bone-marrow aspiration, electrophoresis and immunoelectrophoresis of the urine and serum were all normal. A skeletal survey showed no abnormality except for the right thumb. A clinicopathological diagnosis of solitary plasmacytoma of bone was made.

He was treated with fractionated radiotherapy, with no complications and the patient had minimal skin changes after radiation. Sixteen weeks after radiotherapy, no changes in imaging was observed. To ensure eradication of the

disease and obviate the need for further radiotherapy, more specimens were obtained from the patient. This consisted of dense fibrotic tissue, with no signs of tumor. We concluded that he was free of disease, hence the patient returned to work soon after the treatment.

To evaluate any progression to multiple myeloma, skeletal surveys and serum immunoelectrophoreses were performed every 3 months, but no evidence of local recurrence or multiple myeloma was found 22 months after the surgery.

### Discussion

Only approximately 3% to 4% of hand and wrist bone tumors are malignant [6]. Considering just 2% to 4% of all bone tumors arise in the hand and wrist [6], malignant bone tumors of the hand and wrist are, therefore, rare. Chondrosarcoma is the most common primary malignant bone tumor that occurs in the hand [3].

In the hand, with its very special structure, high tactile sensitivity, small amount of free space, and mobile bony structures immediately underneath the skin, such lesions are readily diagnosed.

Solitary plasmacytomas are relatively rare malignant bone or soft-tissue tumors consisting of a collection of monoclonal plasma cells [7]. They typically are classified as osseous (solitary plasmacytomas of bone) or nonosseous (extramedullary plasmacytomas) [2]. Generally speaking, the extramedullary plasmacytomas carry a better prognosis than the solitary plasmacytoma of bone [2]. The median age at diagnosis for patients with solitary plasmacytoma of bone is approximately 10 years younger than for patients presenting with multiple myeloma [4]. The average age at presentation for this tumor is 50 to 58 years [4]. The most common mode of relapse of plasmacytoma is progression to multiple myeloma [5]. Bolek et al cited actuarial risks of progression at 5, 10, and 15 years as 40%, 54%, and 100% for bone lesions [8]. The most common localization for a solitary plasmacytoma of bone is the thoracolumbar spine [7]. The proximal phalanx of thumb is an extremely rare localization for lesion and review of the English literature, shows no cases of plasmacytoma arising from thumb proximal phalanx. The differential diagnosis of such lesions should include chondrosarcoma, metastatic tumors, giant cell tumor and vascular tumor. Treatment of both the osseous and extramedullary type of solitary plasmacytoma remains controversial. Surgical resection alone, radiotherapy, or combinations of the two have all been advocated to achieve local control [5]. Because of the importance of the thumb in daily activities and the tumor characteristics, an amputation was not an option for this case.

Because radiotherapy results in various degrees of fibrosis and sclerosis, follow-up computed tomography or MRI studies were not useful for the evaluation of recurrence at the primary site. Therefore a further specimen was taken from the patient sixteen week after radiotherapy.

When a plasmacytoma lesion is encountered, multiple myeloma should always be excluded.

Early recognition may have a dramatic impact on patient morbidity and mortality. Because of the potential for future systemic involvement, patients who are treated for solitary lesions need to be monitored routinely with serial radiographic surveys and serum immunologic evaluation. Our patient had no clinical, immunologic, or radiographic evidence of disease progression at a 22-month follow-up examination.

In conclusion, phalanx solitary plasmacytoma should be considered when formulating the differential diagnosis for a solitary phalanx tumor.

---

## References

1. Bolek TW, Marcus RB, Mendenhall NP: Solitary plasmacytoma of bone and soft tissue. *Int J Radiat Oncol Biol Phys* 36:329-333, 1996.
2. Stuart J, Smith AC. Plasmacytoma of the Superficial Radial Nerve. *J Hand Surg* 2001; 26A:776-780.
3. Dimopoulos MA, Goldstein J, Fuller L, Delasalle K, Alexanian R. Curability of solitary bone plasmacytoma. *J. Clin. Oncol.* 10(4):587-590; 1992.
4. Dimopoulos MA, Moulopoulos A, Delasalle K, Alexanian R. Solitary plasmacytoma of bone and asymptomatic multiple myeloma. *Hematol Oncol Clin North Am* 1992;6:359-69.
5. Templeton KJ, Langford S, Tawfik O, City K. Extramedullary plasmacytoma of the hand: a case report. *J Hand Surg* 2001; 26A:781-785.
6. Campbell DA, Millner PA, Dregghorn CR. Primary bone tumours of the hand and wrist. *J Hand Surg [Br]* 1995;20:5-7.
7. Van Riet RP, Dreessen P. Solitary plasmocytoma of the distal humerus. *J Hand Surg* 2006; 31A:1197-1200.
8. Bolek TW, Marcus RB Jr, Mendenhall NP. Solitary plasmacytoma of bone and soft tissue. *Int J Radiat Oncol Biol Phys* 1996; 36:329 -333.