

ZOSTERIFORM METASTASES IN A MAN WITH MALIGNANT MELANOMA

S. SHAMSADINI, M.D., AND S. DABIRI,* M.D.

*From the Departments of Dermatology and *Pathology, Kerman University of Medical Sciences,
Kerman, I.R. Iran.*

ABSTRACT

Zosteriform metastasis is a rare clinical distribution from spreading neoplasms of every organ to the skin. Tumors most often arise from an internal or hematologic malignancy. We report a 69-year-old man, a known case of malignant melanoma of the left heel. In this case, multiple red-brown metastatic nodules appeared four months after diagnosis. Distribution of metastatic lesions resembled a zosteriform configuration on his left thigh dermatome. Histological findings of a cut section of an excised nodule were compatible with a diagnosis of metastatic malignant melanoma. As we know this case report is the first case of zosteriform distribution of metastatic malignant melanoma that has been reported.

MJIRI, Vol. 16, No. 2, 115-117, 2002.

Keywords: Zosteriform metastases, Malignancy, Malignant melanoma.

INTRODUCTION

Cutaneous metastases of original malignancies in patients are important clues to tumor progression or even the first manifestation of a malignancy. This case report is another case of the type reported by Itin et al. in 1992.¹ In a review of 4020 patients with metastatic carcinoma, cutaneous lesions were found in 10.4%.² Different types of metastatic skin lesions include nodules, ulcerations, inflammatory, sclerotic, bullous and vesicular patterns.³

Carcinoma en cuirasse and metastatic alopecia are uncommon types of skin metastases.² This report describes a patient with malignant melanoma of the left heel and a zosteriform pattern of cutaneous metastases to his ipsilateral thigh and leg.

CASE REPORT

A 69-year-old man had long-standing red violaceous nodular lesions on his left leg and thigh. Examination disclosed many pigmented nodules with zosteriform distribution on the lower left limb with keratotic crust for-

mation (Fig. 1). Excision of one nodule from his thigh with a 1 cm margin was performed, and histological cut smear study showed a nodular type of metastatic malignant melanoma without any dermal lymphatic involvement in perineural tissues (Fig. 2 & 3). Amputation was not done because metastatic malignant melanoma cells were observed in ipsilateral lymph nodes. Chemotherapy was done but was without benefit. Four months later many more red-brown metastatic nodules appeared between them. Lymphadenectomy was performed and the histological findings approved the diagnosis of metastatic melanoma. Tumor infiltration of the lymphatic vessels was observed in the lymph nodes of his groin.

DISCUSSION

Zosteriform cutaneous metastases arise from skin cancers, vascular tumors, hematologic malignancies, and visceral neoplasms.⁴ Malignant melanoma has a high tendency to metastasize to the skin. Lookingbill et al. in 1993 reported that 77 (44.8%) of 172 patients had metastatic melanoma lesions of the skin. Among them, in 28 patients (36%) skin metastases were pigmented, 3 cases were ulcerated and in one case metastatic skin lesions had a zosteriform pattern.^{1,2} In our extensive literature review there was no more than one

Correspondence: S. Shamsadini, Kerman Darman Hospital, Kerman University of Medical Sciences, Kerman, I.R. Iran. Tel: +98 34157272, +98 34158287, E-mail: shamsadini@yahoo.com

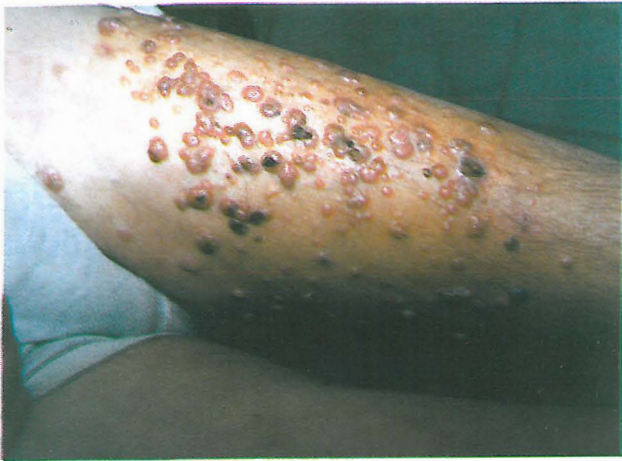

Fig. 1. Zosteriform metastases in a 69-year-old man with malignant melanoma.

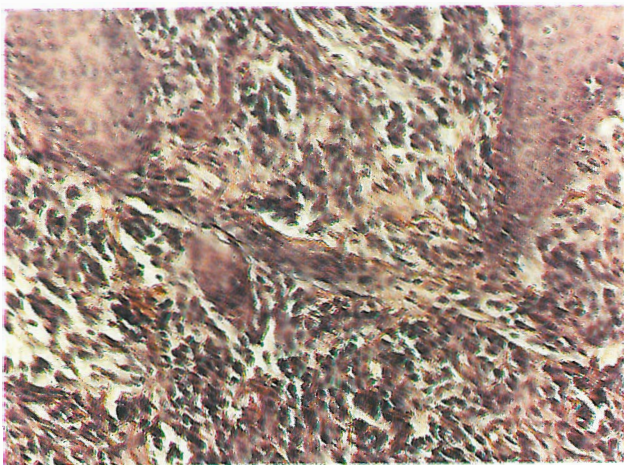


Fig. 2. Light micrograph of a zosteriform metastatic skin nodule of melanoma.

similar case. Several reports have described zosteriform metastases from different malignant tumors, but no more than two cases with malignant melanoma were included in the long list.² Primary malignant melanoma occurring in a speckled zosteriform lentiginous nevus has been documented at least twice.^{5,6} In 1974 McWilliams and Noojin described a patient with vesicular metastatic melanoma at the site of surgical treatment.⁷

The cause of the dermatomal distribution and the zosteriform metastatic pattern in the lower limb are not known. In our case numerous metastatic lesions appeared above the initial site of excision. The process was aggressive in the patient and he died 13 months after excision of the primary lesion. An additional patient with vesiculobullous metastatic lesions (not zosteriform) from melanoma was described by Goldman in 1996.⁸ Although no zosteriform pattern was mentioned in his clinical

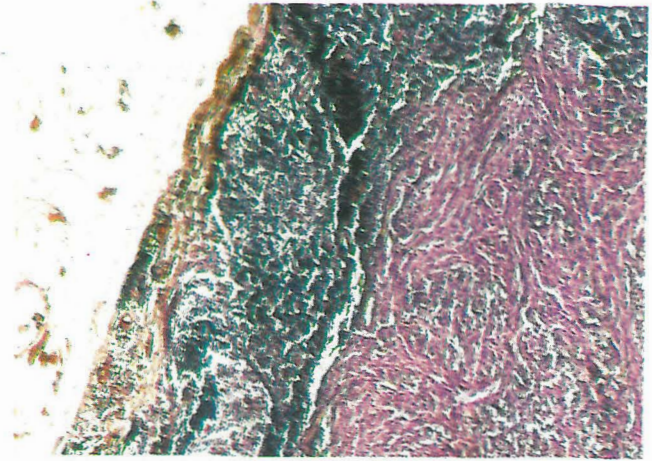


Fig. 3. Light micrograph of a lymph node showing metastatic malignant melanoma.

manifestations, the author described the lesions as being scattered around all margin borders and in the scars along the right thigh and leg. Melanoma erysipeloid, also called inflammatory metastatic melanoma, is another rare variant of metastatic melanoma that has been reported by Haupt et al.⁹ The pathophysiologic background for zosteriform metastasis may be a Koebner-like phenomenon as has been suggested by several descriptions of metastatic lesions in areas of recent herpes zoster infection.^{7,10,11} Metastatic spreading by perineural lymphatic invasion is an additional possibility for explaining a zosteriform pattern.^{4,12,13}

Besides, tumor invasion of dorsal root ganglia with extension peripherally may have an important role.^{4,14,15} Our observation suggests that a zosteriform pattern of metastatic melanoma is a consequence of lymphatic invasion rather than a Koebner-like phenomenon.

REFERENCES

1. Itin PH, Lautenschlager S, Buechner SA: Zosteriform metastases in melanoma. *J Am Acad Dermatol* 1992.
2. Lookingbill DP, Spangler N, Helm KF: Cutaneous metastases in patients with metastatic carcinoma: a retrospective study of 4020 patients. *J Am Acad Dermatol* 29: 228-36, 1993.
3. Brownstein MH, Helwig EB: Spread of tumors to the skin. *Arch Dermatol* 107: 80-6, 1973.
4. Manteaux A, Cohen PR, Rapini PP: Zosteriform and epidermotropic metastases. Report of two cases. *J Dermatol Surg Oncol* 18: 97-100, 1992.
5. Bologna JL: Fatal melanoma arising in a zosteriform speckled lentiginous nevus. *Arch Dermatol* 127: 1240-1, 1991.
6. Stern JB, Haupt HM, Aaronson CM: Malignant melanoma in a speckled zosteriform lentiginous nevus. *Int J Dermatol*

- 29: 583-4, 1990.
7. McWilliams P, Noojin RO: Vesicular metastatic melanoma. *South Med J* 67: 1365-7, 1974.
 8. Goldman L: Melanoma with vesiculobullous metastatic lesions. *Arch Dermatol* 93: 233-4, 1966.
 9. Haupt HM, Hood AF, Cohen MH: Inflammatory melanoma. *J Am Acad Dermatol* 10: 52-5, 1984.
 10. Aberer W, Zonzits E, Soyer HP, et al: Postzosterische spezifische Haut infiltrate bei chronischer lymphatischer Leukämie. *Hautarzt* 41: 455-7, 1990.
 11. Niedt GW, Prioleau PG: Kaposi's sarcoma occurring in a dermatome previously involved by herpes zoster. *J Am Acad Dermatol* 18: 448-51, 1988.
 12. Bluefarb SM, Wallk S, Geeth M: Carcinoma of the prostate with zosteriform cutaneous lesions. *Arch Dermatol* 76: 402-6, 1957.
 13. Hodge SJ, Mackle S, Owen LG: Zosteriform inflammatory metastatic carcinoma. *Int Dermatol* 18: 142-5, 1979.
 14. Jaworsky C, Bergfeld WF: Metastatic transitional cell carcinoma mimicking zoster sine herpette. *Arch Dermatol* 122: 1357-8, 1986.
 15. Matarasso SL, Rosen T: Zosteriform metastasis; case presentation and review of the literature. *J Dermatol Surg Oncol* 14: 77-8, 1988.

