

## Case Report

# MALAKOPLAKIA OF THE COLON: A CASE REPORT AND LITERATURE REVIEW

S.M. ALAVIAN, M.D., F. RAISSI SHABARI M.D., AND  
N. KAMALIAN,\* M.D.

*From the Dept. of Gastroenterology, Baqiatalah Hospital, Baqiatalah University of Medical Sciences, Tehran, and  
the \*Dept. of Pathology, Shariati Hospital, Tehran University of Medical Sciences, Tehran, I.R. Iran.*

### ABSTRACT

Malakoplakia is a rare disease with undefined etiology that has been almost exclusively reported in urology and pathology journals. We are presenting a case of colonic malakoplakia in an 18-year old young man who was referred to us with a four-year history of intermittent rectorrhagia. The pathological examination of the endoscopically resected specimen revealed pathognomonic features of malakoplakia, von Hansemann cells and Michaelis-Gutmann bodies.

*MJIRI, Vol. 15, No. 3, 179-182, 2001.*

**Key Words:** Malakoplakia, colon, colorectal tumors

### INTRODUCTION

Malakoplakia is a rare, chronic, granulomatous inflammatory disease, which was first described by Michaelis and Gutmann in 1902. One year later, von-Hansemann coined the term malakoplakia derived from the Greek "malakos"(soft) and "plakos"(plaque). The macroscopic appearance is usually a yellow or yellowish brown, solid, soft, friable mass of various size and different patterns of distribution, not unlike that of a carcinoma. Histologically, there is diffuse histiocytic infiltration with a strong periodic acid-Schiff (PAS) positive eosinophilic granular cytoplasm (von Hansemann's cells) containing the characteristic basophilic, laminated cytoplasmic inclusions called Michaelis-Gutmann bodies. Originally described in the bladder, malakoplakia is most commonly found in the genitourinary tract. In this article we present the first reported case of malakoplakia in a young adult from Iran and the histologic and endo-

scopic features of the disease, along with a brief review of the literature.

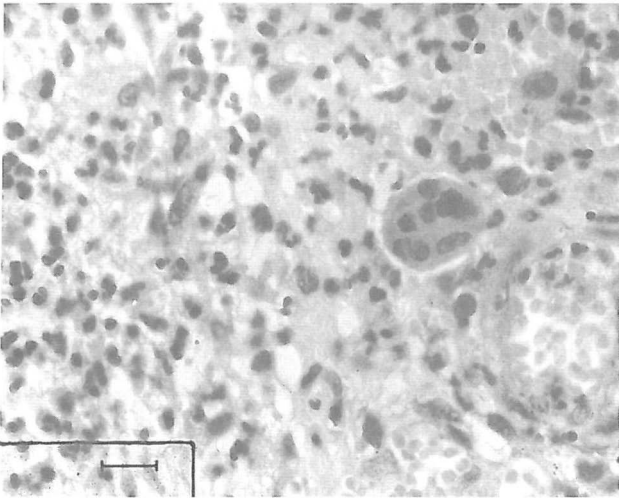
### CASE REPORT

An 18-year old young man was referred to our institution with a 4-year history of intermittent fresh rectal bleeding. He had been symptom-free until four years ago, at which time he developed intermittent painless rectal bleeding without any bowel habit changes. He never had diarrhea, tenesmus, fever, weight loss, anorexia or abdominal pain. There was no significant past medical history but in his family history one of his cousins had a history of colon polypectomy when he was 6-years old. He had no drug abuse. He sought medical advice and with a diagnosis of hemorrhoids, was prescribed anti-hemorrhoid ointment. Seven months ago, because of a sensation of a mass protruding from the anus, the patient underwent rectosigmoidoscopy and eleven polyps of various sizes were resected from the anorectal region. Microscopic examination of the polypoid structures showed diffuse edema, ulceration, and acute and chronic inflammation accompanied with vascular congestion and

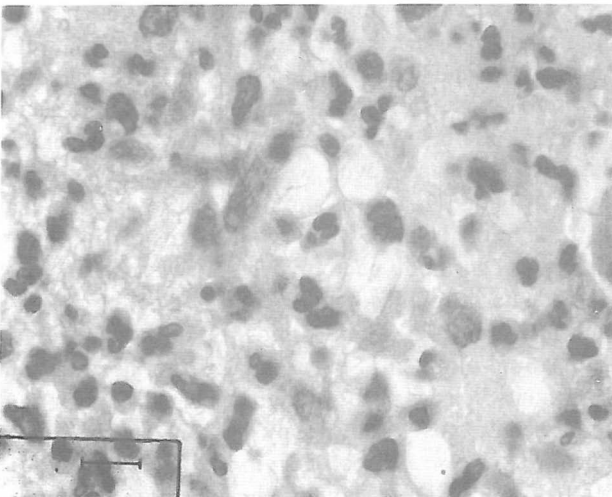
**Correspondence:** S.M. Alavian, Tehran Hepatitis Center, P.O.Box 14155-3651, Tehran, Iran; email: sm\_alavian@alavian-thc.org

## Malakoplakia of the Colon

mucosal gland disruption. The diagnosis was juvenile polyposis. All laboratory tests were normal but occult blood was positive in the stool exam. He was symptom free for three months, at which time rectal bleeding recurred. In endoscopic examination, there were certain ulcerative and yellowish friable polypoid lesions in the anorectal region. Polypectomy was performed via colonoscopy. Microscopic examination of the specimens measuring 20×20 and 10×10 mm revealed fragments of tissue, including granulation tissue (Fig. 1). The tissue was markedly edematous showing infiltrates by lymphomononuclears and plasma cells. They are mixed with plump histiocytes, occasionally multi-nucleated, having abundant cytoplasm. A few histiocytes seem to contain intracytoplasmic PAS-positive inclusion-like



**Fig. 1.** Granulation tissue and colonic mucosa with neutrophils (left side), histiocytes and multinucleated giant cells. (H&E, ×250).



**Fig. 2.** The same field, showing macrophages containing Michaelis-Gutmann bodies (arrowed). (H&E, ×400).

Michaelis-Gutmann bodies (Fig. 2).

### DISCUSSION

Malakoplakia usually involves the genitourinary tract including the kidney, ureter, bladder, urethra, testis, epididymis, prostate, endometrium, vagina or broad ligament.<sup>1,2,3</sup> Nankohl and Chichiurian described the first case outside the urinary tract involving the testis. In the urinary tract hematuria and recurrent urinary tract infection are the most frequent findings. Additionally, obstruction of the urinary or gastrointestinal tract may cause other symptoms. The more extensive lesions can cause tiredness, weight loss, fever, and night sweats. A palpable mass may be found. Other common findings include anemia, leukocytosis, and increased erythrocyte sedimentation rate.<sup>4</sup>

More recently, there has been a growing list of cases reported outside the genitourinary tract including lung, brain, skin, conjunctiva, bone, tonsils, adrenals, breast, abdominal wall, pancreas, liver and all parts of the gastrointestinal tract. Colonic malakoplakia was first described by Turner and Lattes in 1965.<sup>5</sup> McClure made a comprehensive review of the literature in 1983 and reviewed 38 cases involving the entire gastrointestinal tract.<sup>6</sup> Previously a case of colonic malakoplakia has been reported in this Journal in 1989. The clinical manifestations of colonic malakoplakia depend on the extent of involvement and coexisting disease. They are non-specific and include rectal bleeding, diarrhea, abdominal pain, fever, weight loss, night sweats and intestinal tract obstruction.

There are three forms of the disease in endoscopic examination;<sup>3,6,7,8</sup> (1) Isolated sessile or polypoid masses in the rectosigmoid colon; the lumen may be narrowed suggesting a malignant stricture. The inflammatory process may be transmural, resembling Crohn's disease. (2) Diffuse involvement of the entire colon with either polypoid serpiginous lesions or diffuse ulceration. This form is often present in patients with compromised immunity including renal transplant recipients, immunosuppressive drug therapy, and hereditary immunodeficiency. (3) A mass-like lesion occurring alone or in association with cancer of the colon or an adenomatous polyp. The incidence of colon cancer associated with intestinal malakoplakia is as great as 35 percent.<sup>3,6,9</sup>

Commonly associated symptoms of colonic malakoplakia include, fever, diarrhea, and hematochezia in types 1 and 2, and fever with abdominal pain and tenderness in type 3.<sup>6</sup>

### Pathogenesis

Although the etiology and pathogenesis of malakoplakia are still unknown, it is believed that this disease

may have multiple causes. Some authors believe the origin to be infectious, because of consistent finding of *E. coli*, klebsiella, mycobacterium, and staphylococcus. However, considering the frequency of *E. coli* in urinary tract infections and the rarity of malakoplakia, a primary infectious cause seems to be unlikely. Moreover, *E. coli* and other organisms have not been consistently associated with malakoplakia outside the urinary tract. Other authors agree that a diminished capacity of macrophages for lysis of bacteria is the basic defect.<sup>4,9,10,11,12</sup> Some authors emphasize the correlation between immunosuppression and malakoplakia because an increasing number of cases in immunodeficient individuals and in patients receiving aggressive chemotherapy for transplantation has been reported.<sup>4</sup> Furthermore, several malakoplakia cases have been reported in patients with systemic lupus erythematosus, liver disease, mycotic infections, sarcoidosis, ulcerative colitis, cachexia and in drug addicts. In one of the comprehensive studies reported, Abdou et al. found evidence for a monocyte lysosomal abnormality similar to findings in the Chediak-Higashi syndrome.<sup>9</sup> They showed that decreased intracellular concentration of cyclic guanosine monophosphate (cGMP) in the macrophages of one patient with malakoplakia and hypogammaglobulinemia could lead to a decreased fusion of primary lysosomes with phagosomes, resulting in incomplete bacterial killing and the formation of Michaelis-Gutmann bodies. They also found an increase in the intracellular cGMP concentration and bactericidal activity of blood monocytes when the patient was treated with bethanechol. However, Webb et al.<sup>13</sup> did not find diminished cGMP levels in their hypogammaglobulinemic patient with malakoplakia.

Biggar et al.<sup>10</sup> found decreased bacterial killing but normal cyclic adenosine monophosphate (cAMP) and cGMP levels in their patients with malakoplakia. The bactericidal effect did not improve after carbachol treatment. Wener et al.<sup>14</sup> found a decreased cGMP level in their patient who used prednisone due to systemic lupus erythematosus, but incubation with bethanechol did have any effect on it. Both Wener et al. and Curran<sup>15</sup> proposed that a decreased cGMP/cAMP ratio might be more important than lowered cGMP level alone.

Ascorbic acid might be able to correct this ratio, as it increases the cGMP level in normal monocytes<sup>16</sup> and decreases cAMP levels in monocytes of patients with the Chediak-Higashi syndrome.<sup>17</sup> Its effects in malakoplakia have not been totally evaluated. It has also been suggested that malakoplakia may be an expression of microtubular/microfilamentary dysfunction, but this hypothesis was not thoroughly supported by later investigations.<sup>1</sup>

### Pathology and diagnosis

The most distinctive and diagnostic histologic feature of malakoplakia consists of Michaelis-Gutmann bodies, which are concentrically laminated, round or oval, dark inclusion bodies, 5 to 10 mm in diameter, located in the cytoplasm of histiocytes known as von Hansemann cells. These inclusions are generally PAS- and von Kossa stain positive (MM), are composed of a glycolipid matrix, probably from a specific micro-organism, and are coated by a layer of calcium and iron. So, diagnosis can be made only by histologic examination of endoscopic biopsy specimens or fine-needle aspiration. Barium enema radiography, CT scan, scintigraphy, and transrectal ultrasonography are helpful in estimation of the spread of disease to surrounding areas.<sup>6</sup>

### Treatment

The rarity of malakoplakia and the coexistence of serious diseases such as cancer, as well as treatment with immunosuppressive drugs or a severe underlying immunologic dysfunction, make difficult any evaluation of reported treatments. However, surgical excision or incision and drainage are the treatment of choice. In patients unfit for surgery, discontinuation of immunosuppressive drugs, if possible, and administration of bethanechol or antimicrobial drugs with intracellular penetration, such as trimethoprim-sulfamethoxazole, rifampicin, or ciprofloxacin can be attempted. Bethanechol, a cholinergic agonist, is considered to raise intracellular levels of cGMP in macrophages. Ascorbic acid, with the same suggested mechanism of action, is also recommended but further conclusions need more thorough investigations.<sup>4</sup>

### REFERENCES

1. McClure J: Malakoplakia. *J Pathol* 140:275-330. 1983.
2. Long JP Jr, Althausen AF: Malakoplakia: a 25-year experience with a review of the literature. *J Urol* 141:1328-31. 1989.
3. Stanton MJ, Maxted W: Malakoplakia: a study of the literature and current concepts of pathogenesis, diagnosis and treatment. *J Urol* 125:139-46. 1981.
4. Van der Voort HJ, ten Velden JA, Wassenaar RP, Silberbusch J: Malakoplakia. Two case reports and a comparison of treatment modalities based on a literature review. *Arch Intern Med* 156:577-83. 1996.
5. Terner JY, Lattes R: Malakoplakia of colon and retroperitoneum. *Am J Clin Pathol* 44:20. 1965.
6. McClure J: Malakoplakia of the gastrointestinal tract. *Postgrad Med J* 57:95-103. 1981.
7. Sansui ID, Tio FO: Gastrointestinal malakoplakia. Report of a case and a review of the literature. *Am J Gastroenterol* 62:356-66. 1974.

## Malakoplakia of the Colon

8. Hayden AJ, Hardy DC, Jackson DE Jr: Malakoplakia of the colon. *Mil Med* 151:567-9, 1986.
9. Abdou NI, NaPombejara C, Sagawa A, Ragland C, et al: Malakoplakia: evidence for monocyte lysosomal abnormality correctable by cholinergic agonist *in vitro* and *in vivo*. *N Engl J Med* 297:1413-9, 1977.
10. Biggar WD, Crawford L, Cardella C, Bear RA, et al: Malakoplakia and immunosuppressive therapy. Reversal of clinical and leukocyte abnormalities after withdrawal of prednisone and azathioprine. *Am J Pathol* 119:5-11, 1985.
11. Schreiber AG, Maderazo EG: Leukocytic function in malakoplakia. *Arch Pathol Lab Med* 102:534-7, 1978.
12. Thorning D, Vracko R: Malakoplakia. Defect in digestion of phagocytized material due to impaired vacuolar acidification? *Arch Pathol* 99:456-60, 1975.
13. Webb M, Pincott JR, Marshall WC, Spitz L, et al: Hypogammaglobulinaemia and malakoplakia: response to bethanechol. *Eur J Pediatr* 145:297-302, 1986.
14. Wener MH, Ramsey PG, Hill HR, Striker L, et al: Renal malakoplakia in a patient with systemic lupus erythematosus. *Arthritis Rheum* 27:704-7, 1984.
15. Curran FT: Malakoplakia of the bladder. *Br J Urol* 59:559-63, 1987.
16. Sandler JA, Gallin JI, Vaughan M: Effect of serotonin, carbamylcholine, and ascorbic acid on leukocyte cyclic GMP and chemotaxis. *J Cell Biol* 67:480-484, 1975.
17. Boxer LA, Watanabe AM, Rister M, Besch HR, et al: Improvement of leukocyte function in Chediak-Higashi syndrome by ascorbate. *N Eng J Med* 295:1041-1045, 1976.
18. Forootan H: Primary malakoplakia of colon: a case report. *MJIRI* 3:175-177, 1989.