

PRIMARY PANCREATIC LYMPHOMA: A CASE REPORT AND LITERATURE REVIEW

H. FOROOTAN, F. MANSOUR GHANAIE,* AND H. GHOFRANI

*From the Department of Gastroenterology, Tehran University of Medical Sciences, Tehran, and the
*Department of Gastroenterology, Gastrointestinal & Liver Disease Research Center (GLDRC), Guilan
University of Medical Sciences, Rasht, I.R. Iran.*

ABSTRACT

Primary pancreatic lymphoma is a rare extranodal manifestation of any histopathologic subtype of B cell non-Hodgkin's lymphoma that predominantly involves the pancreas. It comprises less than 0.2% of pancreatic malignancies and less than 0.7% of non-Hodgkin's lymphomas. This lymphoma is almost never suspected clinically. It is usually diagnosed by surgical exploration for suspected adenocarcinoma because this kind of lymphoma resembles pancreatic adenocarcinoma, a much more common disease, in clinical presentation and radiologic appearance. Differentiation is, however, essential because of different clinical management and outcome. This report describes an interesting case of primary pancreatic lymphoma and review of the literature to elucidate features that suggest this entity.

MJIRI, Vol. 15, No. 2, 117-121, 2001.

Keywords: Pancreas, Pancreatic lymphoma, B-cell lymphoma, Pancreatic mass, Chemotherapy

INTRODUCTION

Primary pancreatic lymphoma is a rare but treatable malignancy that may present as an isolated pancreatic mass. It may be confused with pancreatic adenocarcinoma.¹

Diagnostic criteria of primary pancreatic lymphoma include a pancreatic mass that predominates with gross involvement of only the peri-pancreatic lymph nodes, no hepatic or splenic involvement, no palpable superficial lymphadenopathy, no enlargement of mediastinal lymph nodes on chest radiography and a normal leukocyte count.²⁻⁵

The pancreas can be involved in up to one-third of patients with non-Hodgkin's lymphoma. However, primary lymphoma of the pancreas is rare and accounts for fewer than 1% of extranodal non-Hodgkin's lymphoma.³

The incidence increases to 5% in HIV patients because the GI tract is the most commonly affected extranodal site in AIDS-related non-Hodgkin's lymphoma.¹⁰

Differentiation from pancreatic adenocarcinoma is important preoperatively because clinically most patients

with pancreatic lymphomas present with signs and symptoms identical to those with adenocarcinoma.³

The data in the English literature show no significant difference regarding patient age or duration of symptoms between patients with non-Hodgkin's lymphoma primarily involving the pancreas and patients with pancreatic adenocarcinoma.¹⁰⁻¹⁴

Imaging plays a key role in the diagnosis and staging of pancreatic masses. Lymphoma certainly falls into this group of diseases.¹⁰ Percutaneous or endosonographic or even laparotomic core biopsy should be performed to establish the diagnosis.¹⁻¹⁰

Chemotherapy is the treatment of choice for most patients with pancreatic lymphoma.¹ However, surgical resection may play a beneficial role in the treatment of localized (stage 1 and early stage 2) pancreatic lymphoma.⁸

CASE REPORT

History and findings

A 55 year-old previously healthy woman was admitted to our hospital because of a 1 year history of epigas-

Primary Pancreatic Lymphoma

tric pain, recent anorexia and early satiety with 5-6 kg weight loss.

Epigastric pain did not respond to treatment with H₂ receptor blockers or proton pump inhibitors. There was a history of constipation from 3 months ago. There was no history of melena, hematochezia, pancreatitis, liver or gallbladder disease.

On admission, she had a temperature of 37.6°C, pulse rate of 90 beats per minute and blood pressure of 145/80 mmHg.

Physical examination revealed an ill-defined mass with soft consistency which was palpable in the epigastric area. She had minimal ascites. She didn't have jaundice. The rest of the exam was unremarkable.

Investigations

The hemoglobin was 11 g/dL. There were 9500 leucocytes/mm³ with a normal differential. The liver function tests and the serum amylase level were normal.

Computerized tomography (CT) of the abdomen showed a large para-aortic mass with heterogenous, mixed enhancement and encasement of great vessels. Ascites was seen (Fig. 1). ERCP was unsuccessful due to anatomical abnormality and extrinsic compression on the descending duodenum.

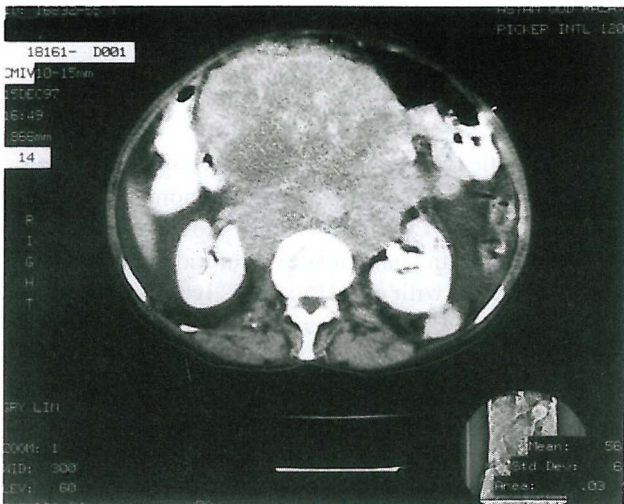


Fig. 1. Abdominal CT scan showing ascites and a large para-aortic heterogeneous mass with encasement of the aorta and right renal vein.

The diagnosis of pancreatic adenocarcinoma was strongly suspected. Operation was performed and an isolated large mass with pancreatic origin and vessel involvement was revealed at surgery. Regional lymph nodes were involved. Surgical tumor debulking was performed.

Pathological examination of the resected tumor in the pancreas showed diffuse mixed cellularity non-cleaved

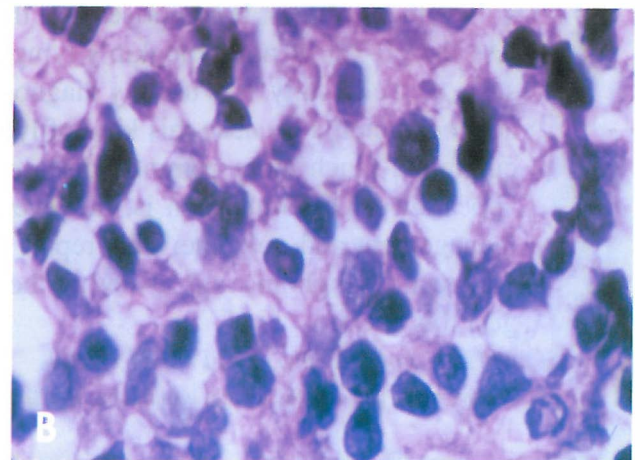
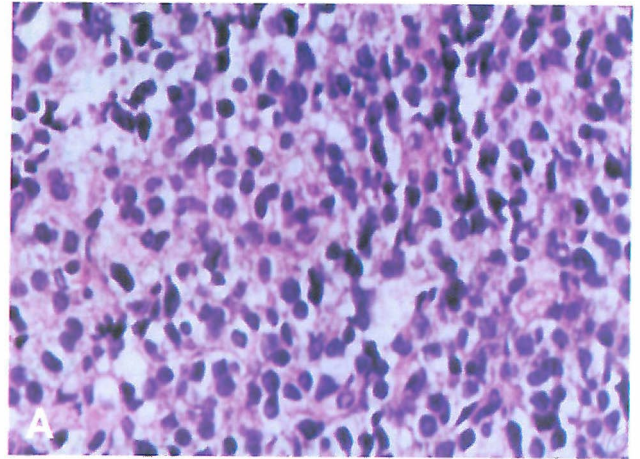


Fig. 2. Diffuse, mixed cellularity, non-cleaved malignant lymphoma with relatively round cells, cytoplasmic border and hyperchromic nuclei with dense chromatin.

type non-Hodgkin's lymphoma (Fig. 2).

The diagnosis of pancreatic lymphoma was established by immunohistochemical study.

Bone marrow biopsy and aspiration showed a reactive bone marrow and non focal lesion or atypical lymphoid aggregate. Liver biopsy was normal. She received chemotherapy with cyclophosphamide, vincristine, doxorubicin, and prednisolone with symptomatic improvement. She was in complete remission during 24 months of follow up.

DISCUSSION

Primary neoplasms of the pancreas are most often adenocarcinomas. Non-Hodgkin's lymphoma involving the pancreas is less common but well documented.¹⁴ The majority of patients with pancreatic cancer, whether ad-

enocarcinoma or lymphoma, present with a mass in the head of the gland. Pancreatic lymphoma is often described as a large homogeneous mass with extra-pancreatic extension, with or without associated lymphadenopathy. Less common presentations are masses in the body or tail, or more rarely diffuse involvement of the pancreas.⁹

Non-Hodgkin's lymphoma is not commonly a familial condition. In the literature only one report of familial pancreatic lymphoma was available which is believed to be the first two cases of primary pancreatic lymphoma within a single family.¹²

Although the clinical presentation of primary pancreatic lymphoma is non-specific, some findings may strengthen the clinical suspicion of lymphoma rather than pancreatic cancer. The most common findings were abdominal pain and weight loss. Classic symptoms of nodal non-Hodgkin's lymphoma, i.e., fever, chills, and night sweats were found in only 2% of patients with primary or predominant pancreatic involvement.¹⁰ Fever, chills and night sweats were not present in our case, but abdominal pain and weight loss were present.

Fortunately jaundice is an infrequent finding, despite large lymphomatous masses involving the pancreatic head.⁷ It was not present in our case.

Only the clinical presentation of abdominal pain and a palpable mass without jaundice was found to be valuable in attempting to distinguish most patients with pancreatic adenocarcinoma from those in the minority with lymphoma.²

Untreated pancreatic lymphomas do not contain calcifications, therefore radiographs of the abdomen are of little value.¹⁰

Only a single case using endoscopic sonography in a patient with primary pancreatic lymphoma was reported in the current literature. Flamenbaum et al.¹³ described the typical endoscopic sonographic findings of a strongly hypoechogenic appearance in the pancreas, hypertrophy in all its segments, a hyperechoic wall in the common pancreatic duct contrasting with the adjacent parenchyma, and multiple isoechogenic peripancreatic lymph nodes. These authors concluded that the endoscopic sonography findings were highly specific and allowed distinction of lymphoma from all other pancreatic tumors.¹³ CT scan is by far the most common imaging technique used in the detection and characterization of primary pancreatic lymphoma. On CT scan, two different morphologic patterns of pancreatic involvement are seen: 1) a localized, well-circumscribed tumoral form, and 2) diffuse tumoral enlargement infiltrating or replacing most of the pancreatic gland. The diffuse infiltrating pattern may mimic the imaging findings of acute pancreatitis.¹⁰

The combination of a bulky localized tumor in the pancreatic head without significant dilatation of the main

pancreatic duct strengthens the diagnosis of pancreatic lymphoma over adenocarcinoma. Furthermore, if enlarged lymph nodes are encountered below the level of the renal veins, virtual exclusion of adenocarcinoma is possible. A bulky homogeneous tumoral mass without alteration of Wirsung's duct or the peripancreatic vessels should suggest the diagnosis. In patients with diffuse infiltration of the pancreatic gland without clinical signs of pancreatitis, the radiologist should be alert to the possibility of pancreatic lymphoma.⁴⁻¹⁰

Primary pancreatic lymphoma has been extensively reviewed in two occasions.^{8,11} In one survey Cappell et al.¹¹ reported a 66-year-old man with primary pancreatic lymphoma and reviewed 12 cases of this disease.

This review of the 12 histologically confirmed reports of lymphoma predominantly involving the pancreas shows that this lymphoma presents clinically like pancreatic carcinoma but has different features. Like pancreatic adenocarcinoma, this kind of lymphoma primarily affects older patients. About half were male. The duration of symptoms prior to admission was usually six weeks or less with this kind of lymphoma, but averaged four months for pancreatic adenocarcinoma. Symptoms and signs of this kind of lymphoma frequently included upper abdominal pain, nausea or vomiting, weight loss, jaundice, an abdominal mass, and abdominal tenderness. These symptoms and signs also commonly occurred with pancreatic adenocarcinoma. This kind of lymphoma produced a mass in the head of the pancreas in nine of 12 patients. Four patients appeared to have localized involvement, and eight had bile duct, intra-abdominal lymph node, or duodenal involvement. Three of seven patients with lymphoma predominantly involving the pancreas who received chemotherapy showed clinical improvement and a reduction in tumor size with three months to one year of follow-up.

In a second extensive survey on pancreatic lymphoma, Koniaris et al.⁸ from the Johns Hopkins hospital presented 8 cases of stage 1 or 2 of primary pancreatic lymphoma and by searching the literature, they collected 122 cases with this disease altogether. They also worked on the role of surgical resection in the treatment of patients with localized disease.

In this extensive review, pancreatic lymphoma, like most extralymphatic lymphomas, is predominantly of intermediate to high-grade histology with diffuse large cell being the predominant type (60%). Less than 20% of reported patients demonstrated low grade histology. The patient population was 67% male, with an average age of 57 years. Forty percent of patients were older than 60 years, and less than 15% of reported patients were in Ann Arbor stage 4. The most common symptom of pancreatic lymphoma, epigastric pain, was seen in 75% of the patients reported in this series and 63% of the pa-

Primary Pancreatic Lymphoma

tients described in the English language literature. Obstructive jaundice was observed in 63% of the patients seen in this series and in 48% of patients among English language reports. Double-contrast enhanced spiral CT is the imaging modality of choice and demonstrates the presence of a pancreatic mass in virtually all patients. Although certain serum abnormality and CT changes are suggestive of lymphoma, tissue is essential for diagnosis. Patients presenting with advanced disease may be diagnosed by peripheral lymph node fine-needle aspiration (FNA), core, or open biopsy.

With regionally confined disease, CT or ultrasonography and recently, endoscopic ultrasonography, guided biopsy techniques usually can provide a diagnostic tissue sample. 58 cases in this survey represented stage 1 or 2 of lymphoma which were treated without surgical resection with a 46% cure rate. Fifteen patients who had surgical resection for localized disease have been reported with a 94% cure rate. Tumor size was larger in the nonoperatively treated group (8 cm versus 6 cm in the resected group). This retrospective analysis and comparison of surgically treated patients to non-operatively treated stage 1 or 2 of pancreatic lymphoma patients treated over a similar period demonstrates markedly improved complete remission and cure rates in the surgically treated group. A suggested treatment protocol is available in this review.⁸ Preoperative CT scan or MRI should be obtained in all patients. It is suggested that a resectable solid pancreatic mass, whether or not it could be lymphoma, should be resected in a hospital equipped with the technical challenges and experienced in post-operative care of such patients. Preoperative biopsy is unnecessary in the presence of clearly resectable disease, because treatment would be unchanged. If a question to the surgical resectability exists, preoperative FNA or a frozen section at operation should be considered.

In all surgical patients placement of titanium clips around the margins of the tumor bed to facilitate post-operative radiotherapy of residual disease is essential. A neoadjuvant approach, where surgery follows chemotherapy, may also be considered, but to date no data exist as to its potential efficacy. In the presence of unresectable disease, especially involving multiple organs, percutaneous FNA biopsy should be obtained and the patient should be treated nonoperatively. Chemotherapy should be used after surgical resection in all cases of intermediate and high grade lymphoma.

Our patient has some differences with patients reviewed or reported by others. The presence of ascites in our patient is a rare finding in general and was reported only in one case.¹ This case was among seven patients who were reported in 1993 and only this patient (among a total number of seven) had ascites. It seems the presence of ascites in our case reflects late diagnosis.

The duration of symptoms prior to admission in different surveys was 6 weeks or less, whereas this period for our patient was nearly one year.

Because of high extension of disease in our patient, she was treated by surgical tumor debulking.

In one report, Behrns and associates,⁵ have suggested that nonresectable pancreatic lymphomas may benefit from a 95% tumor debulking which decreases the tumor burden, followed by chemotherapeutic regimens.

Having resected the tumor in our patient surgically, we treated her with a chemotherapy regimen consisting of cyclophosphamide, vincristine, adriamycin and prednisolone (CHOP protocol). 24 months of follow-up showed no tumor recurrence in our patient. It seems that surgical tumor debulking followed by chemotherapy in nonresectable pancreatic lymphoma increases patient survival rates.

REFERENCES

1. Tucheck JM, De-Jong SA, Pickleman J: Diagnosis, surgical intervention, and prognosis of primary pancreatic lymphoma. *American Surgery* 59(8): 513-518, 1993.
2. Bouvet M, Staerkel GA, Spitz FR, et al: Primary pancreatic lymphoma. *Surgery* 123(4): 382-390, 1998.
3. Goldschmiedt M, Gutta K: Other tumors and diseases of the pancreas. In: Feldman M, Scharschmidt BF, Sleisenger MH, (eds). *Gastrointestinal and Liver Diseases*. 6th ed., Philadelphia: W.B. Saunders Co., pp. 898-899, 1998.
4. Teefey SA, Stephens DH: CT appearance of primary pancreatic lymphoma. *Gastrointestinal Radiology* 11(1): 41-43, 1986.
5. Behrns KE, Sarr MG, Strickler JG: Pancreatic lymphoma: is it a surgical disease? *Pancreas* 9(9): 662-667, 1992.
6. Borrowdale R, Strong RW: Primary lymphoma of the pancreas. *Aust NZJ Surgery* 64: 446-449, 1994.
7. Ezzat A, Jamshed A, Khafaga Y, et al: Primary pancreatic non-Hodgkin's lymphoma. *J Clin Gastroenterol* 23(2): 109-112, 1996.
8. Koniaris LG, Lillemoe KD, Yeo CJ, Abrams RA, et al: Is there a role for surgical resection in the treatment of early stage pancreatic lymphoma? *J Am Coll Surg* 190(3): 319-330, 2000.
9. Salvatore JR, Cooper B, Shah I, et al: Primary pancreatic lymphoma: a case report, literature review, and proposal for nomenclature. *Med Oncol* 17(3): 237-47, 2000.
10. Merkle EM, Bender GN, Brambs HJ: Imaging findings in pancreatic lymphoma: differential aspects. *Am J Roentgenol* 174(3): 671-675, 2000.
11. Cappell MS, Yao F, Cho KC: Lymphoma predominantly involving the pancreas. *Dig Dis Sci* 34: 942-947, 1989.
12. James JA, Milligan DW, Morgan GJ, Crocker J: Familial pancreatic lymphoma. *J Clin Pathol* 51(1): 80-83, 1998.
13. Flamenbaum M, Pujol B, Souquet JC, Cassan P: Endo-

H. Forootan, F. Mansour Ghanaie, and H. Ghofrani

scopic ultrasonography of a pancreatic lymphoma (letter).
Endoscopy 30: 43, 1998.

14. Freeman C, Berg JW, Cutler SJ: Occurrence and prognosis of extranodal lymphomas. Cancer 29: 252-260, 1972.



In the name of God
CALL FOR ABSTRACTS
8th Razi (Rhazes) Medical Sciences Research Awards
December, 2002



Relying upon the assistance of the Almighty God, the 8th Razi Medical Sciences Research Awards is to be held on December, 2002 in the following five sections:

1. Papers published in peer reviewed Iranian and foreign scientific journals.
2. Student theses from Iranian universities published in any scientific journal.
3. Innovations and inventions.
4. Medical research centers.
5. Scientific-research journals approved by the Publications Committee of the Ministry of Health and Medical Education.

Eligibility for participation

1. To submit a copy of the published paper along with the project report.
2. To submit a copy of the student's thesis along with the related paper(s).
3. To submit issues of the scientific journals published from March 20, 2001 to April 2002.
4. To submit the related application for the Research Centers Section.
5. A full description concerning inventions/innovations along with the invention registration certificate.

Notes

- Submitted papers will be assessed among specialized medical fields of basic, clinical, pharmaceutical, nutrition, health, dentistry, rehabilitation and medical equipment sciences.
- Papers must have been published recently (March 2000 or afterwards).
- The students section includes individuals introduced by the deputy of research affairs of their universities, (medical sciences universities can present up to 3 students).
- The theses must be fulfilled later than March 2000.
- Applicants holding BS degree or above from Iran who have graduated later than September 2000 can participate in the festival.
- Research Centers are introduced by deputy research affairs of medical science universities. So, the related form should be filled out and submitted along with other documents.
- The documents shall not be returned to the applicants.
- Acceptance proof of papers will not suffice.

Further information is available for interested applicants at the secretariat of Razi Awards, National Research Center of Medical Science, deputy of research affairs of medical sciences universities or at <http://nrcms.org>

**Deadline for submission of documents:
September 27, 2002**

Correspondent Address:

National Research Center of Medical Sciences
First Flr., No. 26, 1st Al., Kooh-e-Noor St., Motahhari Ave. Tehran, Iran,
Zip Code: 1587656811
Tel: (+98-21) 8501403-6
Telfax: (+98-21) 8501408
E-Mail: razi@nrcms.org