

PREVENTIVE EFFECTS OF VITAMIN B₁₂ AND FOLIC ACID IN METHANOL-INDUCED RETINOPATHY IN AN ANIMAL MODEL

H.A. SHAHRIARI, M.D., AND A. HOSSEINI RAD, M.D.

From Zahedan University of Medical Sciences, Dr. Shariati Ave, Zahedan, 98134, I.R. Iran.

ABSTRACT

In order to identify the effects of vitamin B₁₂ and folic acid in reducing methanol-induced retinopathy, ERG waves were compared before and after methanol intoxication in rabbits. In this study 34 rabbits were divided into 4 groups. All groups received 4 g/kg of methanol intraperitoneally. In addition, the second, third and fourth groups received vitamin B₁₂ injection, oral folic acid and a mixture of vitamin B₁₂ and folic acid, respectively.

Baseline ERGs were recorded for all rabbits prior to intoxication and then second ERGs were taken 48-72 hours following methanol toxicity. Compared to baseline ERGs, a severe reduction in the b-wave amplitude as well as reduction in the oscillatory potential were noticed. Among all groups, the first group had the most and the fourth group had the least decrease in b-wave amplitude as well as oscillatory potential. It is therefore believed that vitamin B₁₂ has a synergistic effect with folic acid in attenuating ophthalmic toxicity of methanol in rabbits. Further studies are needed to evaluate these effects in humans.

MJIRI, Vol. 14, No. 1, 83-86, 2000

INTRODUCTION

Methanol is absorbed through the skin, respiratory system and GI tract.¹ Acute toxicity can occur with ingestion of 10-15 cc of methanol.¹⁶ Following acute methanol intoxication a severe metabolic acidosis can occur due to the accumulation of toxic metabolites, especially formic acid.³ Neurologic problems can occur with formic acidemia, progressing variably to stupor, coma and death. Visual disturbances including cloudiness of vision, decreased visual acuity, central, cecentral and paracentral scotoma occur within 18-48 hours following methanol toxicity.¹⁷

Fundus findings are present in the vast majority of patients with symptomatic loss of vision. Edema of the disc is the first finding. In some severely affected patients, optic atrophy and excavation become apparent in 1 to 2 months.¹⁸

Histopathologic findings in the eyes of patients dying of methanol intoxication are attributed to retinal injury from methanol itself, from one of its metabolites (such as formaldehyde) or from the acidosis.¹⁵

Electrophysiologic findings in humans in most studies have shown reduction in the ERG b-wave amplitude, as well as in the oscillatory potential.⁷ ERG a-wave amplitude could be either accentuated or reduced.^{8,9} The mainstay of therapy is alkalization of plasma using intravenous sodium bicarbonate solution. Ethanol and folic acid could also be used in an effort to counter the toxic effects of methanol.¹⁰⁻¹² This study attempts to show the effects of vitamin B₁₂ and folic acid in reducing methanol-induced retinopathy by comparing the ERG waves before and after methanol intoxication in rabbits.

MATERIAL AND METHODS

In this experimental study white albino Dutch rabbits from both sexes were used. These rabbits were purchased from Razi Institute, Tehran. They were small-size rabbits weighing between 800-1200 grams. All animals were supplied with food and water *ad libitum* and maintained on a 12-hour light-dark schedule in a temperature and humidity-controlled environment. All rabbits had a complete ophthalmic examination including slit-lamp and indirect ophthalmoscopy. Those rabbits who had any apparent ocular problem were eliminated from the experiment. Baseline ERG measurements were recorded from all rabbits at the beginning of the experiment. For the ERG recording, a circular wire electrode was manually applied to the rabbit cornea with contact lens and methyl cellulose and electrodes were affixed to the right and left ears respectively. Binocular single flash recordings were affixed to the right and left ears respectively. Binocular single flash recordings were obtained after dark adaptation of the animals for 30 minutes. The responses to 10 unfiltered white light stimuli were recorded and electronically averaged. We divided 34 rabbits into 4 groups randomly. All rabbits received 4g/kg methanol intraperitoneally. The first group which included 10 rabbits was used as control and received methanol only. The remaining groups which had 8 rabbits each, received additional medication which included 1000 micrograms (intramuscular injection) of vitamin B₁₂ for the second group, 1 mg oral folic acid for the third, and a mixture of both medications (vitamin B₁₂ and folic acid) for the fourth group. A second ERG measurement was recorded for all rabbits 48-72 hours after medications.

ERG changes, especially b-wave amplitude and oscillatory potential, as well as maximum response (the distance between trough of a-wave to the peak of b-wave), were the significant parameters in this experiment. The ERG parameters used in our calculation were the average taken from the ERG of both eyes of each animal.

Figs. 1-4 show representative ERGs from all four groups. All ERG recordings were performed by the same operator in the same room and by a Gansfield Epic 2000 device. There were 5 electrodes: the two corneals were jet type, two were attached to the ears and the fifth one to the forehead over the nose of the rabbits. After shaving the area for a good adhesion, methyl-cellulose gel was employed for a firm contact with the skin.

RESULTS

For each group of animals a mean was calculated for the difference in indicated parameters before and after medication. In this study a confidence interval of 99% was accepted for the mean values of each group. Overlap of the confidence intervals of different groups indicates the

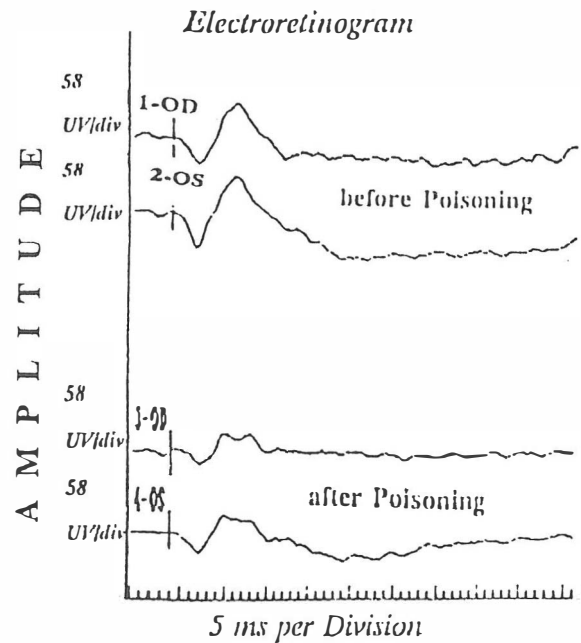


Fig. 1. Dark adapted single flash ERG: Group 1.

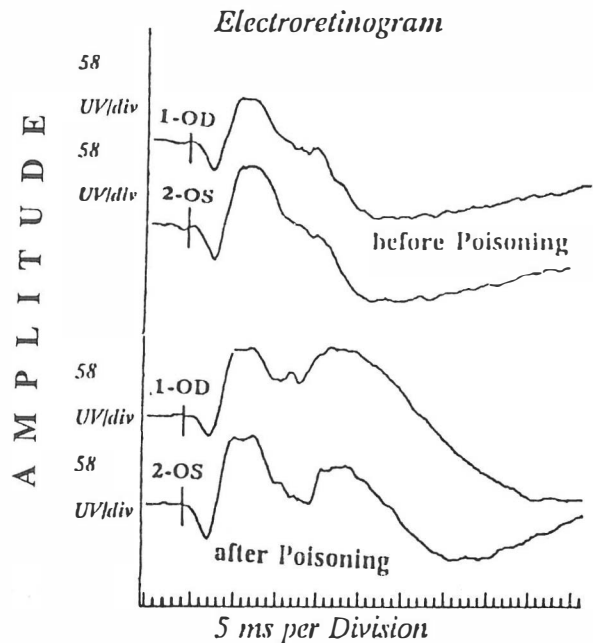


Fig. 2. Dark adapted single flash ERG: Group 2.

similarity between the results and the mean values of the different modalities.

Evaluation of oscillatory potential amplitude

The mean difference for the O.P. values in the first group (X1) was 19.25 microvolts and the standard error (SE1) was 1.975 with a confidence interval of 99%. For the second, third and fourth groups O.P. values were between (2.32-9.81 microvolts), (9.24-12.51 microvolts), and (0.83-9.55

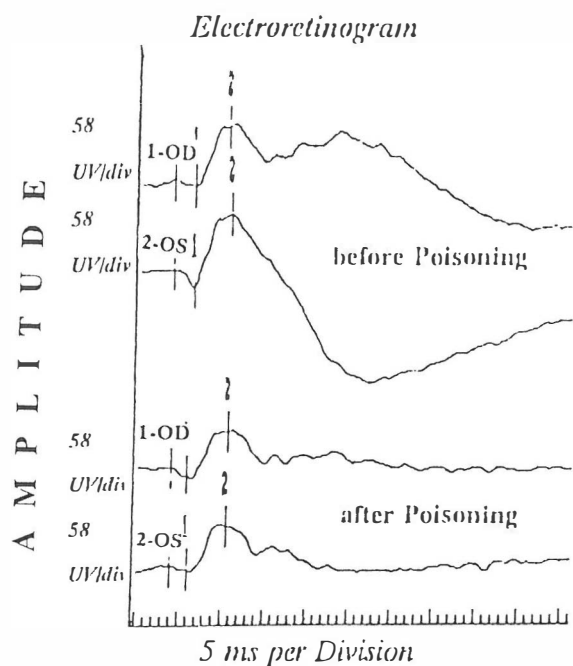


Fig. 3. Dark adapted single flash ERG: Group 3.

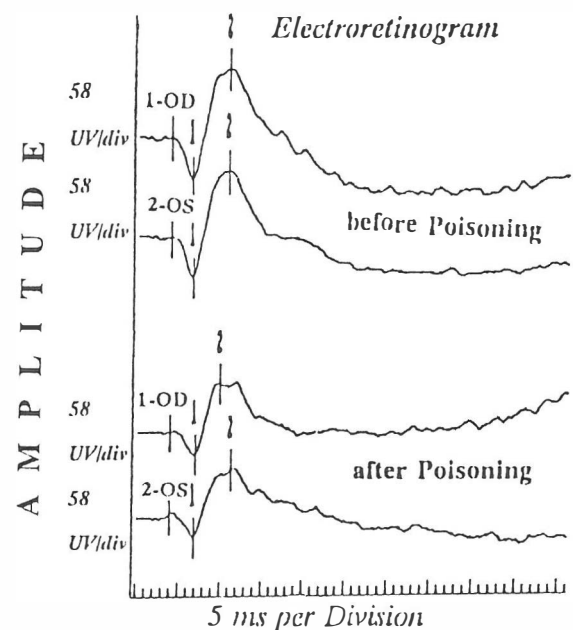


Fig. 4. Dark adapted single flash ERG: Group 4.

microvolts) respectively. Because there is no overlapping of the results between the first and the other three groups, this indicates that the different treatment modalities have statistically significant differences.

Evaluation of the difference between a and b-wave amplitude (maximum response)

The mean differences for all groups were X1=112.3, X2=53.25, X3=44.75 and X4=49.75 microvolts.

The standard errors were SE1=12.746, SE2=16.482,

SE3=23.712 and SE4=16.272. The confidence interval of 99% for the first group lies between 99.2-125.4 which does not overlap with the other three groups, indicating a statistically significant difference between the first group and the others.

Evaluation of b-wave amplitude

The mean value and the standard error for the first group was X1=88.55 microvolts and SE1=14.582, respectively. Comparison of the confidence interval of 99% for the first group which is 73.56-103.36 with the other three groups indicates that there is no overlap between the first group and the others, therefore there are significant statistical differences between the first group and the other three groups.

Evaluation of a-wave amplitude

A confidence interval of 99% for the mean value of the first group (control) did not show a statistically significant difference with the others. These results are similar to those previously reported in the literature. This indicates that a-wave has not been shown to be a reliable parameter in the study of methanol-induced toxicity.

Oscillatory potential amplitude for the first group was measured before and after medication. The amount of decrease in the oscillatory potential amplitude was calculated as a percentage and the mean difference was obtained. These were X1=63.29%, X2=22.8%, X3=35.1 and X4=20.7% for the four groups.

The least amount of decrease was noted in the fourth group which were recipients of a combination of folic acid and vitamin B₁₂. The mean values for the percent decrease in the b-wave amplitude were X1=51.2%, X2=28.73%, X3=34.95% and X4=25.3% for the four groups. The least amount of decrease was noted in the fourth group. The mean values for the percent decrease in the maximum response amplitude were X1=56.48%, X2=31.25%, X3=36.7% and X4=28.2% for the four groups. Like the other parameters, the least amount of decrease was noted in the fourth group.

DISCUSSION

Many studies have been published about methanol-induced toxicity. In 1953, Benton and Calhoun examined 320 cases of methanol toxicity during a mass poisoning with contaminated whiskey.¹⁶ Garner and Lee have studied methanol-induced retinopathy in animal models. They have noticed, in a different study on mice, a decrease in the ERG b-wave amplitude in those animals who had oral methanol; however, a much smaller decrease was noticed in a group of mice who received disulfiram prior to methanol.¹³

In our study the decrease in the b-wave amplitude which was noticed in group 4 (recipients of folic acid and vitamin B₁₂) was the least compared to the other groups.

There are different theories regarding the primary site of injury and the mechanism by which the injury occurs.¹⁴ Acute methanol-induced toxicity causes a severe metabolic acidosis with accumulation of toxic metabolites, especially formic acid, which is a cause of neurologic symptoms in the subject.⁶ Formic acid causes hypoxic toxicity by cytochrome-oxidase inhibition. In a comparative study between the b-wave amplitude and the O.P. amplitude after methanol-induced toxicity, Garner and co-workers noticed that b-wave amplitude is more sensitive than O.P. They suggested that retinal ischemia is not involved in methanol-induced toxicity.²

Murray and co-workers in an animal model of methanol-induced toxicity using light microscopy showed generalized retinal edema and vacuolation in the photoreceptors and retinal pigment epithelium. Using electron microscopy they showed swelling and disruption of the mitochondria in photoreceptor inner segments, optic nerve and the retinal pigment epithelium. They concluded that in their animal model a direct retinal involvement was seen with methanol toxicity.^{4,5}

In a different study using electrophysiologic analysis, it has been suggested that the primary site of injury in methanol toxicity is at the level of Muller cells in the retina. Considering that the toxic dose of methanol is 2.5-4 g/kg in animal models,^{9,13,15} we used 4g/kg intraperitoneally. Some studies have reported the use of folic acid and vitamin B₁₂, including a study by Frenia and co-workers in which they reported seven cases of methanol toxicity by inhalation in 1993.¹ These patients presented with central nervous system depression, nausea, vomiting, shortness of breath, photophobia, and/or decreased visual acuity. Treatment modalities in these patients included correction of acidosis, folic acid, and ethanol infusion.

Buzna and Cernea in 1991 reported a case of methanol intoxication which presented with bilateral blindness without perception of light. After treatment with three perfusions per day with ethanol, vitamin B₁, vitamin B₆, and nicotinated Xanthinol for six days they reported a good result of VOD=23 nc and VOC=18 nc.¹¹

In another study Schramm and Rogner treated a case of methanol intoxication with folic acid and ethanol.⁵ Tephly concluded that the role of folic acid in attenuating methanol toxicity in humans is due in part to low hepatic tetrahydrofolate (H4 folate).¹²

Because of this deficiency, accumulation of formate occurs with methanol toxicity which causes toxic effects. Treatment of methanol toxicity with folic acid will compensate for this deficiency and decrease the side effects of methanol.

In our study a combination of folic acid and vitamin B₁₂ showed a more preventive effect in methanol toxicity than the use of folic acid alone. Therefore, vitamin B₁₂ shows a synergistic effect with folic acid in attenuating the neurologic

and ophthalmic toxicity of methanol. This could be a subject for further investigations.

REFERENCES

1. Frenia ML, Schauben JL: Methanol inhalation toxicity. *Ann Emerg Med* 22 (12): 1919-23, 1993.
2. Garner CD, Lee EW, Louis - Ferdinand RT: Muller cell involvement in methanol-induced retinal toxicity. *Toxicol Appl Pharmacol* 130 (1): 101-7, 1995.
3. King I: Acute methanol poisoning: a case study. *Heart - Lung* 21 (3): 260-4, 1992.
4. Murray TG, Rajani C, Elles JT, Burke JM: Ocular methanol toxicity: cell type specificity *in vitro*. *Invest Ophthalmol Vis Sci* 31: 286, 1990.
5. Schramm A. et al: Acute methanol poisoning - a review and a case report. *Anaesthesiol Reanim* 16(4): 259-65, 1991.
6. Lee EW, Garner CD: Animal model for the study of methanol toxicity; comparison of folate - reduced rat responses with published monkey data. *J Toxicol Environ Health* 41(1): 71-82, 1994.
7. Grant S: Toxic Retinopathies, In: Tasman W, Jaeger EA, (eds.), *Duane's Clinical Ophthalmology*. Vol. 3, Chapter 33, Philadelphia: Lippincott-Raven, pp. 6-8, 1995.
8. Murray G, et al: Methanol poisoning. *Arch Ophthalmol* 109: 1012-1016, 1991.
9. Lee EW, Garner CD: A rat model manifesting methanol-induced visual dysfunction suitable for both acute and long-term exposure studies. *Toxicol Appl Pharmacol* 128(2): 199-206, 1994.
10. Potts AM, Praglin J, Farkas I, Lowell MS, Orbison-Chickering D: Studies on the visual toxicity of methanol, VIII: additional observations on methanol poisoning in the primate test object. *Am J Ophthalmol* 40: 76-82, 1995.
11. Buzna E, Cernea D: The therapeutic approach in optic neuropathy due to methyl alcohol. *Oftalmologia* 35(1): 39-42, 1991.
12. Tephly TR: The toxicity of methanol. *Life Sci* 48(11): 1031-41, 1991.
13. Garner CD, Lee EW: Evaluation of methanol - induced retinotoxicity using oscillatory potential analysis. *Toxicology* 11: 93 (2-3): 113-24, 1994.
14. Garner CD, Lee EW: Role of retinal metabolism in methanol-induced retinal toxicity. *J Toxicol Environ Health* 44(1): 43-56, 1995.
15. Potts AM, Johnson LV: Studies on the visual toxicity of methanol. I. The effect of methanol and its degradation products on retinal metabolism. *Am J Ophthalmol* 35: 107, 1952.
16. Bennett IL, Carey FH, Mitchell GL, et al: Acute methyl alcohol poisoning: a review based on experiences in an outbreak of 323 cases. *Medicine* 32: 431, 1953.
17. Benton CD, Calhoun FP: The ocular effects of methyl alcohol poisoning: report of a catastrophe involving three hundred and twenty persons. *Trans Am Acad Ophthalmol Otolaryngol* 56: 875, 1952.
18. McGregor IS: A study in the histopathological changes in the retina and late changes in the visual field in acute methyl alcohol poisoning. *Br J Ophthalmol* 27: 523. 1943.