

TORSION AND GANGRENE OF THE GALLBLADDER IN A CHILD

AKBAR BEHDAD, M.D.

From the Department of Surgery, Isfahan University of Medical Sciences, Isfahan, I.R. Iran.

ABSTRACT

Torsion of the gallbladder with gangrene is a rare condition which is generally due to an abnormal anatomical variation of the organ; i.e., loss of fixation of the organ to the inferior margin of the liver and the presence of a long mesocyst.

The case considered is a seven year old boy who presented with acute abdominal pain. He underwent laparotomy 36 hours after having sustained blunt abdominal trauma. Operation was limited to cholecystectomy and removal of a gangrenous gallbladder which had undergone torsion. The postoperative course was uneventful.

MJIRI, Vol. 12, No. 2, 191-192, 1998.

Keywords: gallbladder, diseases, torsion, trauma, cholecystectomy.

INTRODUCTION

Torsion of the gallbladder is a rare entity. Approximately 300 cases have been reported since it was first described in 1898 by Wendel. The condition occurs most often in the elderly.¹ Volvulus of the gallbladder is extremely rare in the pediatric population.² Although the etiology is unknown, a constant finding is the presence of the gallbladder on a mobile mesentery—the so-called floating gallbladder. Torsion or volvulus of the gallbladder occurs when the organ twists axially causing subsequent occlusion of bile and/or blood flow. Torsion of the gallbladder is a surgical emergency. Accurate preoperative diagnosis is difficult, and delay in cholecystectomy can result in a fatal outcome.³

Case report

A seven year old boy presented with acute upper-abdominal pain of sudden onset 24 hours prior to admission. The pain was colicky in nature at first but became constant and progressive after a few hours. Abdominal pain had

begun after he was kicked by one of his classmates. On physical examination, vital signs were stable, temperature was 37.5°C on arrival, pulse rate was 100 beats/min, and blood pressure 100/70 mmHg.

The patient was well-developed, slender and constitutionally short-statured. He appeared to be acutely ill. Positive physical findings were limited to the abdomen. Tenderness and guarding was present in the right upper quadrant, but the abdomen was flat, had normal bowel sounds, and had no palpable mass.

Blood chemistry and complete blood count were normal except for mild leukocytosis (12000/mm³). Urine specimen was clear. An abdominal radiography revealed no distended bowel or free air in the peritoneal cavity. Ultrasonography of the abdomen revealed a normal liver and gallbladder, and upper G.I. series was not helpful.

The patient was under close observation for 12 hours, during which abdominal pain became worse, temperature rose to 38°C and the white blood cell count to 18000/mm³. With a possible diagnosis of acute appendicitis or retroperitoneal perforation of the duodenum, exploratory

Gallbladder Torsion and Gangrene

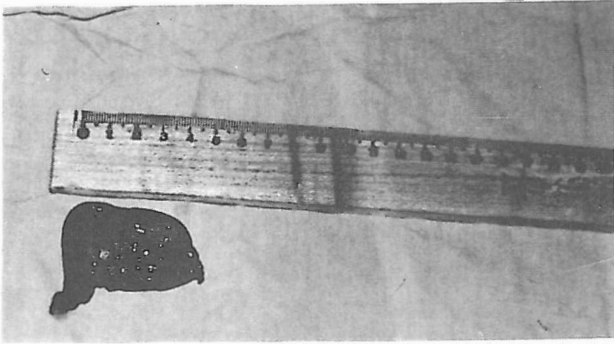


Fig. 1. Photograph of the resected gangrenous gall bladder

laparotomy was performed through a midline incision. At surgery the gallbladder was found to be in its normal location but gangrenous (Fig. 1). It was twisted around the cystic duct. There was no attachment to the liver and it was completely peritonealized. No other lesion was found. Cholecystectomy was performed, and histological examination of the gallbladder revealed hemorrhagic gangrene. The postoperative course was uneventful.

DISCUSSION

Gallbladder volvulus is a rare disease which may affect the elderly. It clinically mimics acute cholecystitis.⁴ Signs and symptoms of gallbladder volvulus are often subtle, and radiologic evaluation may be normal. A high index of suspicion is necessary to make the preoperative diagnosis.⁵ Ultrasonography may be helpful for the diagnosis, but

ultrasonographically detectable modification of the gallbladder occurs only after the onset of pain.

Torsion of the gallbladder must be considered in an elderly patient with sudden onset of upper abdominal pain, nausea, vomiting and a palpable mass without jaundice.⁶

No routine laboratory or invasive study enabled us to make the right preoperative diagnosis. Torsion is an acute surgical emergency in which diagnosis is generally made upon laparotomy. Is there any relation between blunt abdominal trauma and torsion of the gallbladder in this case? This is a difficult subject to prove, but it is a possibility.

REFERENCES

1. Ngugen T, Geraci A, Bauer JJ: Laparoscopic cholecystectomy for gallbladder volvulus. *Surg Endosc* 9: 519-521, 1995.
2. Levard G, Weil D, Barret D, Barbier J: Torsion of the gallbladder in children. *J Pediat Surg* 29: 569-70, 1994.
3. Panich V: Torsion of the gallbladder. *J Med A Thai* 77 (12): 669-72, 1994.
4. Hambi M, Bondiau JV, Algaba R: Gallbladder volvulus: a case report. Could ultrasound be the key of early diagnosis? *Acta Chir Belg* 96: 41-43, 1996.
5. Schroder Dm, Cusumano DA: 3rd laparoscopic cholecystectomy for gallbladder torsion. *Surg Laparosc Endosc* 5: 330-4, 1995.
6. Schwartz SI: Anatomy of the Biliary Tract. In: Schwartz SI, Ellis H, (eds.), *Maingot's Abdominal Operations*. California: Appleton & Lange, pp. 1344-1347, 1990.