

## ENDOSCOPIC REMOVAL OF GASTRIC CANCER BY METHYLENE BLUE INJECTION METHOD: SUBMUCOSAL CANCER WITHOUT THE NON-LIFTING SIGN

AKIHIRO MUNAKATA, M.D., AND YOSHIHARU UNO, M.D.

*From the First Department of Internal Medicine, Hirosaki University School of Medicine, 5 Zaifu-cho,  
Hirosaki, Aomori 036, Japan.*

### ABSTRACT

A 59 year old man is presented with adenocarcinoma of the stomach. In order to evaluate for the presence of the non-lifting sign, methylene blue was injected 2 mm from the perimeter of the tumor. Since the tumor lifted, snare removal of the tumor was done, safely. Partial gastrectomy was performed 2 weeks after endoscopic removal of the tumor which revealed no residual tumor or lymph node metastasis.

*MJIRI, Vol. 9, No. 2, 97-100, 1995.*

### INTRODUCTION

Gastric carcinoma is similar to carcinoma of the large intestine in that it originates from the epithelium and progresses by infiltrating into the submucosa and then into the muscularis propria. Radical curative therapy by endoscopic resection alone is possible only for small tumors in the early stage of carcinomatous growth.<sup>1-4</sup> For a gastric carcinoma in the advanced stage, complete cure is unlikely unless lymph node dissection and gastrectomy are performed. For early gastric cancers 2 cm in size or larger, the main treatment procedure is laparotomy, similar to that applied for carcinoma in the advanced stage.

In an earlier publication, we have reported that the non-lifting sign is useful for establishing the limiting conditions for application of endoscopic removal of colonic carcinoma, that is, conditions characterized by massive tumor infiltration into the

Herein we describe a patient with a large 27mm gastric tumor that was amenable to radical therapy by endoscopic removal. This was possible because the non-

lifting sign was not present.

### CASE REPORT

The patient, a 59 year old male in whom a stomach tumor had been found, came to our hospital for a more thorough examination.

Endoscopy confirmed the presence of a protuberant tumor in the greater curvature opposite to the angulus. Biopsy performed on tissue specimens from the tumor head showed that it was an adenocarcinoma. A biochemical assay of the patient's blood revealed no abnormal findings, and tumor markers (CEA,  $\alpha$ -FP) were also negative. Chest X-ray films showed no evidence of metastasis, and ultrasonography and computed tomography of the abdominal region indicated no signs of metastases in the liver or lymph nodes. Double-contrast gastrography was in agreement with the endoscopic findings in revealing a 3cm protuberant tumor in the greater curvature (Fig. 1). The tumor had a 2.5cm thick base and an irregular surface. However, it was not possible to make a precise stage-classification of the carcinoma, as to whether it was Type I (classification of the Japan Gastroenterological Endoscopic Society; protruded type) early stage, or advanced Borrmann's Type I. For this reason, the tumor was

#### Correspondence and address for reprint requests:

Yoshiharu Uno, MD, First Department of Internal Medicine, Hirosaki University School of Medicine, 5 Zaifu-cho, Hirosaki, Aomori 036, Japan. Tel: 0172 (33)5111, Fax: 0172(37) 5946

## Endoscopic Removal of Gastric Cancer

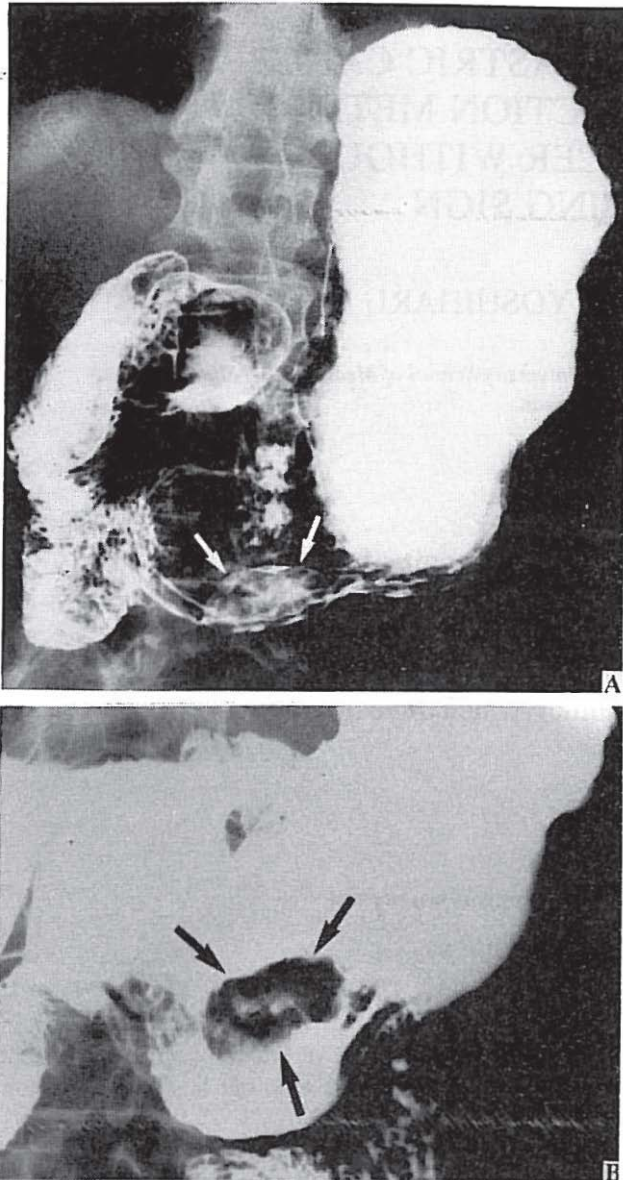


Fig. 1. A: Double-contrast gastrography showing the tumor in the greater curvature (arrow).  
B: Compression study of the same lesion (arrow).

inspected for the presence of the non-lifting sign. This was done by injecting methylene blue from a location some 2mm from the tumor perimeter to observe whether the tumor would lift. As this tumor did lift, it was then encircled with a snare for removal, along with the normal mucosa that had appeared blue (Fig. 2). The size of the removed specimen was 27×17×15 mm, and the additionally-resected section measured 25×15mm. During and after resection, the patient did not suffer any abdominal pain, nor was there any sign of hemorrhage or perforation in the removed part of the stomach. For histological study, ten step sections from the specimen were cut,

stained with hematoxylin and eosin, and examined microscopically. The tumor tissue was that of a well-differentiated adenocarcinoma, extending slightly beyond the muscularis mucosae. However, tumor infiltration was not seen in the lymphatic or blood vessels. Moreover, all the sections had a margin of normal submucosal tissue more than 1mm wide between the carcinoma and the resected end (Fig. 3). Two weeks after the endoscopic removal of the tumor, the patient underwent partial gastrectomy to determine the presence of any residual tumor and/or lymph node metastasis, neither of which was found.

### DISCUSSION

On the basis of our success in removing large colonic lipomas by resorting to the methylene blue injection method, we propose that the use of endoscopy for removal of large tumors should be extended.<sup>6</sup> Furthermore, as has been reported, the limiting conditions for the indications of endoscopic colon cancer removal can be assessed in terms of the "non-lifting sign".<sup>5</sup> The methylene blue injected into the submucosa of a normal intestinal wall can be seen as a blue area through the transparent mucosal membrane. When the tumor is contained within the mucosal layer, as in the case of an adenoma or intramucosal carcinoma, the tumor will lift along with the surrounding mucosa after injection of methylene blue. However, in contrast to normal mucosa, the thickness and dense cell accumulation of the tumor will mask the methylene blue beneath the tumor and prevent it from being seen; consequently, the boundary of the tumor will be recognized due to the difference in the color shade. The mucosa of the stomach is thicker than that of the large intestine and is not stained with methylene blue. However, this patient presented a clearly visible tumor boundary similar to that of a tumor of the large intestine. This clear boundary definition was most helpful in selecting the position for applying the snare for removal of the tumor and made it possible to achieve precision in ensnaring the entire tumor in one portion, even though this particular tumor was very large. The tumor also had a thick peduncle measuring 2.5 cm in diameter, but no complications occurred. Pre-removal infusion of methylene blue into the submucosa should occur roughly in the middle of the submucosa,<sup>5</sup> so that removal can be achieved with less electrocoagulation than would otherwise be the case if no methylene blue had been injected.

In studies of carcinoma of the large intestine, we found that all carcinomas that had penetrated beneath the submucosa presented the non-lifting sign. These carcinomas all showed infiltration to a depth below the mid-submucosa. The present patient had a gastric carcinoma that had infiltrated to the submucosa, and in view of the



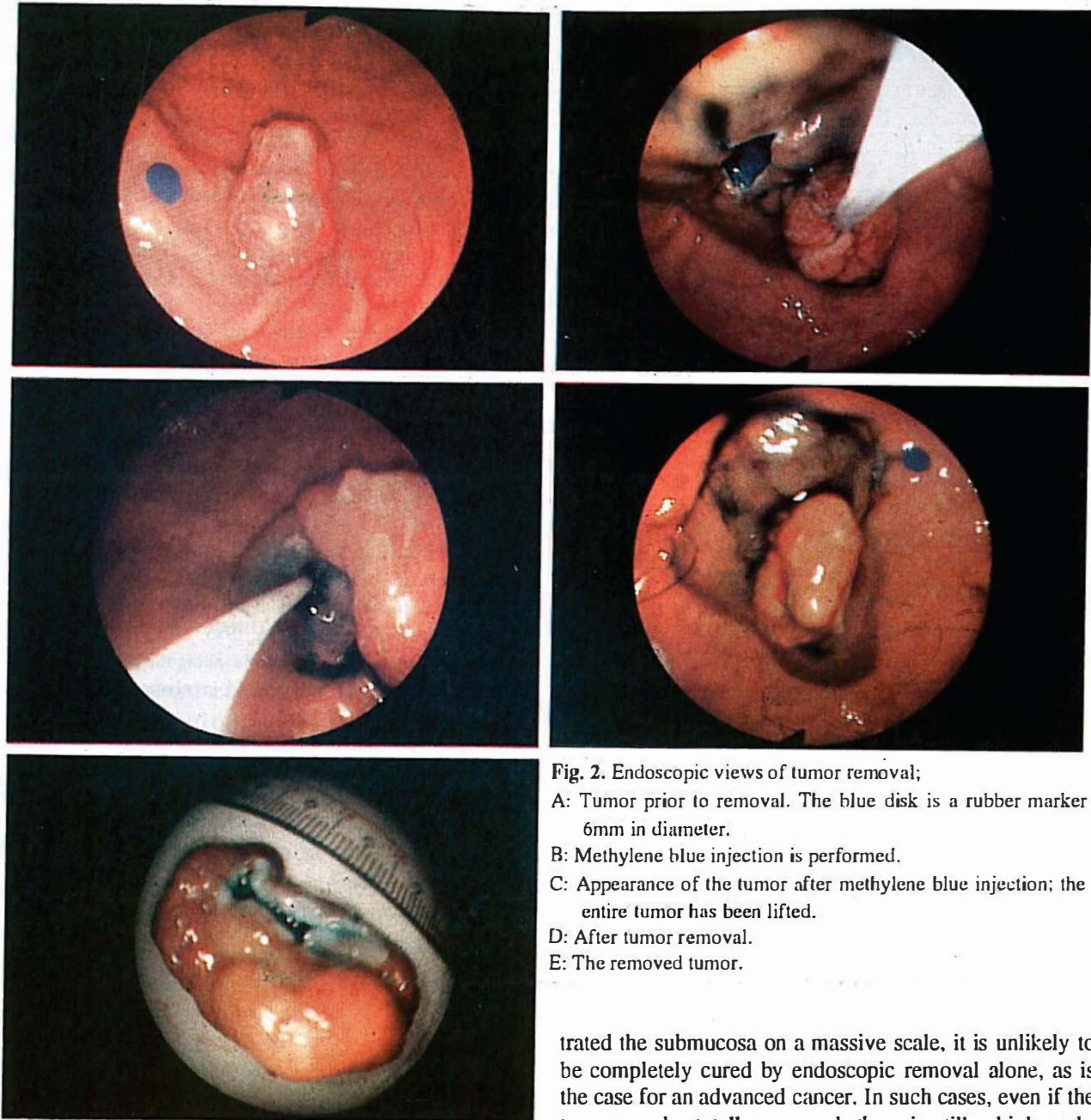


Fig. 2. Endoscopic views of tumor removal;  
 A: Tumor prior to removal. The blue disk is a rubber marker 6mm in diameter.  
 B: Methylene blue injection is performed.  
 C: Appearance of the tumor after methylene blue injection; the entire tumor has been lifted.  
 D: After tumor removal.  
 E: The removed tumor.

slight carcinomatous spread beyond the lamina muscularis mucosa, submucosal injection of methylene blue induced separation from the submucosa and lifting of the pathological site (Fig. 4). Gastrectomy after excision was performed to check for residual carcinoma, but none was found to be present. Thus it is clear that in carcinomas that have spread slightly beyond the muscularis mucosa, or in other words, submucosal cancers that show slight fibrosis with no massive infiltration will lift after a submucosal injection of methylene blue, thereby facilitating endoscopic removal of the entire tumor.

If the carcinoma, be it colonic or gastric, has infil-

trated the submucosa on a massive scale, it is unlikely to be completely cured by endoscopic removal alone, as is the case for an advanced cancer. In such cases, even if the tumor can be totally removed, there is still a high probability of metastasis to the lymph nodes.<sup>1,7-9</sup> However, if there is only slight infiltration into the submucosa (less than one-third of the submucosal thickness), then the extent of lymph node metastasis will still be small, both in the case of colonic or gastric carcinoma, so that there will be a good chance of complete endoscopic elimination by means of this methylene blue injection method.

Although we have demonstrated the successful removal of a gastric carcinoma endoscopically, an early protruding cancer of the present type admittedly is a rare form of stomach cancer. In most cases, gastric cancer is of the depressed type and associated with ulcer formation.<sup>1,10</sup> This indented type of cancer in its early stage is

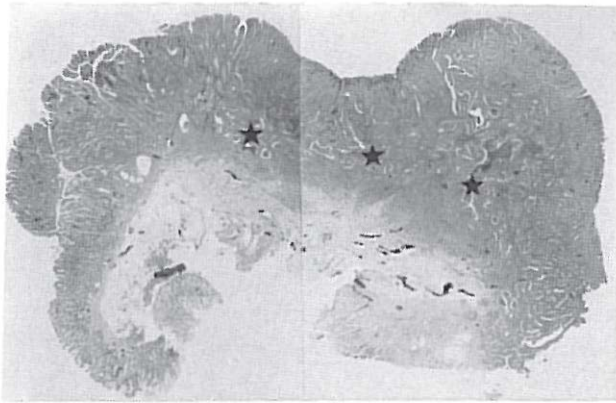


Fig. 3. Appearance of removed tumor tissue; the stars indicate submucosal infiltration.

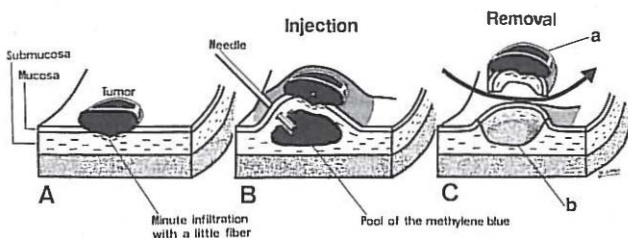


Fig. 4. Methylene blue injection into the gastrointestinal carcinoma with minute infiltration into the submucosa;  
 A: The carcinoma with minute infiltration.  
 B: Methylene blue has been injected into the submucosa.  
 C: After resection of the tumor.

modified not only by proliferated fibers, due to the cancer itself, but also by associated fibrosis due to the deep ulcer. Therefore it is not possible to achieve a clear, correct assessment of the non-lifting sign in such situations. Therefore, in the stomach, application of the above-mentioned technique should be limited only to carcinomas of the protuberant type, as was the case in the presented patient.

## REFERENCES

1. Takekoshi T, Takagi K, Kato Y: Radical endoscopic treatment of early gastric cancer. *Gann Monograph on Cancer Research* 37: 111-125, 1990.
2. Ohshiba S, Ashida K, Tanaka M, Sakaguchi T, Umegaki E: Curative endoscopic resection of early cancer. *Stomach and Intestine* 28: 1421-6, 1993.
3. Tada M, Murakami A, Karita M, Yanai H, Okita K: Endoscopic resection of early gastric cancer. *Endoscopy* 25: 445-50, 1993.
4. Haruma K, Sumii K, Inoue K, Teshima H, Kajiyama G: Endoscopic therapy in patients with inoperable early gastric cancer. *Am J Gastroenterol* 85: 522-6, 1990.
5. Uno Y, Munakata A: The non-lifting sign of invasive colon cancer. *Gastrointest Endosc* 40: P97 (abstract), 1994.
6. Uno Y, Sasaki Y, Munakata A: A large lipoma successfully resected by endoscopy. *Endoscopica Digestiva* 5: 421-5, 1993.
7. Haggitt RC, Glotzbach RE, Soffer EE, Wruble LD: Prognostic factors in colorectal carcinomas arising in adenomas. Implications for lesions removed by endoscopic polypectomy. *Gastroenterology* 98: 328-36, 1985.
8. Takagi K, Ohta H: Factors influencing the prognosis of early gastric cancer with submucosal involvement. *Stomach and Intestine* 17: 485-95, 1982.
9. O-izumi H, Matsuda T, Fukae K, Furusawa A, Mito S, Monma T, Furusawa A, Mito S, Takahashi K: Endoscopic resection for early gastric cancer: the actual procedure and clinical evaluation. *Stomach and Intestine* 26: 289-99, 1991.
10. Hirota T, Itabashi M: Chronological changes in the morphological features of early gastric cancer: especially recent changes in macroscopic findings. *Jpn J Clin Oncol* 14: 181, 1984.