

## PERIPHERAL NEUROEPITHELIOMA: A STUDY OF EIGHT CASES

GUITY IRAVANLOO, M.D.,\* AND ALI ZARE MEHRJARDI, M.D.\*\*

*From the Department of Pathology, The Cancer Institute, Tehran University of Medical Sciences, Tehran,  
Islamic Republic of Iran.*

### ABSTRACT

Peripheral neuroepithelioma (PN) is a rare highly malignant tumor, classified in the group of small round cell tumors. We report eight cases of PN, based on histologic appearance and immunohistochemical staining for neuron-specific enolase (NSE). Electron microscopy was also performed in three cases.

The tumors exhibited rapid local growth, leading to limb amputation in five cases. Histologically the presence of Homer-Wright rosettes is a characteristic of this neoplasm. Tumoral cells are generally positive for NSE. The relationship of PN with Ewing's sarcoma is discussed.

*MJIRI, Vol. 8, No. 1, 5-8, 1994.*

### INTRODUCTION

Peripheral neuroectodermal tumor (PNET), also called peripheral neuroepithelioma (PN) and peripheral neuroblastoma, is a rare soft tissue tumor which has been confused histologically with a variety of other small round cell tumors such as rhabdomyosarcoma, malignant lymphoma, undifferentiated small cell carcinoma and Ewing's sarcoma.<sup>1</sup> First described by Stout in 1918 as "a primitive neuroectodermal tumor with rosettes arising in association with the ulnar nerve", it has since been a fascinating and challenging neoplasm both for pathologists and clinicians. In recent years, new methods of investigation have given us more insight about its origins. However, because of the rarity of this neoplasm, most studies could not gather a large number of cases to clearly define its biologic behavior, although it is generally acknowledged as a highly malignant tumor.<sup>2</sup> We describe our findings in eight cases of PN at the Cancer Institute.

### MATERIAL AND METHODS

Files of the Dept. of Pathology of the Cancer Institute, Imam Khomeini Hospital, from 1981 to 1991 were searched for PN, "small round cell tumor", or similar diagnoses. Two cases with a primary diagnosis of PN, and three others which on review of the slides had features suggestive of PN were selected. Two cases were gathered prospectively, and one case was contributed by a colleague. Hematoxylin and eosin and PAS-stained slides were studied in all cases. Paraffin-embedded tissue blocks were cut and stained immunohistochemically by the peroxidase-antiperoxidase method for neuron-specific enolase (NSE) in all cases, and for chromogranin in the first five cases (stains from Dakopatts).

### RESULTS

Clinical summaries of cases are given in Table I. The patients' ages ranged from 6 to 34 years, with a median of 19.0 years. The M:F ratio was 3:5. Five tumors were located in the extremities, one in the back, and two patients presented with metastases in the lung and scalp whose primary neoplasms were located in the back of the knee and neck,

\* Assistant Professor of Pathology

\*\* Resident in Pathology, Dept. of Pathology, Cancer Institute, Imam Khomeini Hospital, Tehran University of Medical Sciences, Tehran.

## Peripheral Neuroepithelioma

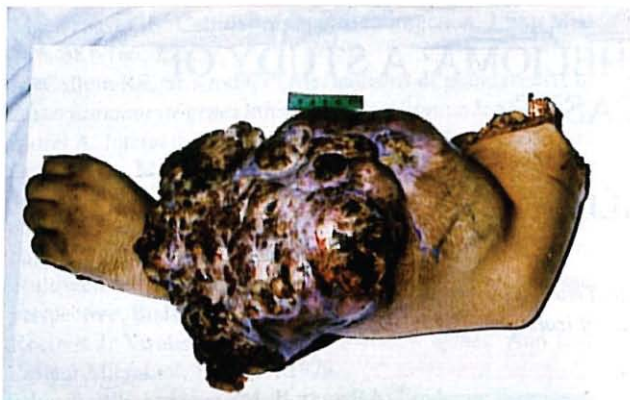

Fig. 1. Huge tumoral growth in forearm with surface ulceration and necrosis.

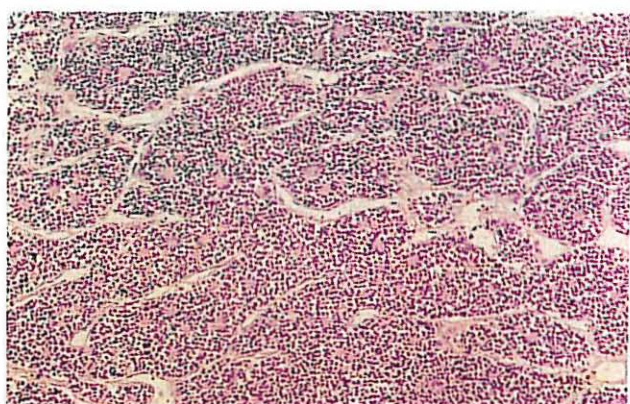


Fig. 2. Sheet of small round cells with conspicuous sinusoidal canals (H&E, X 48).

respectively. Tumors ranged from 3 to 25cm in diameter; five tumors had diameters greater than 10cm, all located in the extremities, which were eventually amputated (Fig. 1). These tumors were soft, seemingly lobulated and white to gray on section, with areas of necrosis. Bone invasion was present in three cases.

Histologically, tumors were composed of sheets of small cells, often with a prominent organoid or lobular pattern rendered by fine fibrovascular septa or sinusoidal canals (Fig. 2). Cells ranged from 6 to 9  $\mu$ M in diameter, with little pleomorphism in each case (Fig. 2). Mitotic figures were prevalent, averaging 3-6 mitoses per 10HPF. Cells had round or oval, hyperchromatic nuclei, some with small indistinct nucleoli, and little or no visible cytoplasm. In cases with previous radio-/chemotherapy the nuclei were vesicular with clumped chromatin. Homer-Wright rosettes, the histologic hallmark of this tumor, were prominent in two cases (Fig. 3), easily found in four cases, and focal or difficult to discern in two others. PAS-positive tumoral cells were found in three cases.

Immunohistochemically, all cases except one (case 6)

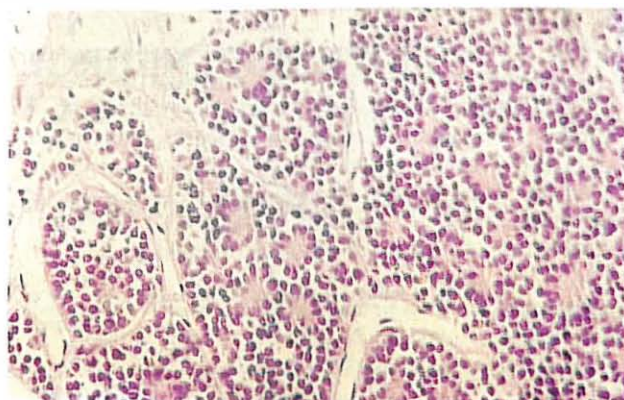


Fig. 3. Homer-Wright rosettes, made of fine pale cytoplasmic processes, are prominent (H&E, X 112).

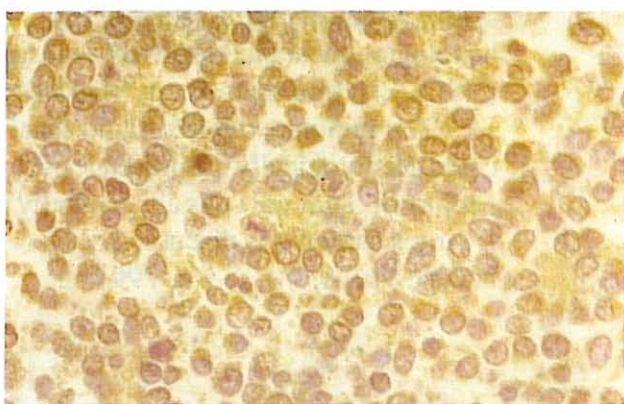


Fig. 4. Immunohistochemical staining for NSE shows diffuse cytoplasmic positivity in this case (peroxidase-antiperoxidase method, X 800).

were positive for NSE, (Fig. 4), but none of the five cases stained for chromogranin were positive.

Electron microscopic studies were done in three cases in whom wet tissue were available. Dense core neurosecretory granules and fine cytoplasmic cell processes were present in two cases. In addition, in the other case, synaptic vesicles and tight junctions among cellular processes could be discerned.

## DISCUSSION

Peripheral neuroepithelioma is an uncommon malignant tumor that appears at any age.<sup>2</sup> It belongs to the group of "small round cell tumors",<sup>3</sup> and shows features of neuronal differentiation such as presence of Homer-Wright rosettes. This tumor seems to be more common in adolescents and young adults. Coffin and Dehner<sup>3</sup> found that PN comprised the second largest category of malignant neurogenic tumors among 900 soft tissue neoplasms in children and adolescents. In the series of Hashimoto et al.<sup>1</sup> patients had a median age

Table I. Clinical characteristics of eight cases of peripheral neuroepithelioma studied at the Cancer Institute.

Case No	Sex	Age	Location	Tumor diameter (cm)	Duration of tumor to surgery	Type of Surgery	Previous Treatment	Metastasis	Follow-up
1	F	23	Thigh	20	1 yr	Hip disartic.	-	-	Alive & well, 3 yrs
2	F	12	Forearm	11	3 yr	Mid-arm amputation	XRT*/CHEM**	?	Lost after 6mo.
3	F	26	Knee	?	?	Excision	-	Lung	Alive & well, 2 yrs
4	M	11	Arm	14	18 mo.	Forequarter amputation	XRT/CHEM	Lung	Dead, one mo.
5	F	34	Arm	21	2 yr	Forequarter amputation	CHEM.	?	Could not be traced
6	M	25	Forearm	25	11 mo	Mid-arm amputation	CHEM.	Axillary fat	Alive with disease, 10 mo.
7	M	11	Neck	?	6 mo	Incision	CHEM.	Scalp, CNS	Alive with disease, 1 yr
8	F	15	Back	3	1 yr	Excision	-	-	Alive with disease, 10 mo.

\*XRT= Radiotherapy

\*\*CHEM= Chemotherapy

of 21 years, very close to our series with a median age of 19.0 years.

The most common sites are reported to be the chest wall and extremities.<sup>2</sup> In our patients tumors occurred most frequently in the extremities. Patients presented with a painless, often rapidly growing mass. In case 6, the tumor attained a diameter of 25cm in less than a year, despite partial excision and two courses of chemotherapy. Grossly PN is very soft, as it induces little reactive fibrosis. Areas of hemorrhage and necrosis are more common in larger tumors. It invades adjacent tissues indiscriminately, although the incidence of bone involvement is said to be lower than Ewing's sarcoma.<sup>5</sup>

By light microscopy, the presence of Homer-Wright rosettes is diagnostic of PN, as Schmidt et al. claim.<sup>4</sup> However, these structures may be present only focally, and sometimes many sections must be searched carefully to find them. In addition, prompt and adequate fixation of tissue is mandatory to properly preserve these delicate structures. Apparently, in cases with few or indistinct rosettes, other diagnostic modalities must be used to confirm the diagnosis.

Immunohistochemically, markers of neural differentiation such as NSE and Leu-7 have been shown in tumor cells.<sup>6</sup> Our findings are in accord with those of Cavazzano et al,<sup>6</sup> who studied 40 cases with a panel of

monoclonal antibodies. However, Lombart-Bosch et al.<sup>7</sup> showed chromogranin positivity in five of their ten cases. Even desmin, a conventional muscle-specific intermediate filament, has recently been described in two cases of otherwise typical PNET.<sup>8</sup> Further large-scale studies are needed to identify the patterns of immunohistochemical reactivity in this tumor.

Early in 1970s, finding a clear relationship of this tumor to a peripheral nerve and ruling out disseminated neuroblastoma were diagnostic criteria for PN. More recently, Marina et al.<sup>9</sup> and Schmidt et al.<sup>4</sup> proposed diagnostic criteria for PN, with emphasis on the presence of Homer-Wright rosettes and expression of neural markers by immunohistochemical methods. EM studies to demonstrate features of neural differentiation in tumor cells are also helpful.

Chromosomal studies to identify known cytogenetic aberrations are finding diagnostic utilities in pathology labs, with encouraging results in cases of small round cell tumors.<sup>10</sup> A chromosomal translocation, t(11:22)(q24:q12) is present in the cells of PN, which is identical to that of Ewing's sarcoma, indicating a close relationship between these two neoplasms.<sup>11</sup> Indeed, studies on osseous and extraskelatal Ewing's sarcoma have disclosed the presence of cellular markers similar to PN in their cells.<sup>12,13</sup> *In-vitro*, Ewing's

## Peripheral Neuroepithelioma

sarcoma cells have been induced to differentiate toward neuronal cells by adding cAMP or TPA to the culture medium.<sup>14</sup> These findings indicate that Ewing's sarcoma represents the most undifferentiated form of PNET.<sup>12</sup>

As of biologic behavior, these tumors are claimed to be highly malignant,<sup>11</sup> even more than Ewing's sarcoma,<sup>5</sup> and so clear distinction and early aggressive therapy are of great importance. Limb amputation in five of our eight cases as the only available modality to halt tumor growth attests to the highly aggressive nature of this neoplasm. Of our patients, one died with metastatic disease one month after surgery, three are alive with disease less than one year after diagnosis, two were disease-free two and three years after surgery, and two patients could not be traced. In case 6, a 7-cm metastatic tumor appeared in the ipsilateral axilla two months after cessation of chemotherapy.

A combined modality approach to treatment, including surgery, radiation and chemotherapy is often necessary since many cases present with advanced local disease or metastases. Radiation in combination with chemotherapy has been claimed to provide efficient local treatment of the primary tumor at presentation,<sup>11</sup> although in five of our cases, chemotherapy and/or radiotherapy failed to do so. Others propose aggressive surgery initially and adjuvant chemotherapy.<sup>9</sup> It seems that if the tumor is not eradicated early in its course, the morbidity and mortality rates will be unacceptably high.

### ACKNOWLEDGEMENTS

We are indebted to Dr. P. Ashrafzadeh and Dr. F. Tirgari for immunohistochemistry, Dr. M. Takhi for electron microscopy, and Dr. F. Fereidooni for contributing the last case.

### REFERENCES

1. Hashimoto H, Enjoji M, Nakajima T, Kiryu H, Daimaru Y: Malignant Neuroepithelioma. *Am J Surg Pathol* 7: 309-318; 1983.
2. Enzinger FM, Weiss SW. *Soft tissue tumors*. 2nd ed., St Louis, C.V. Mosby Co, p. 806-10, 1988.
3. Coffin CM, Dehner LP: Peripheral neurogenic tumors of the soft tissue in children and adolescents: a clinicopathologic study of 139 cases. *Ped Pathol* 9: 387-407; 1989.
4. Schmidt D, Herrmann C, Jurgens H, Harms D: Malignant peripheral neuroectodermal tumor and its necessary distinction from Ewing's sarcoma. *Cancer* 68: 2251-2259, 1991.
5. Rosai J: *Ackerman's Surgical Pathology*. 7th ed., St. Louis, C.V. Mosby Co, p. 1614-16, 1989.
6. Cavazzano A, et al: Peripheral neuroepithelioma. Morphologic and immunologic criteria for diagnosis. *Lab Invest* 1988: 17 A (abstract).
7. Lombart-Bosch A, Terrier-Lacombe J, Peydro-Olaya A, Contesso G: Peripheral neuroectodermal sarcoma of soft tissue (peripheral neuroepithelioma): A pathologic study of ten cases with differential diagnosis regarding other small, round-cell sarcomas. *Hum Pathol* 20: 273-280; 1989.
8. Parham D, Dias P, Kelly DR, Rutledge JC, Houghton P: Desmin positivity in primitive neuroectodermal tumors of childhood. *Am J Surg Pathol* 16(5): 483-492, 1992.
9. Marina NM, Etcubanas E, Parham D, Bowman LC, Green A: Peripheral primitive neuroectodermal tumor (peripheral neuroepithelioma) in children. *Cancer* 64: 1952-1960, 1989.
10. Fletcher JA, et al: Diagnostic relevance of clonal cytogenetic aberrations in malignant soft tissue tumor. *N Engl J Med* 324: 436-42, 1991.
11. Israel MA: Peripheral neuroepithelioma. In: Williams CJ, et al. (ed), *Textbook of Uncommon Cancer*. John Wiley & Sons, Ltd, p. 683-90, 1988.
12. Ushigome S, et al: Immunocytochemical and ultrastructural studies of the histogenesis of Ewing's sarcoma and putatively related tumors. *Cancer* 64: 52-62, 1989.
13. Kawaguchi K, Koike M: Neuron-specific enolase and Leu-7 immunoreactive small round cell neoplasm. The relationship to Ewing's sarcoma in bone and soft tissue. *Am J Clin Pathol* 86: 79-83, 1986.
14. Cavazzano A, Miser JS, Jefferson J, Triche TJ: Experimental evidence for a neural origin in Ewing's sarcoma of bone. *Am J Pathol* 127(3): 507-18, 1987.