

DIFFUSE CORONARY ARTERIAL ECTASIA WITH HYPERTROPHIC CARDIOMYOPATHY

*MOHAMMAD J. HASHEMI, AND **ALI ANDON PETROSSIANS

*From the Cardiovascular Research Center, Shahid Rajaii Hospital, Iran University of Medical Sciences,
Tehran, Islamic Republic of Iran.*

ABSTRACT

A 40 year old male, a known case of hypertrophic cardiomyopathy, was admitted for catheterization. At catheterization and angiography, septum was hypertrophied to about 5cm and diffuse coronary artery aneurysm was revealed. We found no previous report of coronary artery aneurysm in hypertrophic cardiomyopathy.

MJIRI, Vol. 7, No.2, 141-143, 1993.

Keywords: Hypertrophic cardiomyopathy, catheterization, coronary artery aneurysm.

INTRODUCTION

Coronary artery dilatation may occur due to a variety of conditions. A genetic cause also may be involved, but the genetic predisposition has not yet been proven. Concurrence of this problem with hypertrophic cardiomyopathy is more interesting, the latter having a genetic background, but whether this is an incidental finding or part of a complex genetic problem needs more study.

This rare case presents a patient with hypertrophic cardiomyopathy and diffuse multivessel coronary artery dilatation.

CASE REPORT

A 40 year old male, a known case of hypertrophic cardiomyopathy with a positive family history, referred for further evaluation and cardiac catheterization to our department. He was a known case since nine years ago at which time he developed shortness of breath and atypical chest pain, which was studied carefully and after echocardiography, diagnosis of hypertrophic cardiomyopathy was documented and propranolol was prescribed.

On admission physical exam revealed a well-developed, well-nourished male in no acute distress. Blood pressure was 140/85mmHg, pulse rate 75/min with irregular pattern, and respiratory rate 13/min. Lungs were clear. A double apical beat was palpable at sixth intercostal space in anterior axillary line. Grade II/VI ejection murmur was heard at left sternal border. Liver was palpable 2cm below right costal margin. Electrocardiography showed atrial fibrillation with narrow QRS complexes, left ventricular hypertrophy and secondary T wave changes extending from V4 through V6. On chest x-ray, cardiothoracic ratio appeared moderately enlarged with prominence of left ventricle.

Echocardiography revealed EDD=3.8cm, ESD=2.5cm, LA= 3.0cm, IVS= 4.85cm and posterior wall= 1.0cm. Systolic anterior motion of mitral valve was detected. Cardiac catheterization was performed. Left ventricular injection showed small left ventricular cavity in both systolic and end-diastolic periods with simultaneous injection at left and right ventricles. Hypertrophied septum about 5.8cm thickness was detected at end-diastole and end-systole. Coronary artery angiography showed fusiform aneurysmal dilatation of left anterior descending artery extending 40mm in length (Fig. 2).

Right coronary artery injection also showed fusiform aneurysmal dilatation continuing to 4.5cm through distal end of coronary artery (Fig. 3).

Operation was suggested and was performed three days later, after which the cardiac surgeon reported that the septum was thick and coronary arteries were ectatic and

Correspondence, Ali Andon Petrossians, P.O.Box 15745-153, Tehran
Fax: 292023

*Assistant Professor, Cardiovascular Research Center, Shahid Rajaii Hospital, Tehran.

**Fellowship of Cardiology, Cardiovascular Research Center, Tehran.

Coronary Artery Ectasia with Cardiomyopathy




Fig. 1. Septal hypertrophy shown during simultaneous biventricular injection, showing hypertrophied septum measuring 5.8cm.

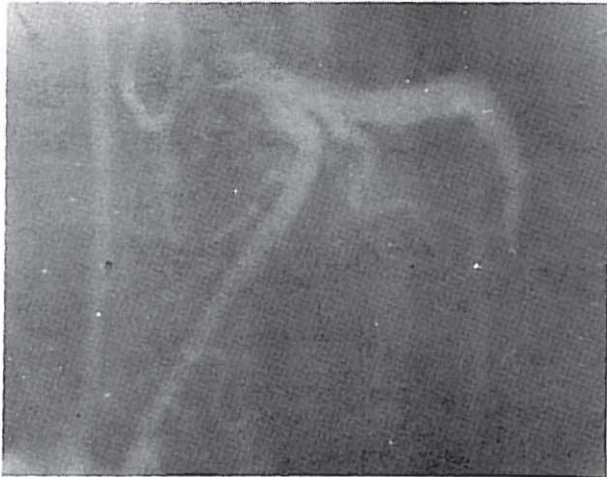


Fig. 2. Diffuse ectasia in left coronary artery.

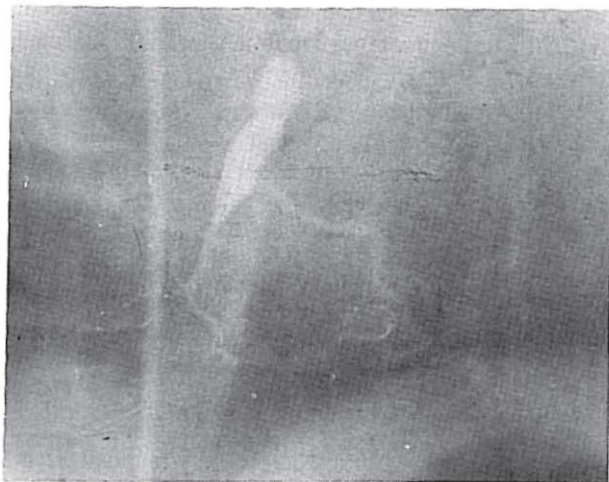


Fig. 3. Diffuse ectasia in right coronary artery.

dilated all through their length, Septal myotomy myomectomy and CABG was performed successfully. Postoperation the patient had no complaint of chest pain or dyspnea.

DISCUSSION

Coronary artery aneurysm is seen in 15% of patients in coronary angiography¹ and generalized coronary aneurysm is called coronary artery ectasia. This process is usually secondary and mainly due to an atherosclerotic process involving coronary arteries, but congenital form of coronary artery aneurysm is also reported.² Kawasaki's disease is another cause of aneurysmal dilatation with many reports having been published.³ Other inflammatory processes may also induce aneurysmal dilatation of coronary arteries and these are vasculitides, syphilis⁴ and mycotic aneurysms. Periarteritis nodosa is another example of a vasculitis producing dilated coronary arteries. Involvement may be at different sites but usually the proximal segment of one or more vessels are involved and the form of involvement may be fusiform or saccular.⁶ The clinical manifestation has a wide variety, from typical chest pain which is due to decreased blood supply or thrombus formation in coronary arteries to angina-equivalent symptoms. In this rare case our patient presented with septal hypertrophy and diffuse multivessel coronary artery dilatation. Here we were not able precisely to determine whether the patient's chest pain was due to coronary ectasia or due to septal hypertrophy, which caused compression of septal perforators. In this particular patient coronary artery bypass graft and myomectomy was suggested and the patient was successfully operated. During postoperative period and in OPD followup (16 months) he had no more problems.

The indications for operation in patients with hypertrophic cardiomyopathy are symptoms unrelieved by intensive medical treatment, in a patient with ventricular outflow gradient of at least 50mmHg at rest or with provocation, a very thick ventricular septum, and high left ventricular end diastolic pressure.

Surgical correction of septal hypertrophy as in our case relieves symptoms but there is no evidence that it prolongs life. The operative mortality and late postoperative mortality rates each approximate 8 percent. Of course with CABG mortality increases but there is no report for this special operation's outcome.

REFERENCES

1. Pyaritz RE, McKusick VA: The Marfan syndrome: Diagnosis and management. *N Eng J Med* 300:772-7, 1979.

M.J. Hashemi, and A.A. Petrossians

2. Erdheim J: Medionecrosis aortae idiopathica cystica. *Virchows Arch* [8] 276: 187-229, 1930.
3. McKusick VA: The cardiovascular aspects of Marfan's syndrome: A heritable disorder of connective tissue. *Circulation* 11: 321-42, 1955.
4. Wagenvoort CA, Neufeld HN, Edwards JE: Cardiovascular system in Marfan syndrome and in idiopathic dilatation of the ascending aorta. *Am J Cardiol* 9:496-507, 1962.
5. Marvel RJ, Genovese, P.D: Cardiovascular disease in Marfan syndrome. *Am Heart J* 42: 814-823, 1951.
6. Baer R, Taussig HB, Oppenheimer EH: Congenital aneurysmal dilatation of the aorta associated with arachnodactyly. *Bull John Hopkins Hosp* 72: 309-18, 1942.